



ISSN NO. 2320-5407

Journal Homepage: - www.journalijar.com

INTERNATIONAL JOURNAL OF ADVANCED RESEARCH (IJAR)

Article DOI: 10.21474/IJAR01/8128
DOI URL: <http://dx.doi.org/10.21474/IJAR01/8128>



RESEARCH ARTICLE

CHRONIC PERIODONTITIS ASSOCIATED WITH CINNAMOMUM ZEYLANICUM INDUCED PLASMA CELL GINGIVITIS: A CASE REPORT.

Mohammed Salman¹, Dr Anuroopa P², Savita Sambashivaiah³, Vinaya Kumar. R⁴, and Navnita Singh¹.

1. BDS, (MDS) Post Graduate, Department of Periodontology, Rajarajeswari Dental College & Hospital, Bangalore.
2. MDS Reader, Department of Periodontology, Rajarajeswari Dental College & Hospital, Bangalore.
3. MDS, Professor & Head Of The Department, Department of Periodontology, Rajarajeswari Dental College & Hospital, Bangalore.
4. MDS, Professor, Department of Periodontology, Rajarajeswari Dental College & Hospital, Bangalore.

Manuscript Info

Manuscript History

Received: 01 October 2018

Final Accepted: 03 November 2018

Published: December 2018

Keywords:

Plasma cell gingivitis, PCG, dentifrices, cinnamon, gingival enlargement.

Abstract

Plasma Cell Gingivitis (PCG) is a rare condition of the gingiva which is characterized by massive infiltration of plasma cells into the underlying sub-epithelial connective tissue. Clinically it appears as a diffuse reddening and edematous swelling of the gingiva with clear demarcation from the mucogingival border. Although the etiology is largely unknown; it is considered to be an immunologic reaction to allergens. Here we present a case of plasma cell gingivitis along with chronic generalized periodontitis in a 27 year old male patient brought upon by use of cinnamon containing toothpaste.

Copy Right, IJAR, 2018., All rights reserved.

Introduction:-

Plasma cell gingivitis (PCG) is a rare inflammatory benign condition of gingival tissue characterized by a marked infiltration of plasma cell into sub epithelial connective tissue (1). This lesion may cause severe gingival inflammation, discomfort, and bleeding and may mimic more serious conditions (2). It is one of the few diseases known to involve attached gingiva apart from leukemic enlargement and hereditary idiopathic gingival enlargement (1).

The occurrence of PCG is associated with a number of allergens and hence it is also known by various names such as Allergic gingivostomatitis, Stomatitis venenata, Irritant contact stomatitis, Atypical gingivostomatitis.¹ Exact etiology of PCG is still not known and some believe that it is a hypersensitivity reaction to certain allergens such as mint-candy or herbal ingredients of toothpaste, red pepper, cinnamon, clove, khat leaves and food flavouring agents. This condition has hence been classified into three categories, based on the etiology:

1. PCG due to allergens.
2. PCG due to neoplastic origin.
3. PCG due to unknown cause. (3, 4)

Irrespective of the etiology, this lesion clinically appears as a diffuse reddening and edematous swelling of the gingiva with a sharp demarcation along the mucogingival border (5).

Corresponding Author:-Mohammed Salman.

Address:-BDS, (MDS) Post Graduate, Department of Periodontology, Rajarajeswari Dental College & Hospital, Bangalore.

The diagnosis requires hematological screening in addition to clinical and histopathological examinations. Clinically the pathologic changes are similar to those of leukemia, HIV infection, discoid lupus erythematosus, atrophic lichen planus, desquamative gingivitis, or cicatricial pemphigoid which must be differentiated through hematologic and serologic testing (5).

Several new products come out in the market and the patient may be reacting to one or more of these products. For example, cinnamon is not only sold as a spice; it is commonly added to many products including toothpastes. This case report outlines such a case of PCG which is suspected to be brought upon by the use of cinnamon (*Cinnamomun zeylanicum*) containing toothpaste.

Case Report

Clinical Findings:

A 27-year-old male reported to the Department of Periodontology and Implantology, Rajarajeswari Dental College and Hospital (Bangalore) with a chief complaint of red, swollen and bleeding gums while brushing teeth. Patient noticed the swelling and redness 3 months before he reported to us in his upper jaw in maxillary right first, second and third molar teeth region, which slowly increased to the present size. On examination gingiva had a reddish pink erythematous appearance, size was increased i.e. grade III enlargement covering three quarters or more of the dental crown (Bokenkamp *et al.*,1994) (6) ; it was soft and edematous in consistency, contour of the gingiva was accentuated with blunted interdental papilla. There was also absence of stippling in the involved region and bleeding on probing was generalized. Probing depth ranged from 7 mm to 10 mm with an attachment loss of 6-8 mm in the maxillary posterior region (Figure 1). Grade 2 mobility was seen in maxillary right first, second and third molar, maxillary left second molar and mandibular right first molar. Grade 1 mobility was observed in mandibular left first molar and mandibular right second molar. Oral hygiene was poor and history revealed patient had a habit of smoking 1 packet of cigarette per day since 10 years. Patient had visited a local dentist 3 months ago and undergone oral prophylaxis along with antibiotic therapy, but there was no significant improvement in his condition. Patient was systemically healthy and did not report a positive drug history. After taking a detailed history, it was found that the patient changed his toothpaste 1 year ago. Radiographic observation revealed generalized horizontal bone loss of varying amount in the maxillary and mandibular molar region with localized vertical bone loss in mandibular right and left first molar region (Figure 2). A blood sample was obtained in order to rule out leukemia or other blood dyscrasias following which a provisional diagnosis of the chronic periodontitis with localized gingival enlargement was made.

Treatment and follow-up:

Initial periodontal therapy comprising of scaling and root planning were performed and oral hygiene instructions were given. Endodontic treatment was planned for maxillary right first and second molar following which flap surgery would be performed in that region. Patient was also instructed to rinse with 0.2% chlorhexidine mouth rinse twice daily. As the oral condition of the patient failed to show any improvement in the enlarged areas on subsequent recall intervals; a gingival tissue sample was procured from maxillary right second molar region and sent for biopsy (Figure 3). An inference of Plasma Cell Gingivitis was made following biopsy. The patient was advised to discontinue the use of that particular tooth paste and an alternate tooth paste was prescribed after which there was reduction in enlargement to Grade 1 following which flap surgery was performed wherever necessary. The areas showing vertical bone loss were treated with alloplastic bone graft material (PerioGlass™) for regeneration. As the patient did not comply for the root canal treatment due to financial problem, root canal therapy and flap surgery could not be performed in PCG involved region. Further recall visits revealed healthy gingiva with well-defined margins throughout (Figure 4).

Histological Findings:

Microscopic examination (4x & 10x) revealed tissue lined by stratified squamous epithelium with mild hyperplasia. Underlying sub epithelial connective tissue showed dense collagenous stroma with collection of inflammatory cells i.e. plasma cells all of which is suggestive of plasma cell gingivitis (Figure 5). Tissue section showed negative result for granuloma and malignancy.

Discussion:-

The present case report is of a rare disorder of gingival origin associated with chronic periodontitis. This case fulfills the criteria of a diagnosis of chronic periodontitis both clinically radiographically associated with abundant plaque and calculus superimposed with generalized gingival enlargement. The enlargement observed was not clinically

consistent with the features of chronic periodontitis and the failure to respond to conventional therapy compelled us into taking a biopsy of the gingival tissue which further revealed the lesion to be Plasma cell gingivitis associated with chronic periodontitis.

Plasma cell gingivitis is a rare condition, characterized by diffuse and massive infiltration of the plasma cells into the connective tissue (7). It is an uncommon condition characterized by a sharply demarcated, erythematous and edematous gingiva often extending up to the mucogingival junction (5). Though the etiology is not clear, the obvious infiltration of plasma cells suggests that the condition is an immunologic reaction to allergens such as various flavoring agents used in chewing gums and dentifrices.

Several cases have been reported showing plasma cell gingivitis alone or in association with inflammatory cheilitis (1), periodontitis (2), gingivostomatitis (8, 9). Serio FG *et al.* (2) reported a similar case where in chronic periodontitis was associated with plasma cell gingivitis and the clinical and histologic findings reported were very similar to our case.

Usually the patient presents with edematous and inflamed gingiva on the labial aspect of the anterior regions of the maxillary gingiva. A tendency for gingival bleeding upon tissue manipulation is invariably present in all cases (10,11). In the present case also, edematous and inflamed gingiva was seen clinically but it was generalized mainly involving the maxillary posteriors.

The local etiological factors for severe gingival manifestations has remained elusive as non-surgical periodontal therapy and mouth rinses have shown to be less effective. Vickers *et al.* (8) suggested *Candida albicans* as an etiological factor, but treating it with antifungal agents proved unsuccessful and in some of the reported cases there was a lack of a positive fungal culture (9). Similarly in this case the etiological factor was not known and the conventional treatment failed to show any sign of clinical improvement in the condition. This case illustrates the need to explore and identify a patient's individual background and habits when several etiological factors are eliminated and desired clinical result is not obtained even after conventional therapy.

When it comes to the etiology of plasma cell gingivitis; Strong spices and some herbs such as chilli, pepper, and cardamom may also be considered important factors in the etiology of PCG (5). Cinnamonaldehyde, which is usually added to dentifrices to mask the unpleasant taste of pyrophosphate, has been associated with the development of PCG (12). Macleod and Ellis (13) reported a case related to the use of herbal toothpaste. Cinnamon, when used as a flavoring agent in toothpaste, was found to be an etiological factor in cheilitis. Kerr *et al.* (10) reported a case of PCG in 1971 where he found that it was due to an allergic reaction to the cinnamon content in chewing gums. In our case it was found that the toothpaste which the patient was using had cinnamon content in it which might have triggered the immunologic reaction causing plasma cell gingivitis. The condition regressed by discontinuing the use of that particular tooth paste containing cinnamonaldehyde.

Differential diagnosis holds a very important place as it shows similarity with many other conditions. Any cutaneous disorder was eliminated due to lack of skin lesions and a negative Nikolsky sign. However as the patient did not respond to the initial periodontal therapy a biopsy was taken from the involved gingival tissue. The histopathological picture revealed high infiltration of plasma cells into the underlying connective tissue thus indicating the diagnosis.

As the diagnosis of plasma cell gingivitis was made along with detailed history pointing towards recent change in dentifrice to a cinnamon containing tooth paste; change in the toothpaste was advised following which at further 1 month recall the lesion showed clinical signs of regression. Following this the patient was subjected to scaling and root planing along with administration of systemic antibiotic and local drug delivery to further treat the condition along with treatment of chronic periodontitis. On further recall visits the sites with persisting probing depth were subjected to surgical intervention with regenerative procedure where ever necessary. At further 6 month recall the enlargement showed reduction from grade 3 to grade 1. Supportive periodontal therapy was carried out wherein the patient eventually showed remission of the condition.

There have been very less reported cases on recurrence of Plasma Cell Gingivitis. Fogarty *et al.* (13) reported on a case of gingival plasmacytosis that had progressed to involve the larynx and was treated with systemic chemotherapy (cyclophosphamide, vincristine, and prednisolone) with temporary improvement, but symptoms progressed after therapy was discontinued. Eventually, the patient was treated with low-dose radiation therapy,

which subsequently caused symptomatic improvement, which was maintained at 12 month follow up. In our case the patient showed no sign of recurrence following the removal of the etiologic agent that is cinnamon containing tooth paste. Also responded well to further periodontal treatment with considerable improvement in the gingival condition.

Conclusion:-

As PCG mimics various lesions associated with other serious conditions such as leukemia and myeloma, an early diagnosis is of prime importance. The present case shows the adverse effect and immunologic reaction to cinnamon containing toothpaste. Taking a detailed history, conducting appropriate examinations and diagnostic tests are important to arrive at an early diagnosis. Accurate diagnosis can in turn direct the clinician towards an appropriate treatment plan for conditions which would otherwise be refractory to conventional periodontal therapy.

Source of funding:

None

Conflict of interest:

None

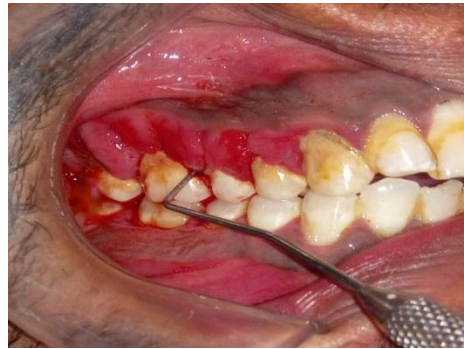

Figure 1:-Grade III Gingival Enlargement & Probing Depth

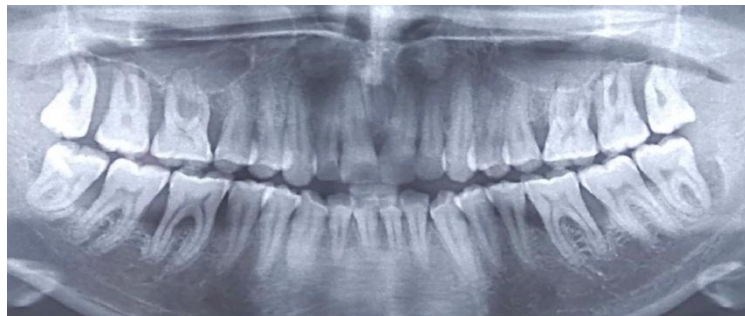

Figure 2:-OPG

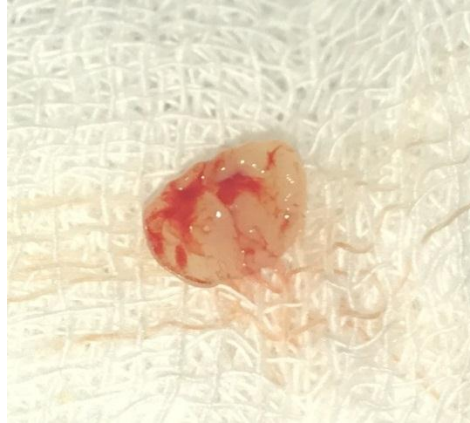

Figure 3:-Biopsy Specimen

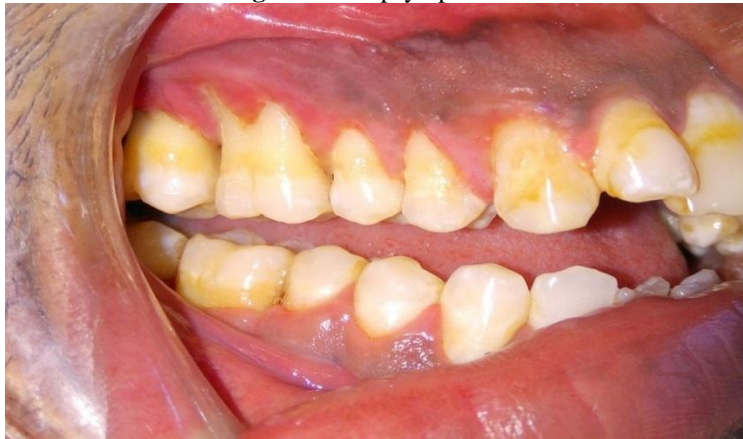

Figure 4:-6 Month postoperative view of PCG involved site

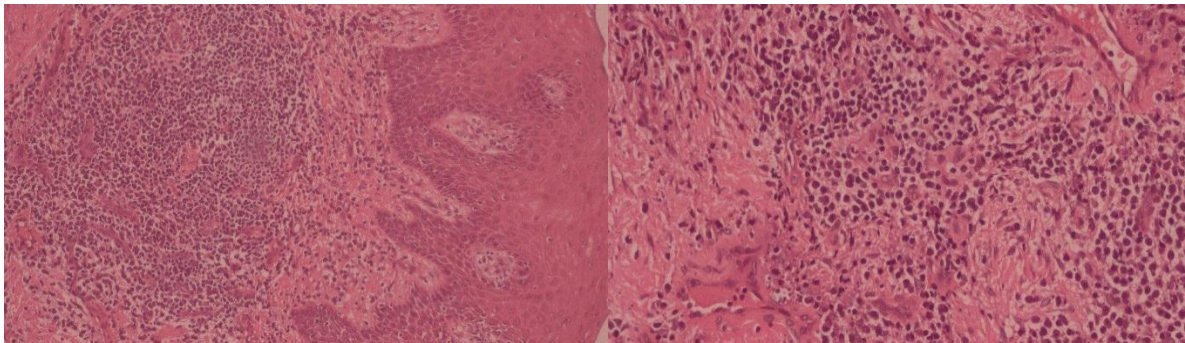


Figure 5:-(a) Microscopic View (4x). (b) Magnified Microscopic View (10x)

References:-

1. Abhishek K, Rashmi J. Plasma cell gingivitis associated with inflammatory cheilitis: a report on a rare case. *Ethiop J Health Sci.* 2013 Jul; 23(2): 183–187.
2. Serio, Francis & A. Siegel, Michael & E. Slade, Brenda. (1991). Plasma Cell Gingivitis of Unusual Origin. A Case Report. *Journal of periodontology.* 62. 390-3.
3. Elavarasu S, Thangakumaran S, Karthik SJ, Arthie T. Plasma cell gingivitis of unknown origin. *J Indian Acad Dent Specialists* 2010; 1:34-8.
4. Ref 4 Imran F, Rajan S, Vijay G. A case of plasma cell granuloma of unknown cause. *J Orofac Res* 2012; 2:235-7.
5. Anil S. Plasma Cell Gingivitis Among Herbal Toothpaste Users: A Report of Three Cases. *J Contemp Dent Pract* 2007 May;(8)4:060-066

6. Bökenkamp A, Bohnhorst B, Beier C, et al: Nifedipine aggravates cyclosporine A-induced hyperplasia. *Pediatr Nephrol* 8:181, 1994.
7. Konidena A, Puri G, Jatti D, Singh S. Plasma cell gingivitis: A case report. *J Indian Acad Oral Med Radiol* 2014; 26:219-21.
8. Vickers RA, Hudson CD. A Clinicopathologic investigation of "Plasma cell gingivostomatitis". *IADR Abstracts*, 1971, 755, p.241.
9. Silverman S, Jr., Lozada F. An epilogue to plasma-cell gingivostomatitis (allergic gingivostomatitis). *Oral Surg Oral Med Oral Pathol* 1977; 43(2):211-217.
10. Kerr DA, McClatchey KD, Regezi JA. Allergic gingivostomatitis (due to gum chewing). *J Periodontol.* 1971; 42(11):709–12.
11. Lubow RM, Cooley RL, Hartman KS, McDaniel RK. Plasma-cell gingivitis. Report of a case. *J Periodontol* 1984; 55(4):235-241.
12. Lamey PJ, Lewis MA, Rees TD, Fowler C, Binnie WH, Forsyth A. Sensitivity reaction to the cinnamonaldehyde component of toothpaste. *Br Dent J* 1990; 168:115-8.
13. Miller RL, Gould AR, Bernstein ML. Cinnamon-induced stomatitis venenata, Clinical and characteristic histopathologic features. *Oral Surg Oral Med Oral Pathol* 1992; 73(6):708-716
14. Fogarty G, Turner H, Corry J. plasma-cell infiltration of the upper aerodigestive tract treated with radiation therapy. *J Laryngol Otol* 2001; 115: 928-930.