

ONYCHOPHAGIA - A CASE REPORT

Salman Salaria¹, Smit Shah², Pooja Shah³, Osman Salaria⁴

¹Resident Physician, Delaware Psychiatric Center, Delaware & Johns Hopkins University Bloomberg School of Public Health, Baltimore, MD, US. ²MS-3, Rutgers Robert Wood Johnson Medical School, New Jersey. ³Resident Physician, Delaware Psychiatric Center, Delaware. ⁴Resident Physician Mount Sinai Medical Center of Florida, Florida.

Abstract

Body focused repetitive behaviors are frequently seen in individuals with obsessive compulsive disorders. These behaviors range from repetitive hand washing to more severe forms such as onychophagia. We report a case of severe onychophagia wherein the patient despite receiving pharmacological treatment for obsessive compulsive disorder was unable to control her impulse to compulsively bite her nails. Repetitive nail biting led to the patient being treated for bacterial infections, debridement and subsequent digital amputations. Cases of severe onychophagia are seldom seen in clinical practice therefore an awareness regarding early identification of the signs and symptoms and up to date management are crucial for practicing clinicians. As illustrated in this case report, pharmacotherapy as well as intense psychotherapy is essential for the long-term effective management of this chronic ailment that can gravely affect the quality of an individual's life .

Keywords: Onychophagia, nail biting, obsessive compulsive disorder, Onychitillomania.

Introduction

Onychophagia is part of the spectrum of obsessive-compulsive disorder, which is characterized by chronic nail biting. Nail biting is commonly seen in adolescents during periods of heightened anxiety. Pacan and colleagues' study estimated that 28-33% of children bite their nails and close to 50% of teenagers remain engaged in this activity. As these individuals reach adulthood nail biting tends to decrease with a frequency ranging between 5 to 10% in adults who remain as active nail biters [1]. In some individual's this behavior can persist in the form of severe compulsions tagged with obsessions. Nail biting can lead to damage to an individual's nails and cuticles and result in secondary bacterial infections due to exposure of the broken skin to the external environment and inculcation of bacteria [2].

Obsessive thoughts with regards to bodily appearance or stereotyped behaviors such as tics, hair pulling or nail biting are integral to obsessive compulsive spectrum disorders. Onychophagia, Onychitillomania, Trichotillomania have been termed body focused repetitive behaviors [1]. Researchers have concluded that low self-esteem and high anxiety correlates with nail biting. Individuals diagnosed with onychophagia have been shown to have high scores on obsessive compulsive rating scales [2].

Ghanzidaehs' study regarding the etiology of nail biting, its consequences and management, revealed that there are very few studies that have analyzed the co morbidity of nail biting with other psychiatric disorders [3]. The study revealed that the most common psychiatric disorders in children with nail biting are attention deficit disorder, oppositional defiant disorder, tic disorder, obsessive compulsive disorder and major depressive disorder [3].

Pacan and colleagues study on the onychophagia disclosed certain factors and comorbidities associated with this behavior. With the help of a structured questionnaire the researchers interviewed participants of which roughly 68 were active nail biters and 102 were past nail biters [1]. The results of the study revealed that nail biting among these individuals was considered an involuntary behavior with close to 70% reporting tension before the behavior and 40% reporting a feeling of temporary pleasure after the nail had been bitten [1].

Case report

A 56-year-old Caucasian female with a history of anxiety, alcohol abuse, hypertension, depression, obsessive compulsive disorder, chronic neuropathy, and multiple partial amputations of bilateral upper limbs due to nail biting, presented to the emergency department on 08/01/2016 with swelling and pain of her left upper limb and left middle finger. Patient claimed that she cut her left middle finger with a steak knife 3 days ago and since then her pain and swelling had gotten worse. Patient described her pain as a burning and throbbing which was 10/10 in intensity, aggravated by touch and



eISSN: 2522-7165
pISSN: 2520-7342

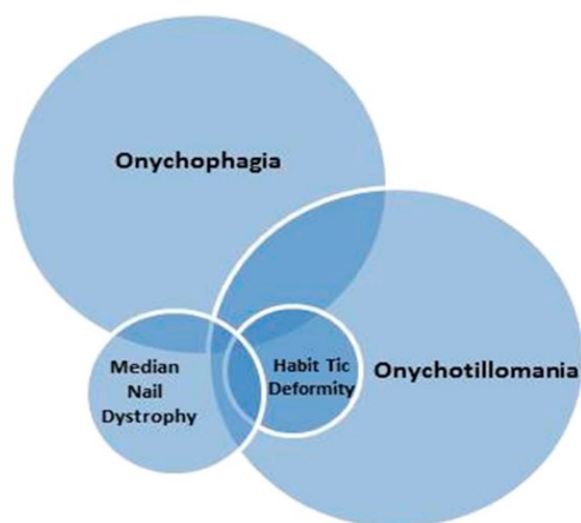
Correspondence: Smit Shah, 112 Montgomery Street, Highland Park, NJ 08904, USA.

Email: spsah1991@gmail.com.

movement of the hand, localized to her left arm and hand, and went down to a 7/10 after administration of IV dilaudid. Patient reported no other symptoms besides having problems with sleep for a couple of weeks.

Patient has had a history of multiple admissions of severe nail biting and “self-reported” accidental injuries to her upper limb, digits which have resulted in partial amputations, debridement and administration of IV antibiotics. Patient’s home medications were clonazepam 0.5 mg 1 tab BID, metoprolol 50 mg PO 1 tab daily, bupropion 150 mg 1 tab daily, risperidone 0.5 mg 2 tabs PO BID, gabapentin 200 mg PO BID and sertraline 250 mg PO daily. Patient was started on disulfiram in the past but was not compliant and started drinking alcohol again.

Patient was treated with IV daptomycin, ceftriaxone, vancomycin and debridement was done by hand surgery. Patient’s last psychiatry consult was on 02/02/2016 when she presented to the emergency department with an ulcer on her right heel. During the interview patients stated that she engages in obsessive compulsive like behaviors which result in her biting her nails to the point of amputation. During psychiatry consult patient denied any picking or biting behavior or any other psychotic symptoms. Inpatient hospitalization was not recommended however patient was advised to start an intensive outpatient program along with increasing her Zoloft. Psychiatry was consulted again during this admission and patient was discharged on home



medications and was told to follow up with outpatient psychiatry and to start intensive psychotherapy for her mental illness.

Figure 1. Venn diagram of similar clinical nail disorders that can present in different body focused repetitive behaviors [4]

Discussion

There are few case reports that describe the severity and chronicity of onychophagia. As seen in this case in the absence of a proper treatment protocol, patients will be frequently hospitalized due to recurrent bacterial infec-

tions. Severe onychophagia requires pharmacotherapy in conjugation with intensive psychotherapy. Many studies have researched potential interventions. Moritz and colleagues’ randomized control trial on nail biting focused on the use of decoupling with the use of motor sequencing that focus on reorganizing behavioral elements involved in nail biting [5]. The researchers compared this technique to progressive muscle relaxation and found that after four weeks, individuals in the decoupling group showed a significant decline in the urge to bite one’s nails [5].

Morand-Beaulieu study on body focused repetitive behaviors revealed that cognitive behavioral therapy which is specifically focused on controlling the unnecessary number of sensorimotor stimuli and muscular tension, has been shown to be effective in treating these behaviors. The researchers designed their own cognitive-psychophysiological model, which focused on motor execution and inhibition [6]. The researchers found improvement in symptoms in both tic disorders and in patients with body focused repetitive behaviors. Another study analyzing an alarm armband versus imipramine in 157 individuals revealed that by attaching an alarm armband to an individual’s arm can effectively reduce nail biting. The researchers found that individuals using the alarm armband reported a decrease in symptoms and less frequency in nail biting compared to the individuals treated with imipramine [7, 8].

With regards to pharmacotherapy, many medications such as selective serotonin reuptake inhibitors have been recommended for the treatment of onychophagia. Sharma and colleagues review on the pharmacotherapy of onychophagia highlights the use of clomipramine and others drugs of its class however, the authors also stress analyzing the nature of the comorbid psychiatric disorder accompanying onychophagia. For example, lithium, has been effective in resolving nail biting in individuals with a history of bipolar disorder [9]. Fluoxetine has been used to treat patients diagnosed with onychophagia. Ghanizadeh concluded in his study on nail biting, that since this is an impulse behavior, some selective serotonin reuptake inhibitors might aggravate the impulse to bite. This is based on the idea that impulses are aggravated in some individuals once being started on these classes of medications [3].

In conclusion, nail biting, which is commonly seen in adolescents, can progress towards onychophagia in adults with conditions such as obsessive compulsive disorder and other mental health illnesses which involve body focused repetitive behaviors. Health care professionals should be vigilant of signs and symptoms of onychophagia which if untreated can lead to severe bacterial infections resulting in multiple amputations as demonstrated. A multi-disciplinary team which involves a group of physicians, which include psychiatrists, internists and dermatologists should be included in the overall treatment protocol for these patients [10]. As mentioned in the above research studies, a combination of pharmacotherapy and behavioral therapy focused on repetitive behaviors is crucial in attaining a path towards

recovery in individuals that struggle from constantly biting their nails only to receive temporary gratification.

Conflicts of Interest: We have no conflicts of interest.

Funding sources: None

References

1. Pacan P, Grzesiak M, Reich A, Szepietowski JC. Onychophagia as a spectrum of obsessive-compulsive disorder. *Acta Derm Venereol.* 2009;89(3):278-80.
2. Tanaka OM1, Vitral RW, Tanaka GY, Guerrero AP, Camargo ES. Nailbiting, or Onychophagia: A Special Habit. *Am J Orthod Dentofacial Orthop.* 2008;134(2): 305-08.
3. Ghanizadeh A. Nail Biting; Etiology, Consequences and Management. *Iranian J Med Sci.* 2011;36(2):73-9.
4. Rieder EA, Tosti A. Onychotillomania: An under-recognized disorder. *J Am Acad Dermatol.* 2016 Dec;75(6):1245-50.
5. Moritz S, Treszl A, Rufer M. A Randomized Controlled Trial of a Novel Self-Help Technique for Impulse Control Disorders A Study on Nail-Biting. *Behav Modif.* 2011;35(5): 468-85.
6. Morand-Beaulieu S, O'Connor KP, Richard M, Sauvé G, Leclerc JB, Blanchet PJ, Lavoie ME. The Impact of a Cognitive-Behavioral Therapy on Event-Related Potentials in Patients with Tic Disorders or Body-Focused Repetitive Behaviors. *Frontiers in Psychiatry.* 2016; 7:81.
7. Kasaeeayan AA, Nakhjavany NH, Aliramaji. A Comparing the Treatment Effectiveness of Alarm Armlet (a New Invented Method) and Imipramine in the Chronic Nail Biting. *Caspian J Appl Sci Res.* 2005; 4(2):1-5.
8. Houston-Hicks M, Lura DJ, Highsmith MJ. Play Hands Protective Gloves: Technical Note on Design And Concept. *Tech Innov.* 2016;18(2-3):207-210.
9. Sharma V, Sommerdyk C. Lithium Treatment of Chronic Nail Biting. *Prim Care Companion CNS Disord.* 2014;16(3):PCC.13101623.
10. Halteh P, Scher RK, Lipner SR. Lipner. Onychophagia: A Nail-biting Conundrum for Physicians. *J Dermatolog Treat.* 2016: 1-7.