

# ANNALS OF SURGERY

---

VOL. LIV

JULY, 1911

NO. 1

---

## ORIGINAL MEMOIRS.

---

### THE CONTROL OF BLEEDING IN OPERATIONS FOR BRAIN TUMORS.\*

WITH THE DESCRIPTION OF SILVER "CLIPS" FOR THE OCCLUSION OF VESSELS  
INACCESSIBLE TO THE LIGATURE.

BY HARVEY CUSHING, M.D.,

OF BALTIMORE,

Associate Professor of Surgery in The Johns Hopkins University.

ALL surgeons who make for themselves opportunities to observe the manipulative work of their fellows must appreciate the present general tendency toward the abandonment of the applauded methods of comparatively few years ago. The conditions under which Cooper, Pott, and Abernethy worked have long since changed, and though the by-the-clock methods which were essential to operative success in their day are still emulated in some of our present clinics, the stirring, slap-dash, and spectacular is rapidly giving way to the quiet, patient, and undramatic performance.

The elimination of pain has made hurry unnecessary; due respect for the principles which have grown from Listerism has made it inadvisable; the emphasis laid by Halsted on detailed blood-stilling during major operations has proved a further check, and lastly, an expectation of the reactionless healing which occurs only in tissues handled with the greatest delicacy and coapted with scrupulous care is prohibitive of

---

\* Read by title before the American Surgical Association, June, 1911.

haste and the old-time thrills for the bystander which accompanied it.

There are special reasons why the utmost precaution in anæsthetization, the gentlest methods of handling tissues, and the most accurate closure of wounds, accompanied by as painstaking hæmostasis as possible, should be observed during the more difficult intracranial procedures. Neighborhood oozing obscures the clear view essential to the safety of such delicate manipulations as are required for the removal of, let us say, a lateral recess tumor or the trigeminal ganglion; whereas a more general loss of blood with the consequent lowering of arterial tension is a cordial invitation to its near relative shock, favors the onset of respiratory paralysis in cases associated with medullary pressure, makes anæsthesia more dangerous, and lowers resistance to infection through secondary anæmia.

These are premises, I am aware, which are not accepted by all surgeons, for many still feel that high-gearred methods of operating can outdistance these largely imaginary risks, and there is a wide-spread apprehension lest observation of these minutiae engender a reputation of being a slow and fussy surgeon. For, after all, what do these details amount to; with another patient awaiting his turn and an assistant who can close the wound, put on the dressing, and administer stimulants and infusions. But for those who grant the premises and agree that every effort should be made, even at the expense of time, to respect the tissues and to minimize the loss of blood by whatsoever methods one can summon to his aid, there are certain "tricks" which may be found useful, particularly in cerebral surgery.

It is necessary to bear in mind that two fairly distinct vascular systems will be encountered—internal and external. On the arterial or carotid side these systems are quite distinct, but on the venous side the communications between them are so free that, under conditions of intracranial stasis brought about by a growth producing an increase of tension, the venous return from the internal system is in large part shunted into the extracranial field. For this reason—though the

"tricks" to be spoken of apply chiefly to the internal system of vessels with a cerebral and meningeal distribution—it may not be out of place to preface a few remarks concerning ways of combating loss of blood from the external coverings, through which the approach to the more important structures must be made.

Throughout this paper the more critical cases will be considered. If precautions are taken to meet the serious problems of hæmostasis which the critical cases present, the simpler and less complicated ones can be more often carried through to a successful termination at one sitting. Furthermore, the discussion will be largely restricted to the osteoplastic type of operation on the cranial vault; for if its principles are mastered, operations in situations which forbid the use of a tourniquet or those in which a bone flap is prohibited may be conducted with comparative ease.

*The Scalp.*—That a trifling wound in a normally vascularized scalp may bleed abundantly is familiar enough. But when stasis of the extracranial vessels has been produced by a cerebral tumor, the loss of blood incidental to the long incision needed for an osteoplastic resection may be disproportionately excessive, unless precautionary measures are taken. Many devices have been suggested to control bleeding from the scalp, none of them in the long run being as efficient as a properly applied tourniquet. This, in any event, will control the arterial supply to the operative field, and if there is no cyanosis under the anæsthetic and no unusual widening of the emissary venous communications between the internal and external systems, not a single hæmostatic adjunct may be required. When, on the other hand, venous stasis has long existed and wide communications have formed between extra- and intracranial veins, the scalp will fill with blood and require the placement of clamps, no matter what device be employed. But even under these circumstances, the convex side of the incision towards the flap remains dry—a desirable result, as it avoids the risk of stripping scalp from bone through the weight of pendent instruments. When it is necessary to place

clamps on the concave edge, even though the bleeding points may lie in the tough scalp proper, it is best to catch the galea and allow the mere weight of the clamps to close the bleeding points. This precaution will avoid superficial points of tissue necrosis which militate against the subsequent reactionless healing. The flat T-shaped clamps which have been devised for the scalp are, I think, undesirable, for the reason that they are difficult to place and are likely to damage the tissues.

As many of these more desperate cranial operations must require two or more stages before their end, it is essential that the utmost pains be taken in closing the wound to assure an epithelial approximation which will permit early removal of the external sutures. Needless to say, if there are points of staphylococcal stitch infection, or even granulating edges owing to inaccurate closure, the reopening of the wound after a few days, and possibly the later re-reopening after a subsequent interval, is accompanied by especial risks of infection.

Our local method of closing these wounds is to bring the edges of the galea together by a series of interrupted and buried fine black (iron-dyed) silk sutures. This row of buried sutures oftentimes so closely approximates the overlying tough scalp as to render the placement of cutaneous sutures hardly necessary, were it not for the fact that they are destined to control the arterial bleeding which would otherwise ensue on the final removal of the tourniquet. A satisfactory method of placing these sutures before they are tied, by a row of round, fine intestinal (cambric) needles, has heretofore been described.<sup>1</sup> They should be removed after thirty-six or forty-eight hours; and by the fourth or fifth day the incision is hardly visible, there are no points of reaction due to suture constriction, and epithelium covers the entire field.

The present paper is not an essay on wound closure, though such an essay might well be written, for many, I am aware, regard this step as so unimportant a detail of an operation that its performance is beneath the dignity of the operating

---

<sup>1</sup> Keen's System of Surgery, 1908, vol. iii, Fig. 152, p. 272.

surgeon himself. It is, however, a deserving detail of these measures, not only when a subsequent reopening is premeditated, but for the reason that in the case of a fresh first-stage wound, especially when clamps have been necessitated owing to venous stasis, some further loss of blood will occur during the closure. For it is inadvisable to attempt to ligate the bleeding points in the tough scalp, as the external approximating sutures may be relied upon to effectually control them; and to place and tie these sutures accurately and rapidly requires a full and not a crippled operative team.

Impatience to attain results is characteristic of the species surgeon and often leads to the taking of unjustifiable risks—one of the reasons for the high mortality ascribed to major intracranial procedures, those for tumor in particular. The writer is no exception and constantly finds it necessary to curb himself in the desire to do just a little more. But far more tumor operations have been carried to a successful outcome by the courage to temporarily withdraw after a bad start than by banging at hazards. Annoying though it is, it may improve one's score when in difficulties to play back with the loss of a stroke.

Postponement may thus be justifiable merely in view of a badly taken anæsthetic—and no tumor patient in whom pressure is considerable takes the anæsthetic any too well, even with the most skilful administration. At a subsequent trial circumstances may be more fortunate, or a preliminary dose of scopolamin with morphia or atropin, or a combination of chloroform and ether, may serve to offset the earlier difficulties. For cyanosis increases intracranial pressure by accelerating cerebrospinal fluid secretion,<sup>2</sup> which adds to the venous obstruction and so to the loss of blood—a bad cycle all around.

---

<sup>2</sup> This is particularly true of ether, which, though the safest drug to employ, is unquestionably the most difficult to administer; and needless to say, its use should be in expert hands. There is less bleeding with chloroform, owing to the fact that it lowers arterial tension; but this in a way is comparable in its consequences to an actual loss of blood and so must be regarded as hazardous, as has been emphasized heretofore. And there are other hazards in the use of chloroform which formerly we did

But rare though it may be to have to abandon progress toward the final stage owing merely to a badly taken anæsthetic, postponement is not infrequently advisable because of excessive loss of blood from scalp and bone, and such a postponement would hardly seem an advance at all were it not for the fact that a blunt reopening of the uniting superficial wound after a few days is attended with relatively little bleeding.

*The Skull.*—All grades of vascularity may be encountered, and chief reliance must be placed upon the proper use of proper wax, for the introduction of which Horsley deserves the lasting gratitude of us all. The cases which present the greatest difficulties are those in which a superficial tumor of long standing receives or discharges much of its blood supply through the diploetic spaces of the bone. This is particularly true of the large dural endotheliomata, which are often associated with extreme vascularity of the adjacent skull, even though the immediately overlying bone may be thinned by pressure atrophy. The enlarged diploetic channels, in these cases, sometimes the size of a radial artery, are often traceable on the radiographic plates, which in this way may be useful even though they rarely show actual shadows of the tumor. At times the very surface of the exposed skull may be so roughened and vascular that it must be rubbed with wax to check the extensive oozing from countless points.

But even with the generous use of wax, considerable loss of blood may be unavoidable in the process of outlining the bone flap under these conditions of abnormal vascularity with extreme venous stasis. For though extravasation from the bone edges may be controlled, it is less easy to combat the free bleeding due to the separation of meningeal emissaries, particularly if the incision be carried into an area of new-formed arachnoidal villi with a distribution beyond the usual

---

not recognize, namely, the hepatic necroses which in greater or less degree are a constant feature of chloroform administration and are particularly extensive after a readministration, when, as Dr. George A. Whipple has found, there is an especial tendency even to spontaneous bleeding, owing to the loss or diminution of one of the elements necessary to clot formation.

confines of Pacchionian granulations. In any case it is well to give the longitudinal sinus and its lateral lacunæ a wide berth, and not to outline the mesial edge of the proposed flap nearer than two or three centimetres from the midline. Should an exposure of the foot area be deemed necessary the safest method of approach is to turn down a low flap and subsequently cut out a bay from the upper edge, leaving a permanent defect over this dangerous vascular area.

Whether one prefers to outline the bone flap with electro-motor or hand-driven instruments,—and I regard the latter as much the safer,—bleeding is likely to occur from the lacerated osteodural communications at the upper margin. For this reason it is our custom, after making the primary large trephine opening and the secondary opening with perforator and burr, to immediately pass a dural separator between the two, so as to break up the vascular attachments at this early stage. For when the instrument is withdrawn, the cerebral tension is sufficient to again plaster dura against bone and effectually check the bleeding, so that by the time the lateral margins of the flap have been cut, many of the emissary vessels will have become spontaneously occluded.

Postponement at this stage owing to loss of blood may sometimes be desirable, even before the flap, though thoroughly outlined, has been lifted away from the adherent dura. The advisability of this can often be gauged by the anæsthetist better than by the operator, and by a blood-pressure tracing better than by a finger on the pulse. The procedure up to this point has been a brief one, there will be a quick recovery from the anæsthetic, and a certain amount of pressure relief will be experienced through the slight elevation of the still adherent flap.

It is of course far more often possible to elevate the bone flap; for conditions such as may have rendered postponement advisable at a stage earlier than this are naturally rare. One must realize, however, that it takes nearly as long to get out of as it does to get into the intracranial chamber, and as there is likely to be about as much bleeding during the process of with-

drawal as during entry, such blood as may be lost during further advance must be multiplied by two. And one should not wait for a profound upsetting of the pressor mechanism, for it does not go to pieces gradually, but suddenly. This is well exemplified in transfusions, for a large amount of blood may be given up by the donor with no appreciable change in his condition, until a little pallor, increased respiration, and restlessness indicate the need of uncoupling. Checking the flow at this stage is followed by complete readjustment within a few moments, and one is often thus misled into the thought that more blood might safely have been withdrawn; but this extra straw will often so upset the regulatory mechanism that hours or days are needed for a complete restoration.

*The Dura.*—We have come to a stage of the osteoplastic operation which calls for especial tricks of hæmostasis, and the following adjuncts have been found useful: (1) *Small pledgets or "tips" of gauze* of various sizes secured by a black ligature, so that though blood-stained they can be easily located—minute Mikulicz pads as it were. (2) *Sterile absorbent cotton* to be used *dry* and plastered on an oozing surface, or *wet* in hot saline solution, a bowl of which at a temperature of 100° to 105° F. should be on the instrument tray immediately at hand. This dripping cotton is the best material for washing meningeal surfaces, and, when wrung out into flat pads, is the safest and most effectual substance for sponging or for temporary placement in deep cerebral wounds. (3) *Bits of living tissue*—supplied, for example, from the exposed temporal muscle—which serve admirably as a means of checking venous extravasation from points on the dura, and *fragments of partially organized blood-clots*, obtainable at a second-stage performance, are similarly useful. Finally (4) *silver wire "clips"* for placement on inaccessible vessels, which, though within reach of a clamp, are either too delicate or in a position too awkward for safe ligation.

On first elevating the flap there may be, particularly in cases with stasis, quite an abundant loss of blood from the raw surface of the dura. This bleeding comes from two sources,



arterial and venous; that from the latter being by far the more troublesome; for only in case of a torn meningeal at the lower anterior angle, due to its having deeply channelled the bone where this has been broken in turning back the flap, will arterial bleeding give trouble. When this occurs it is naturally the first thing to need attention, and if there is venous bleeding from the raw dural surface, it can meanwhile be temporarily controlled by promptly covering the whole surface with a large pad of the hot and dripping cotton, which is immediately dried out against the oozing dural surface by pressure with a gauze sponge. The arterial bleeding should then be checked without attempting to catch or ligate the vessel, which may be torn back "hang-nail" fashion. Some of the prepared gauze pledgets of proper size can be tucked under the bone, separating the dura from it until a point is reached where the vessel no longer channels the bone. Then the pressure of the pledgets against the tense dural surface will control the bleeding until later in the operation, when with an open dura the vessel can be caught by a "clip" if it proves to be inaccessible to a ligature.<sup>3</sup>

Permanent control of the venous bleeding is a more difficult matter. The artery, as its branches approach the upper part of the exposed area, is accompanied by many dural veins which have a more or less intimate connection with the bone, and many raw, bleeding points may be left after their separation. These points, especially if associated with Pacchionian granulations, may give a great deal of trouble during the further procedure, and indeed may continue to ooze after replacement of the flap and closure of the wound; and thus in the course

---

<sup>3</sup>Loose gauze pledgets of minute size, possibly a centimetre in circumference, are particularly valuable in ganglion operations. For one of them can be plastered against a bleeding point, say at the foramen ovale, and its anchoring ligature led out of the wound, leaving a sufficient exposure of the remaining field to allow for further progress in separating the dural envelopes. By using the proper tricks to control hemorrhage, in none of our last seventy-five cases has it been necessary to postpone a ganglion operation until a second session, and in none has it been necessary to place a drain.

of a few hours a thick extradural clot may form and give pressure symptoms. In our earlier experiences this was an occasional postoperative complication, and even now the possibility of its occurrence is always considered. The fact that dura and bone have been separated makes the formation of such an extradural clot possible, as the result of slow venous oozing, whereas in the ordinary extradural hemorrhage of traumatic origin, the extravasation comes necessarily from a ruptured artery. In other words, the tension of a purely venous extravasation under the latter circumstances would not suffice to peel the adherent membrane from the bone.

Even when the venous oozing seems at the close of the operation to have been effectually checked, postoperative vomiting or straining may start the bleeding anew by dislodgement of terminal thrombi, and for this reason in all cases in which the performance has been a bloody one the patient should not be lifted from the operating table until he has recovered in large measure from the anæsthetic. The table therefore should be made sufficiently comfortable by having a thick mattress covering, for it may be inadvisable to move the patient for two or three hours, and, indeed, it is not exceptional for critical cases to be kept in the adjoining recovery room over night before they are transferred to the ward. With such precautions, in addition to skilful administration of the anæsthesia, postoperative retching and vomiting are rare.

Oftentimes the gauze "tips" or pledgets of cotton, which, during the progress of the operation, have been used to cover and which have become adherent to bleeding points in the dura, cannot be removed without starting the bleeding afresh, so that one is occasionally tempted to leave the foreign material plastered against the dura in the hope of its becoming safely organized. This, of course, is undesirable (though we have found in animal experimentation that the cotton pledgets as a rule are well cared for) and also unnecessary, for an alternative has been discovered in *bits of living tissue or well-solidified blood-clots*. Small snips of tissue may be cut from an exposed raw surface, such as the temporal muscle—and muscle seems

to be particularly valuable as a hæmostatic—and when held for a moment on the bleeding point by a smooth instrument they will adhere more promptly and check further extravasation far better than gauze or cotton. Since this device for checking bleeding was first hit upon some two years ago, we have made frequent use of it, with most satisfactory results.<sup>4</sup>

It is possible that any living tissue will suffice. In a recent case of extirpation of a cerebellopontine tumor a troublesome point of venous bleeding was left at the side of the pons. It was controlled by a small piece of dura which, as the most available tissue, was cut off and plastered against the side of the brain-stem, adhering and effectually checking the bleeding after a few moments of gentle pressure. Organizing clots may also be utilized. They are particularly available in second-stage procedures; and at present, instead of scraping away the clots from primary trephine openings and discarding them, they are carefully preserved in saline gauze, and sections of them utilized in the same way as the bits of muscle tissue. Doubtless it will be found that tissue fragments can be prepared beforehand and kept sterile for this purpose.<sup>5</sup>

It is at this period—with a reflected bone flap and all bleeding from the dura checked—that postponement is most often advisable, not only on account of the loss of blood up to

---

<sup>4</sup>Since this paper was put together I have learned from Dr. Lund's interesting report of the visit last summer of the Society of Clinical Surgery to Great Britain that Sir Victor Horsley demonstrated "the hæmostatic action of a fragment of muscle" on the exposed brain during the progress of a laboratory experiment. It is not unlikely, therefore, and is indeed probable, that one or all of the "tricks" which I have here set down have been in use by others who have not regarded them of sufficient importance to record.

<sup>5</sup>If Bernheim's conclusions (*Jour. Am. Med. Assoc.*, 1910), that the walls of the blood-vessels possess more active clotting elements than do other tissues, prove to be correct the walls of preserved vessels may be applicable for this purpose; or the fibrin from whipped blood might be so prepared that it could be immediately plastered on bleeding surfaces, just as cotton is now used, and thus obviate the necessity for any subsequent replacement. Or, as Carrel has suggested (*Jour. Exper. Med.*, 1910, xii, 460) for the preservation of blood-vessels, we may be able to preserve tissues *in vitro* for these purposes in a condition of "latent life."

this stage, but more particularly should the membrane be so tense that cerebral protrusion of a dangerous degree is likely to occur through an immediate dural opening. Under these circumstances, even in the bone-flap operation, the principles of decompression come into play; for it cannot be emphasized too strongly that a rapidly forming hernia, comprising functionally important areas of a tense cortex which protrude through an immediately superimposed dural defect, often leaves irrecoverable paralyses. Hence, unless a tumor is obviously subjacent and there is every prospect of its removal at the first sitting, recourse should be had to a temporary palliative measure with a dural defect over a silent and preferably over the subtemporal area.<sup>6</sup>

In the making of a palliative subtemporal defect, whether a primary operation or one to be combined with a temporary osteoplastic resection, it is important that the fibres of the overlying muscle be preserved as intact as possible. This necessitates, particularly in the case of a primary decompression, the careful rongeur away of the thin bone of the temporal region far under the edge of the split muscle, with an exposure of an area of dura carrying the main branches of the middle meningeal artery. Hence, when the dura is incised radially from a primary central opening to the margins of the bone defect, some of these branches, particularly the posterior radicle of the artery, are likely to be divided, and unless precautions are observed, bleeding may be troublesome. If the spoon-shaped spatula<sup>7</sup> is used to hold the tense brain away from the dura while the radial cuts are being made, the arterial branches can usually be seen before they are divided, and a delicate clamp of the Halsted pattern can be applied on each side of the incised membrane even in the deeply overlain parts of the wound inaccessible for ligation. But what to do with these deep bleeding points after they were thus caught often

---

<sup>6</sup>A useful method of combining at this stage a decompression with the exploration has been elsewhere described (*Surg., Gynæc. and Obst.*, vol. iv, 1909, pp. 1-5). It has been put into practice in some thirty or forty cases with uniform satisfaction in the results.

<sup>7</sup>*Surg., Gynæc. and Obst.*, 1909, vol. iv, p. 3, Fig. 2.

gave us great concern in our earlier operations; and on one or two occasions it was necessary to divide the muscle transversely in order to obtain sufficient exposure for ligation. These difficulties have been overcome by means of silver "clips"—a device which possibly deserves the especial description given to it later in this paper.

*The Brain.*—The central nervous system can be seriously damaged in the attempt to employ the usual methods of hæmostasis with gauze, clamp, and ligature commonly used for other tissues. From its first exposure, every effort should be made to avoid any injury to the pia-arachnoid until the actual moment of entry to the subcortex for the purpose of exploration or enucleation of an obvious growth, and such entry and proposed enucleation must be carefully planned out in accordance with the disposition of the cortical vessels. A safe enucleation may be completely frustrated by gauze sponging or otherwise roughly handling a brain under tension, by the protrusion and rupture of the tense cortex through the primary dural opening, by the accidental injury of a cortical vein carelessly wounded during the enlargement of the dural incision. The struggle to control the consequences of these seemingly trifling matters, which leave in the end a large patch of broken and infiltrated cortex through which ligatures have cut and against which gauze sponges have been held, is only too familiar, and operations for tumor are usually terminated by such an occurrence.

Familiarity with the tricks of lessening tension is all-important in the prevention of these accidents, and the different methods of dealing with a "dry" or "wet" brain by primary decompression, by pricking arachnoid spaces, by ventricular or lumbar punctures, by changes of posture and what not, is a subject too large to be dealt with in the present paper, though indirectly bearing a close relation to loss of blood incidental to manipulations of the nervous tissues themselves. The whole matter hinges more on the disturbances of cerebrospinal circulation than upon the size and position of the tumor. For with a smoothly taken anæsthetic there may be little or no

difficulty in manipulating a brain holding the largest of growths, whereas cyanosis with increase of stasis may make the exposure of a brain, under previously normal conditions of tension, hazardous in the extreme. A small growth of the brain stem, on the other hand, may lead to a great stasis of fluid, the embarrassments from which can be promptly set aside by a ventricular puncture. In any event, a satisfactory subdural exploration can only be made after a considerable diminution in tension has been brought about in one way or another.

The question of tension, furthermore, is quite apart from the actual primary vascularity of the growth, for some of the most vascular lesions, which consequently are difficult to handle, fortunately may be uncomplicated by tension, just as tense brains may hold relatively non-vascular growths which are readily enucleable. However this may be, great care should be exercised in attacking a growth when once it has been brought into view and has been given the wide exposure essential to a safe attempt at extirpation.

Notwithstanding the statement of physiologists to the contrary, one rarely if ever sees "shock" in cerebral operations as a thing apart from hemorrhage or injury to some vital centre. This is abundantly supported by certain of our experiences with extensive cerebral manipulations at second-stage operations in unanæsthetized patients. Hence, with careful choice of the stage at which an extirpation may be attempted—meaning largely an unbled subject—an abundance of time and patience should be expended in the careful and slow manipulations necessary for the dislodgement of the tumor. The tearing out of a growth by the insertion of the fingers means a fragmental removal, extravasation and œdema from unnecessary damage, and blind points of hemorrhage most difficult to identify. On the other hand, it is astonishing how dry the subcortex may actually be if care has been taken in respect to the superficial vessels. One can usually find a safe point of entry through the cortex; and much of the remainder of the operation consists in the slow separation of brain from tumor,

working now here, now there, leaving small, flattened pads of hot, wrung-out cotton to control oozing for the time being from a given area, until it can be again attacked. I know of no better training in such procedures than can be gained by the experience of making clean-cut extirpations on the lower animals—let us say of the motor territory of the canine brain.

A few fine silk (bead) ligatures may be passed on delicate curved needles to secure some of the vessels crossing the line of proposed cortical (circumferential) incision if one is necessary, but care should be taken not to include the large *Vena anastomotica* or important branches of the middle cerebral artery, lest outlying areas of softening result and leave unexpected and unexplainable palsies to be answered for. Indeed, it is often surprising how widely one can push aside many of these vessels in the pia-arachnoid which at first would seem unquestionably to need ligation.

The actual tilting out of a tumor is largely a one-man performance, and the operator's left hand is necessarily occupied in holding and guarding the tissue in process of separation. The manipulations meanwhile are carried on by slow, blunt dissection with the right hand, while an assistant keeps the field clean by the careful use of wet cotton pledgets. During the progress of the measure, particularly in the case of a deeply seated tumor, vessels may be encountered passing from brain to tumor and lying in tissues in which it is obviously futile to place an ordinary hæmostatic forceps. Under these circumstances the silver "clips" to be described may be found to be useful, just as they are in the presence of dural bleeding from points awkward of access; for the jaws of the instrument holding the clip will pick up the visible vessel or bleeding point just as would the ordinary clamp, the "clip" being left to take the place of an actual pendent instrument.

Despite the rapidity with which the surrounding brain tends to fill up the gaping hole left by the final dislodgement of the growth, the raw surface of the cavity may continue to ooze. This condition can best be controlled by filling the hole with a wad of dry absorbent cotton which is replaced as it becomes

saturated. Ultimately the contracting cavity will be left sufficiently dry to justify closure without drainage, for a drain leading from the nervous tissues to the external world should never be used if it can possibly be avoided. The cavity, even if large, should be filled with normal salt solution, and the dura closed as accurately as possible over it. Even if it has been necessary to leave a defect in the dura overlying the cavity, the same principles are to be adhered to.

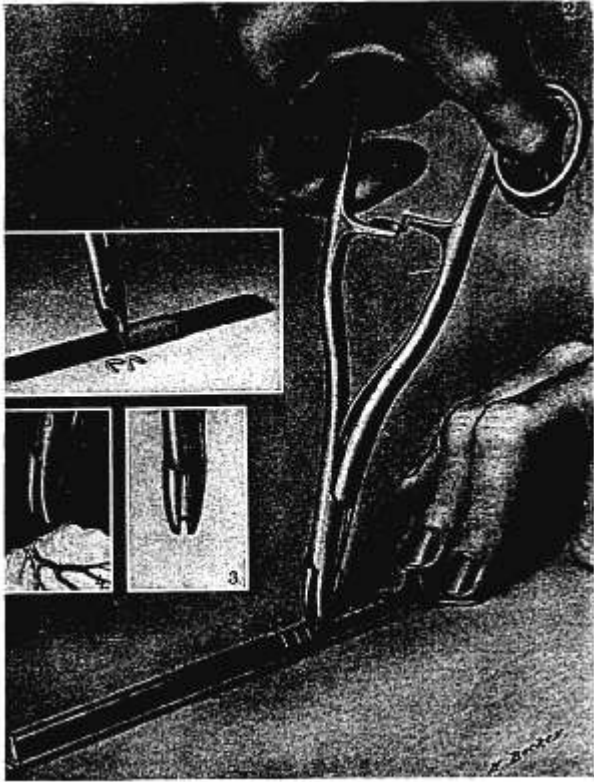
It was formerly our custom, in order to draw off the excess of bloody fluid as the brain tended to swell and fill the cavity, to leave one or two folded protective wicks, which were led from the cranial chamber through the primary trephine opening to a puncture in the scalp, outlying the original line of incision. For in this way an oblique passage is insured, and one which is easily occluded by pressure after the withdrawal of the wicks. But particularly in second-stage performances we have found this to be less and less necessary as we have learned how to leave a dryer wound. In the case, for example, of the tumor pictured in Fig. C., the huge cavity left by the removal of the growth was merely filled with salt solution, the flap replaced, and the wound closed with no drainage whatsoever.

#### SILVER-WIRE CLIPS AS LIGATURES

The thought has doubtless occurred to many that much time and trouble would be saved in major operations could there be devised some form of hæmostatic clamp, the mere placement of which would leave a fine, knotted ligature on the bleeding point so as to obviate the alternatives which we now possess, either of leaving a pendent instrument or taking the time necessary for ligation. Some one will probably have the ingenuity to construct an instrument of this kind, which will be useful not only for such extensive performances as complete breast amputations, where many delicate vessels must be secured along the axillary vein and where the temptation is great to leave dangling a heavy mass of clamps, but also in operations during which vessels are necessarily divided at

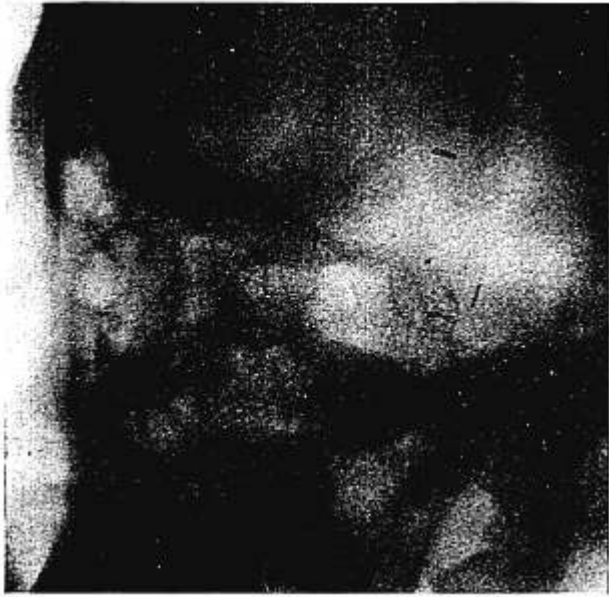

FIG. A.



Drawing to show (1) silver wire loops being cut after wrapping on grooved steel pencil; (2) one of the clips being picked up from the loaded magazine; (3) clip in position in jaws of holder; (4) clip placed on meningeal vessel at the edge of a dural incision, the empty instrument showing the mould for the clip. (Reduced one-third.)

FIG. B.



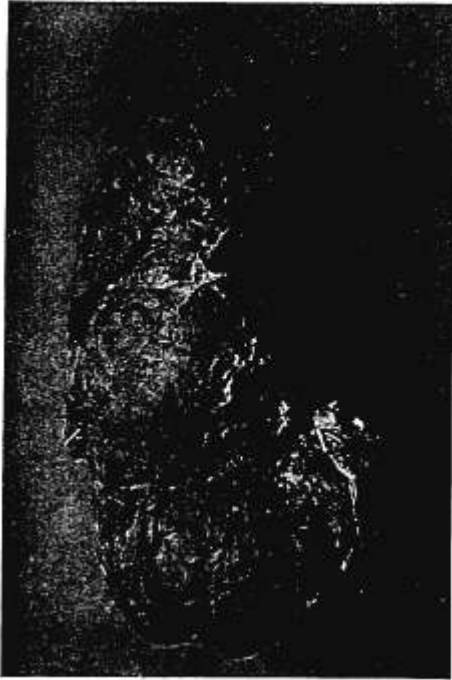X-ray of a patient's head after subtemporal decompression, during which four clips were placed on bleeding points in the dural margin. Showing unobstructed view of normal sella turcica, two of the clips being in line with its posterior border.

FIG. C.



Dural endothelioma (actual size) with adherent clips. Tumor successfully extirpated at second stage, weighing 200 grammes. Bone-flap operation; closure without drainage; uncomplicated recovery.

FIG. D.



Clips adhering to the inferior thyroid stump of an enucleated intrathoracic goitre (slightly reduced).

depths easily reached by a clamp but in positions awkward for ligation. It was doubtless this thought, coupled with a knowledge of the ingenious instrument used by some surgeons for closing skin wounds by the superficial placement of removable, toothed metal bands, that led to the device which we have come to employ.

Some three years ago a small U-shaped bit of wire held in the jaws of an ordinary clamp was first successfully used to check bleeding from a troublesome meningeal vessel divided in a subtemporal operation. As further trials were made on subsequent occasions, the difficulties of holding the small bit of wire in position were overcome by an indentation (Fig. A, 4) in the blades of the clamp in which the wire could securely lie. The wire U's have finally come to be made in large numbers and of equal size by cutting them from a flat metal pencil, around which the wire has been previously wrapped (Fig. A, 1). In order to furnish clips which will not slip easily from the tissues on which they are placed, the metal pencil is longitudinally grooved, so that by lightly tapping the wire, after winding, the inner surface of the loops become transversely ridged. A deep median groove allows the pointed wire-cutters to snip the several loops (Fig. A, 1) of the same size. They are then loaded on a magazine and picked up individually, as needed, by the holder (Fig. A, 2). The first "catch" of the holder locks its sprung handles at a point which closes the jaws sufficiently to enable them to take up the loop from the magazine without deforming the easily compressed wire, and the instrument unlocks itself when the U has been flattened against the bleeding point (Fig. A, 4). These matters are made sufficiently clear by Mr. Becker's excellent drawing without further description.

The instrument in its present form has been put to use at some stage or another in almost all of our operations on the brain for the past year or two. Like any tool, however, a certain amount of experience is necessary before it can be used with facility. In the hands of some ingenious mechanic it would doubtless be capable of much greater perfection; it

would be well to have a self-loading tool if one could be constructed without its being too cumbersome.

The "clips" have been found useful for the occlusion of inaccessible vessels divided in the dural incisions of decompressive operations (Fig. B), for the occlusion of the meningeal at the foramen spinosum if its division is advisable during the operation for trigeminal root avulsion, and, as has been stated, during the enucleation of cerebral tumors for the occlusion of the vessels passing from cortex to tumor—vessels the position and delicacy of which often make ligation well-nigh impossible (Fig. C).

Though from the present character of my operative work I have had little opportunity to test the value of these silver "clips" in operations other than those on the brain, I can recall occasions in intra-abdominal work when the instrument would have been most useful—occasions when a bleeding vessel, such as the artery of the cystic duct, in the depth of the wound could be caught by a clamp but in a position difficult for ligation, particularly if the operator's left hand was occupied in holding the viscera aside to secure the necessary exposure. The "clips," however, have been utilized in a recent enucleation of a large intrathoracic thyroid tumor (*goitre plongeant*) in a case of acromegaly. The tumor, the descent of which had doubtless been encouraged by the skeletal enlargement of the upper thorax, had exerted pressure against the superior vena cava, and venous stasis of the entire upper body was so extreme as to give an appearance of a malignant mediastinal growth. During the process of dislocating and delivering the growth from its subclavicular position, many of the inferior thyroid vessels below the clavicular level were clipped before their division in positions which would have made ligatures very difficult to apply and the placement of a number of clamps out of the question (Fig. D). "Clips" similarly have been successfully used by Emil Goetsch in such delicate procedures as the experimental occlusion of the canine hypophyseal stalk, and by L. J. Crowe for securing the bleeding points after a tonsillectomy. It is not improbable that similar instruments

fashioned to carry loops of stouter wire and of larger calibre might prove useful in occluding vessels larger than those for which we have heretofore used the device.

*Summary.*—One of the chief objects of concern in intracranial surgery should be the avoidance of any unnecessary loss of blood, for at best, in many cases of brain tumor associated with venous stasis, bleeding is likely to be so excessive as to necessitate postponement of the final steps of the procedure until a second or even a third session.

The common methods of blood stilling by sponge, clamp, and ligature are largely inapplicable to intracranial surgery, particularly in the presence of bleeding from the nervous tissues themselves, and any device which serves as an aid to hæmostasis in these difficult operations will bring a larger number of them to a safe termination at a single sitting, with less loss of blood and less damage to the brain itself.

In addition to the more familiar tourniquet for the scalp, and wax for diploetic and emissary bleeding, suggestions are offered as to the use of gauze pledgets, dry sterile cotton, fragments of raw muscle and other tissues, as well as sections of organizing blood-clots for superficial meningeal bleeding, and silver "clips" for inaccessible individual points either in dura or brain.

The successful consummation of any critical operation often depends upon seeming trifles. It is, however, the scrupulous observance of surgical minutiae that makes possible the safe conduct of major intracranial performances—performances which a few years ago were attended in most cases by a veritable dance Macaber.