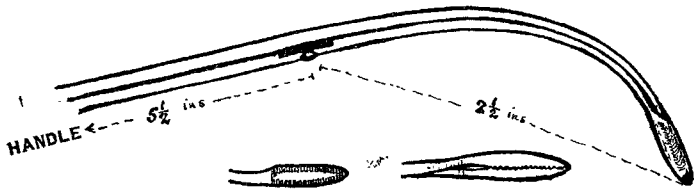


any adhesions separated. The edges of the sac are held apart by Spencer Wells forceps, and the forefinger is passed through the crural canal into the abdominal cavity. If the crural canal is too small to allow the passage of the forefinger then the little finger is used. I have met with cases where before the little finger could be passed I have had to insert the blades of a Spencer Wells forceps and dilate the neck of the sac by gently separating the blades. The finger when passed is flexed forwards so that the tip presses against the conjoined tendon. A pair of closed curved "catch" forceps (see Fig. 2) is passed along the flexor surface of the

FIG. 2.



inserted finger until the tip of the forceps is against the conjoined tendon; the tip of the forceps is pushed through the conjoined tendon, and appears at the upper end of the skin incision. The opposed surfaces of the blades of the forceps are grooved, the better to hold a closed pair of Kocher's hernia forceps, the tips of whose blades are now inserted between the blades of the curved forceps. The latter are withdrawn with the Kocher forceps in their grip, so that the blades of the latter forceps appear at the opening at the apex of the hernial sac. The passage of the finger through the crural canal is important at this stage, as thereby the danger of injuring or nipping intestine or omentum by the blades of the forceps is avoided.

6. The edges of the sac are then caught between the blades of the Kocher forceps and the sac is pulled inside out, appearing through the conjoined tendon. This manœuvre is carried out gently but firmly, and the peritoneal lining of the crural canal is stripped completely away from the canal and invaginated together with the sac of the hernia.

7. The sac is transfixed with a full-curved needle, threaded with catgut, close to the conjoined tendon, ligatured, and then cut away. One end of the catgut is again threaded and the needle passed through the conjoined tendon on one side of the stump, through the stump itself and through the tendon on the other side of the stump, and the two ends tied, the stump thereby being fixed to the conjoined tendon, and retraction being prevented.

8. The slit in the aponeurosis of the external oblique muscle is closed with a continuous catgut suture; the pectineus muscle and fascia are brought into apposition with Poupart's ligament by a stout catgut suture; the skin incision is closed with silkworm gut, and a gauze dressing and firm spica bandage applied.

In practising this operation it is at once obvious that it is necessary to use forceps with curved blades for pushing through the conjoined tendon, since it is difficult, especially in a patient with a fat thigh, to tilt the blades of a straight forceps forward through the tendon. I have not yet encountered a case where I could not perform the manœuvre of invagination with ease. The only obstacle has been in some cases the narrowness of the neck of the sac hindering the passage of the finger. This has been overcome without difficulty, as I have described. The features of the operation are that the crural canal is entirely denuded of

peritoneum, and that there is no pit left at the site of the crural canal which may act as the commencement of another hernial sac. On the contrary, the invagination produces a prominence towards the abdominal cavity. The recurrence of the hernia is further hindered by the fixation of the invaginated sac to the conjoined tendon.

On one occasion recently, when I was operating on a case of double femoral hernia in a female patient, I felt, on passing my finger through the right crural canal into the abdominal cavity, a freely movable body of about the size of a nectarine. On opening the abdomen to remove what proved to be a pedunculated fibroid of the uterus I took the opportunity offered to observe the invagination of the sac from within the abdominal cavity, and the appearance was entirely satisfactory.

A similar method may be used in cases of direct inguinal hernia by invaginating the sac upwards and inwards through the outer border of the rectus abdominis muscle. In one case upon which I operated with excellent result—viz., in a case of right direct inguinal hernia in a man who also had a femoral hernia on the same side—I invaginated the sac of the inguinal hernia through the rectus and the femoral sac through the conjoined tendon. The two sacs thus crossed one another obliquely.

Manchester.

A TREATMENT FOR PROLAPSUS ANI IN YOUNG CHILDREN.

BY WILLIAM GEMMILL, M.A., M.B., CH.B. EDIN.,
F.R.C.S. ENG.,

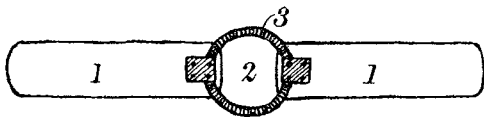
LATE DEMONSTRATOR OF ANATOMY, UNIVERSITY OF EDINBURGH.

It must be clearly understood that the following method deals entirely with the prolapse *per se*, and is not concerned with the exciting causes of that condition, local and general, which must in addition receive their adequate and special treatments. This method of retaining a prolapsus ani in a young child was first tried more than two years ago. It was used without much hope of success in a case of complete prolapse which had resisted all the ordinary methods of retention, including strapping of the buttocks; consequently it was with considerable surprise that I heard the report on the following morning that no prolapse had occurred in the interval. Since this first case the method has been used in several other cases of varying degrees of severity and always with immediate relief of the condition.

The considerations which led me to attempt this treatment were as follows. Normally, when the child defæcates he assumes a position in which the forces accessory to the expulsive contraction of the great bowel (the main factor in defæcation) may act to greatest advantage. The thighs are flexed and pressed on the anterior abdominal wall. The spine is curved with concavity forwards, the pelvis tilting, so that the iliac crests almost reach the costal margins. The position thus assumed of itself decreases the capacity of the abdominal cavity, but it also is a position in which the abdominal muscles, contracting to great advantage and with great force, still further decrease that capacity. Furthermore, when the thighs are flexed on the abdomen two additional results are obtained; firstly, the soft parts of the buttocks and thighs are removed from the region of the anus, thus a great support to the pelvic floor and anal canal is withdrawn, and the anus, instead of being a deeply

embedded hidden orifice, comes to lie on the surface without support; secondly, the skin and subcutaneous tissue round the anal orifice are partly stretched, and the external part of the external sphincter is also stretched and put into a disadvantageous position for contracting efficiently. Hence it is evident that the normal position for defæcation is entirely satisfactory for the exercise of that function, and for the same reasons is favourable to the occurrence of prolapse, decreasing as it does the abdominal capacity, increasing the pressure within, and at the same time weakening the supports of the outlet.

These accessory forces, while of great advantage in defæcation in normal health, are of decided disadvantage in the treatment of prolapse, and especially is this the case when the prolapse is complete, in which type the accessory forces are doubtless the chief expelling factors. The principle then in treatment is to remove these forces as far as possible, and to bring about a condition in which the abdominal capacity responds passively to the decrease in contents brought about by the evacuating contractions of the large bowel, and is not actively decreased by the strength of the accessory forces. This is attained simply by preventing the flexion of the thighs and spine. A straight wooden splint, well padded and covered with mackintosh, is applied to the back of the child of a length to reach from the neck to the heels, and the child is fixed to the splint by two bandages, one round the thorax and the other round the lower limbs. More recently I have been using a similar splint with a hiatus in the region of the anus bridged by a circle of iron, as shown in the diagram. This allows defæcation without soiling of



Sketch of splint for treatment of prolapsus ani. 1. Wooden splinting. 2. Hiatus for evacuation and local treatment. 3. Iron circle screwed to splint.

the splint, and also easy access for such local treatment as cold douching, &c. The result obtained is that the extended position of the child prevents the action of the accessory forces in great part, for the abdominal muscles are placed at a disadvantage for contracting. This position also prevents the decrease in abdominal capacity from flexion, as explained above. Hence evacuation takes place almost entirely from the muscular action of the great bowel. The removal also of the natural support which the soft parts give to the anal canal and sphincters is prevented, and the splint itself gives additional local support by pressing on the soft parts of the buttocks, from which it follows that the hiatus must not be too large, a condition in which this local pressure would be lost.

The relief which this method gives is immediate, the bowel remaining in the abdomen after reduction from the beginning and no prolapse occurring even during defæcation, for which the splint must not be removed. The advantages are efficiency, simplicity, and a minimum amount of trouble in the management of the child, who soon becomes quite comfortable and happy. The splint may be retained as long as is necessary for the child to regain health, for the sphincters to retain tone, and for a normal condition of the parts to return.

The Infirmary, Cleveland-street, W.

A CASE OF DELAYED CHLOROFORM POISONING.

BY H. P. FAIRLIE, M.D. GLASG.,

ANÆSTHETIST TO THE ROYAL AND WESTERN INFIRMARIES, GLASGOW.

THE following case of delayed chloroform poisoning is of interest for two reasons: (1) its late onset and (2) its rapid course.

The patient, a young woman aged 24, spare and rather nervous, was admitted to a nursing home on June 29th, 1914. During the two days which elapsed before operation her temperature was about 99°F. and her pulse about 80 per minute. Her heart and lungs were normal. The urine was acid and clear, had a specific gravity of 1030, and contained neither albumin nor sugar. On July 1st a laparotomy was performed; double tuberculous pyosalpinx was found, along with diffuse tuberculous peritonitis in the pelvis. During manipulation one Fallopian tube ruptured. Both were removed, and the wound was closed with drainage. The administration of the anæsthetic commenced at 3 P.M. and lasted for 38 minutes. Chloroform was administered throughout, during the first nine minutes on a Schimmelbusch mask, and then by the Vernon-Harcourt inhaler. Owing to the patient's nervousness the induction was protracted and three drachms of chloroform were given on the mask. Thereafter the anæsthesia was well maintained by the Vernon-Harcourt inhaler at 2 per cent. until five minutes before the end of the administration, when 1·8 per cent. sufficed; 5½ drachms of chloroform were given by the inhaler. The anæsthesia was satisfactory, with complete relaxation. On return to bed the patient's condition was good, the pulse 100 per minute and of good volume. During the next two days she progressed favourably, and with the exception of pain and attacks of hiccough made no complaint. Thirty-six hours after operation she vomited a small quantity (about an ounce) of brownish fluid. Forty-eight hours after the operation the dressing was stained and the wound dressed. A dose of castor-oil was ordered five hours later, but when an attempt was made to administer it at 8 P.M. on July 3rd—i.e., 53 hours after operation, the patient refused it, clenching her teeth and behaving in a peculiar manner. Although no characteristic symptoms appeared till next morning, when vomiting commenced, this seems to have been the first indication of the presence of acidosis, and during the night of July 3rd she seemed dull and stupid. Sixty-five hours after the operation vomiting of small quantities of brownish, coffee-ground fluid commenced and continued at frequent intervals. The patient was now comatose. Bicarbonate of soda and glucose were ordered in four-hourly doses per rectum, but no improvement resulted. The coma deepened, and along with this the face flushed and the pupils dilated, a decided odour of acetone appeared in the breath, and traces of acetone and albumin were found in the urine. Seventy-two hours after the operation Cheyne-Stokes respiration developed, the patient gradually sank, her temperature rose to 105·8°, and death took place nine hours later, about 24 hours after the onset of acidosis. A post-mortem examination was not obtained.

This case, although presenting many of the