

A Second Case of Abdominal Ovariectomy during Labour, with Remarks.*

By HERBERT R. SPENCER, M.D., B.S., F.R.C.P., *Professor of Obstetric Medicine in University College, London; Obstetric Physician to University College Hospital.*

H. M., a primigravida, aged 24, was admitted to University College Hospital on August 9th, 1905. She stated that the abdomen had been tapped about three weeks previously, at a London lying-in hospital. Afterwards she was told that she had a tumour in addition to pregnancy, and was admitted to the general hospital to which her physician was attached, with a view to having the tumour removed. The patient, however, declined to have the operation done there and left, and, as the abdomen was rapidly increasing in size, she applied for treatment at University College Hospital.

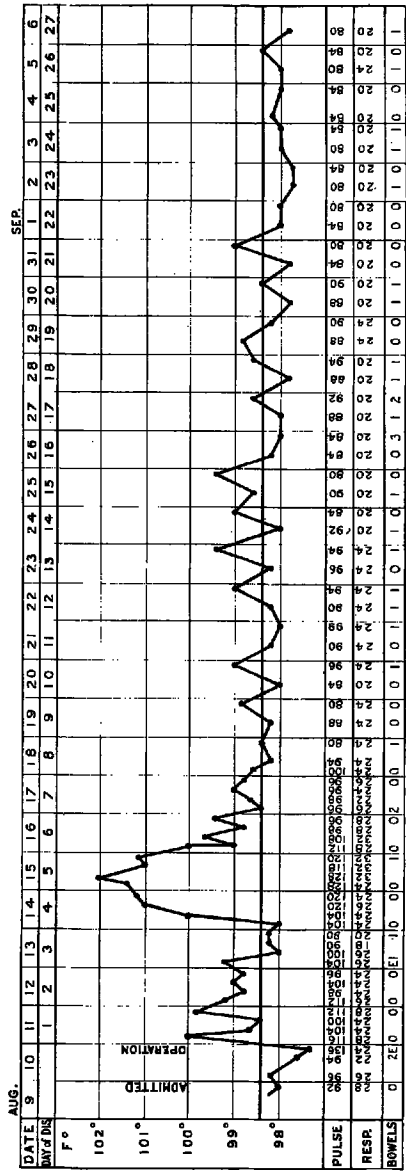
She was a little over eight months pregnant, having ceased to menstruate in the first week of December, 1904. She had always been regular previously. In the last three months the abdomen had swelled very rapidly, and since the tapping she had again increased greatly in size.

She had no pain before the swelling was noticed, but had had increasing pain since. The pain sometimes shot down the outside of the left thigh, which almost always felt numb. She had been losing flesh. There was no history of discharge from the vagina, and no history of tumour or cancer in the family.

I saw the patient on the morning of the 10th of August. She looked bloated in the face. The abdomen was enormously distended, measuring 47 inches in circumference ($23\frac{1}{2}$ inches on each side). From the ensiform cartilage to the umbilicus, the measurement was 13 inches, from the pubes to the umbilicus 12 inches. The surface of the abdomen was mottled, red and white, and there were scratches on the abdominal wall, the result of irritation. Large veins were seen coursing over the upper part of the abdomen.

The greater part of the abdomen was occupied by a thin-walled cyst, dull on percussion, giving distinct evidence of fluctuation, but no ballottement even in the knee-chest position, which was assumed with difficulty.

* Read at a meeting of the Obstetrical Society of London, February 7th, 1906.



Temperature Chart of Case of Ovariectomy during Labour.

The lower part of the abdomen was occupied by a firm tumour, which was felt more on the right side. This was the pregnant uterus, and could be felt to harden while the upper cystic tumour remained flaccid. The outline of the cystic tumour could not be distinctly felt. The flanks were resonant. The os uteri admitted two fingers. The head presented and was low in the pelvis. Contractions could be felt *per vaginam* from time to time. No part of the tumour could be felt in the pelvis.

The case was diagnosed as a large, and probably ruptured, ovarian cyst complicating labour. It was decided to wait for a few hours until the labour was more advanced: this would also permit careful preparation of the abdomen. I operated at 5 o'clock in the afternoon of August 10th, by opening the abdomen in the middle line above the umbilicus. The tumour was found to be extensively adherent to the abdominal wall in the neighbourhood of the puncture. The wall of the tumour was extremely thin and translucent in places, and had ruptured at the lower part, allowing fluid to escape into the peritoneal cavity. The abdominal incision was enlarged upwards and the omentum was found to be extensively adherent to the upper part of the cyst, requiring several ligatures. Fourteen pints of glairy fluid were collected, but a good deal was lost. The cyst was so thin and soft that it tore readily when seized with forceps. The tumour was a multilocular cyst of the left ovary, and contained no solid growth. The pedicle was tied in two and as a whole with floss silk. Afterwards the ovarian vessels were separately under-stitched, and the peritoneum was drawn over the raw surface with fine silk. The abdomen was flushed with saline fluid. The need of taking every precaution against hæmorrhage from the pedicle was seen during the uterine contractions which rendered the parts very tense. Owing to the shortness of the pedicle the stump had to be cut off nearer the tumour than I like. The wound was closed with deep stitches of silkworm gut, with fascial stitches of fine silk and with silkworm gut for the skin. Sterilized gauze dressing was applied. Strong labour pains had set in an hour before operation. A vaginal examination was now made, and the cervix was found to be fully dilated and the head low down in the pelvis. The forceps was applied, and a living and strong female child, weighing 6 lbs. 10 ozs., was delivered. The child was slightly under the influence of the anæsthetic, but soon breathed. The placenta was expressed a few minutes later. There was no postpartum hæmorrhage. The whole operation, including the forceps delivery, lasted 70 minutes; much of the time was occupied in tying off the adherent omentum.

Mother and child recovered well; the mother suckled her infant. The wound healed by first intention. The lochial discharge ceased on August 20th.

The patient left the hospital on September 6th, with her child, both being very well. I saw them both on October 10th, 1905. The mother's uterus was well involuted, movable, and free from tenderness. The abdominal scar was $2\frac{1}{2}$ inches long and quite sound. The child weighed 10 lbs.

Remarks.

The first point which calls for comment in this case is the tapping to which the patient had been subjected before I saw her. Twelve years ago, in a paper read at the Medical Society of London,* I wrote: "The tapping of ovarian cysts, unless they are undoubtedly malignant, or unless the patient is suffering very acutely from some pulmonary affection or grave general disease independent of the tumour, is in my opinion an unjustifiable procedure." Further experience has strengthened this opinion; but it seems desirable that the opinion of other members of this Society should be enunciated, since in the year 1905 such treatment has been adopted in a lying-in hospital of the Metropolis. I do not anticipate that there will be many Fellows of our Society who will advocate tapping an ovarian cyst complicating pregnancy.

The second point of interest is the line of conduct which should be pursued in the case of a patient in labour who has a large ovarian tumour which does not obstruct the pelvis.

The case is one which needs prompt treatment. The danger of rupture of the tumour, when large, is shown by this case (in which, however, it may have been due to the puncture), and by a case published by me in the *Transactions of the Obstetrical Society of London* (Vol. XLIII., p. 224), where a large tumour spontaneously ruptured with fatal result on the third day after labour. Other similar cases are on record, and go to show the danger of postponing operation, in the case of large tumours, for any considerable time after delivery.

We have three alternatives:—

1. To deliver by the natural passage, dilating the canal if necessary, and then to perform ovariectomy.
2. To perform ovariectomy, and leave the delivery to nature.
3. To perform ovariectomy at the end of the first stage of labour and immediately afterwards to deliver by forceps while the patient is under the anæsthetic; as in the case now recorded. In suitable

* "A first series of fifty ovariectomies," *Med. Soc. Trans.*, Vol. XVII., p. 86.

circumstances the two operations might with advantage be performed simultaneously.

Each of these three methods may properly be performed, and possesses special advantages under particular circumstances—the first in avoiding the injurious effects of the anæsthetic on the fœtus, and facilitating the operation of ovariectomy and the ligation of the pedicle; the second in avoiding the maternal and fœtal injuries which are so common with instrumental deliveries; the third, of which the case here recorded is an example, in that the patient is delivered, without pain, of her child and her tumour with only one administration of the anæsthetic. The ovariectomy can usually be performed with more complete asepsis than just after delivery, and the risk of rupture of the large cyst during the expulsive pains is lessened.

My only other case of ovariectomy during labour I have published in *the Transactions of the Obstetrical Society of London* (Vol. XL., p. 14). In that case the operation was undertaken for an incarcerated ovarian dermoid, with success both in the case of the mother and child.