

# Pathomorphological Features of Lungs from Brown Hares Infected with Parasites

Mariana Panayotova-Pencheva, Anetka Trifonova, Vassilena Dakova

**Abstract** 790 lungs from brown hares (*Lepus europeus* L.) from different regions of Bulgaria were investigated during the period 2009-2017. The parasitological status and pathomorphological features in the lungs were recorded. The following parasite species were established: one nematode - *Protostrongylus tauricus* (7.59% prevalence), one tapeworm – larva of *Taenia pisiformis* – *Cysticercus pisiformis* (3.04% prevalence) and one arthropod – larva of *Linguatula serrata* – *Pentastomum dentatum* (0.89% prevalence). Macroscopic lesions in the lungs were different depending on the causative agents. The infections with *C. pisiformis* and *P. dentatum* were attended with small, mainly superficial changes in the lungs. Protostrongylid infections were connected with different in appearance and burden macroscopic changes. In 77.7%, they were nodular, and in the rest of cases, they diffuse. The consistency of the lesions was compact. In most of the cases, alterations were grey in colour, rarely were dark-red or marble-like. In 91.7% of these cases, they were spread on the apical parts of large lung lobes. In 36.7% middle parts of the large lung lobes, and, in 26.7% small lung lobes, were also affected. The small lung lobes were never independently infected.

**Keywords**—*Cysticercus pisiformis*, *Lepus europeus*, lung lesions, *Pentastomum dentatum*, *Protostrongylus tauricus*.

## I. INTRODUCTION

**B**ROWN hare (*Lepus europeus* L.) is one of the basic game species on the European continent. However, reduction in its population in whole Europe is lately observed. According to [1], this is caused by changed living conditions, quantitatively and qualitatively insufficient nutrition, using of herbicides as well as various infectious diseases including parasitoses. Lung parasitoses in hare have been connected with different negatives. Alzaga et al. [2] have established correlation between parasite intensity and escape capacity in Iberian hares. According to [3], parasitic infections of the lungs influence the health and decrease the body weight of hares in Austrian and Czech hunting grounds. Other authors [4] consider that lung parasitoses such as protostrongylidoses

Mariana Panayotova-Pencheva is with the Institute of Experimental Morphology, Pathology and Anthropology with Museum, Bulgarian Academy of Sciences, Sofia-1113, Acad. G. Bonchev St., bl. 25, Bulgaria (corresponding author, e-mail: marianasp@abv.bg).

Anetka Trifonova is with the Southwest State Enterprise, 2700 Blagoevgrad, Zora 18, Bulgaria (e-mail: apth@abv.bg).

Vassilena Dakova is with the Institute of Experimental Morphology, Pathology and Anthropology with Museum, Bulgarian Academy of Sciences, Sofia-1113, Acad. G. Bonchev St., bl. 25, Bulgaria (e-mail: vi\_dakova@abv.bg).

The work was supported by the Operational Programme —Science and Education for Smart Growth|| 2014-2020, co-financed by the European Union through the European Structural and Investment Funds, Grant BG05M2OP001-2.009-0019-C01 from 02.06.2017.

are among the most dangerous diseases in lagomorphs at all and can be reason that influences their numbers in certain conditions. It has been established that infection intensity with one of the lungworm species in hares *Protostrongylus tauricus* can reach to several thousand of specimens in one animal and can cause serious damages of the lungs such as atelectasis, emphysema and necrosis which lead to impaired respiratory function, loss of weight, decrease of mobility and death cases [5]. In connection with the above mentioned, the aim of the present work was set to investigate species composition of the parasites affecting lungs of the brown hare in Bulgaria and correlated pathological changes in the organs.

## II. MATERIALS AND METHODS

During the period 2009-2017, 790 lungs from brown hares from different regions of Bulgaria were investigated. The materials were received mainly from planned hunting (according to the “Law for hunting and game conservation” from 2000) and in a small degree from found dead hares. The lungs were disjoined from the carcasses, deeply frozen and subsequently sent for necropsies in laboratory conditions. If pathomorphological changes on the lungs were present, they were described according to commonly used criteria: localization, consistency, colour, formation of nodules, availability of other lesions, dissemination [6].

The macroscopic lesions were subjectively categorized in four groups depending on their dissemination: light (if small, hardly visible changes were available mostly on the dorsal surfaces of the large lung lobes), mild (affected up to 1/6 of the lungs), heavy (affected from 1/6 to 1/2 of the lungs) and very heavy (affected above 1/2 of the lungs).

After the describing of pathomorphological changes, the lungs were investigated by the method of the full helminthological necropsy. Aiming to find small parasites localized in the terminal lung parts (small bronchi, bronchioles and alveoli), the pieces of changed lung tissue were investigated by their compression after boiling in lactic acid [7]. The species of the established parasites was determined according to their morphometric characteristics.

## III. RESULTS AND DISCUSSION

The following parasite species were established: one nematode - *Protostrongylus tauricus* (7.59% prevalence), one tapeworm – larva of *Taenia pisiformis* – *Cysticercus pisiformis* (3.04% prevalence) and one arthropod – larva of *Linguatula serrata* – *Pentastomum dentatum* (0.89% prevalence).

The macroscopic changes round the *P. dentatum* infection

were weakly marked. They were small, single, compact areas or vesicles, approximately as a lentil of size, localized on the surface and more rarely in the inside of large lung lobes and contented pentastomid larva (Fig. 1 (a)). In one case, a group of several free pentastomid larvae was observed hooked on the mucosa of one of the large bronchi.

Larval forms of *T. pisiformis* were situated under the lung pleura. They were elongated, transparent vesicles with a size about 1 cm, contented one scolex (Fig. 1 (b)). Infection intensity was varying – in some cases cysticerci were single, in other they were multitude, sometimes they were above 50 on the lungs (Figs. 1 (c) and (d)).

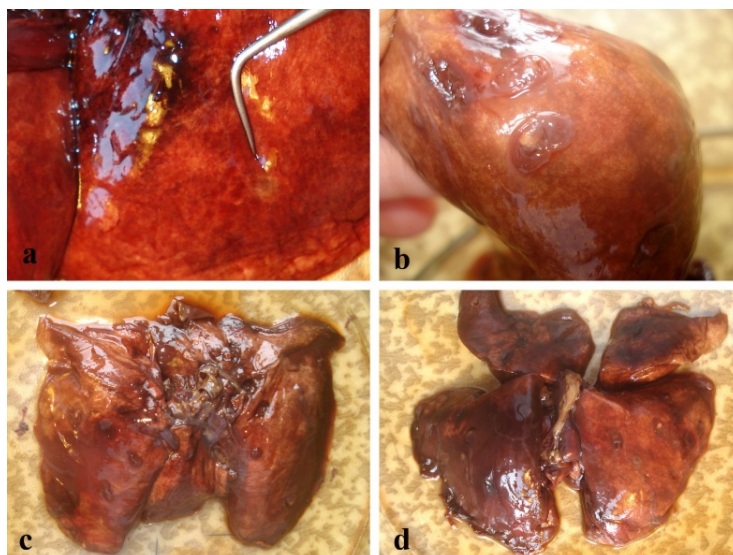


Fig. 1 Macroscopic view of lesions in parasitized lungs from brown hares: (a) Infection with *P. dentatum*; (b), (c), (d) Infections with *C. pisiformis*

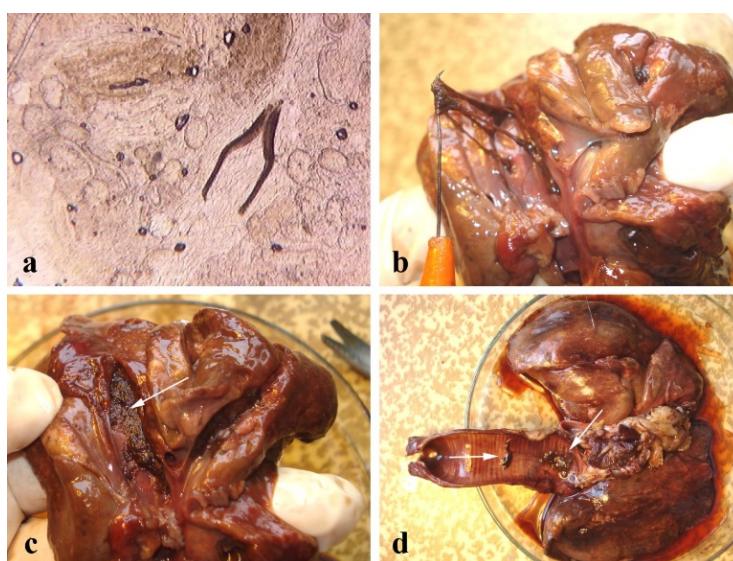


Fig. 2 Lungs from brown hares parasitized with *P. tauricus*: (a) View of spicules, eggs and larvae in changed lung tissue after boiling in lactic acid and compression; (b), (c), (d) Adult worms localized in middle, large bronchi and trachea

The lesions associated with *P. tauricus* were more varied and heavier. In all of the 60 cases of lungs with protostrongylids, parasites were localized in the terminal bronchi, bronchioles and alveoli and they were established only after observing under compression of changed lung tissue boiled in lactic acid (Fig. 2 (a)). In 50% of the cases, besides terminal lung parts, small bronchi were also affected. In 41.7%, lungworms were localized in terminal lung parts, small

and middle bronchi, in 16.7% parasites were also found in large bronchi and in 10% the whole bronchial tree, including trachea, was affected (Figs. 2 (b)-(d)).

The presence of protostrongylid infection in most of the cases was accompanied by pathomorphological lung changes. In 91.7% of the cases, they affected apical parts of the large lung lobes, in 36.7% - middle parts of the large lung lobes and in 26.7% small lung lobes were also affected (Fig. 3).

However, the small lung lobes were never independently infected. Similar alterations have been established by [8] in a mountain hare infected with *Protostrongylus pulmonalis*. Our findings correlate also with those by [9] where the majority and most severe histopathologic changes in mountain and brown hares infected with protostrongylids are located at the distal part of the caudal pulmonary lobes.

associated with previous studies in ruminants when infections with big protostrongylids as *P. rufescens*, *P. hobmaieri* and *P. rupicaprae* were associated with extensive lesions located along the length of the large bronchi [10]. The alterations were coloured most often in different nuances of grey and brown (Fig. 4), more rarely they were dark-red to black or marble-like.

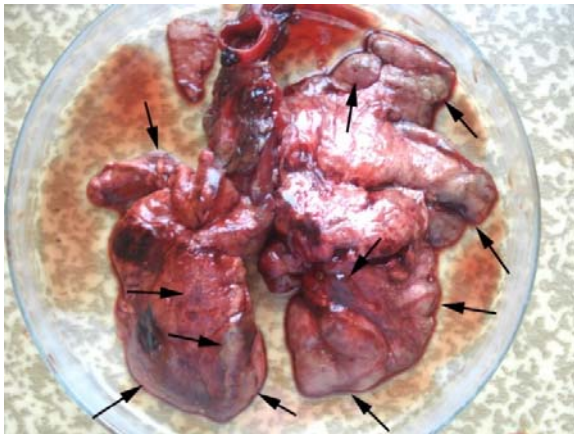


Fig. 3 Areas of pathomorphological changes in lungs from a brown hare infected with *P. tauricus*

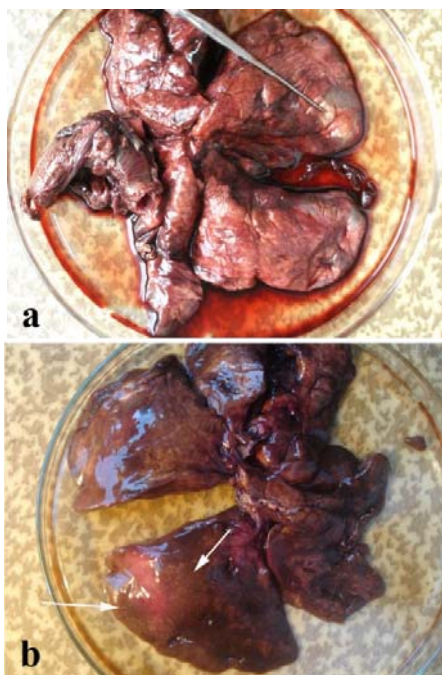


Fig. 4 Pathomorphological changes in lungs from brown hares parasitized with *P. tauricus*: (a) Grey coloured; (b) Brown coloured

In our study, the lesions associated with protostrongylids had compact consistency and varied in size, shape and colour. Most of them were nodular (77.7%) and the size of nodules was between pinhead and large almond. The size of the diffuse lesions was also different and sometimes affected large parts of the lungs. The last ones were observed mainly when the worms were localized in the large bronchi. This fact

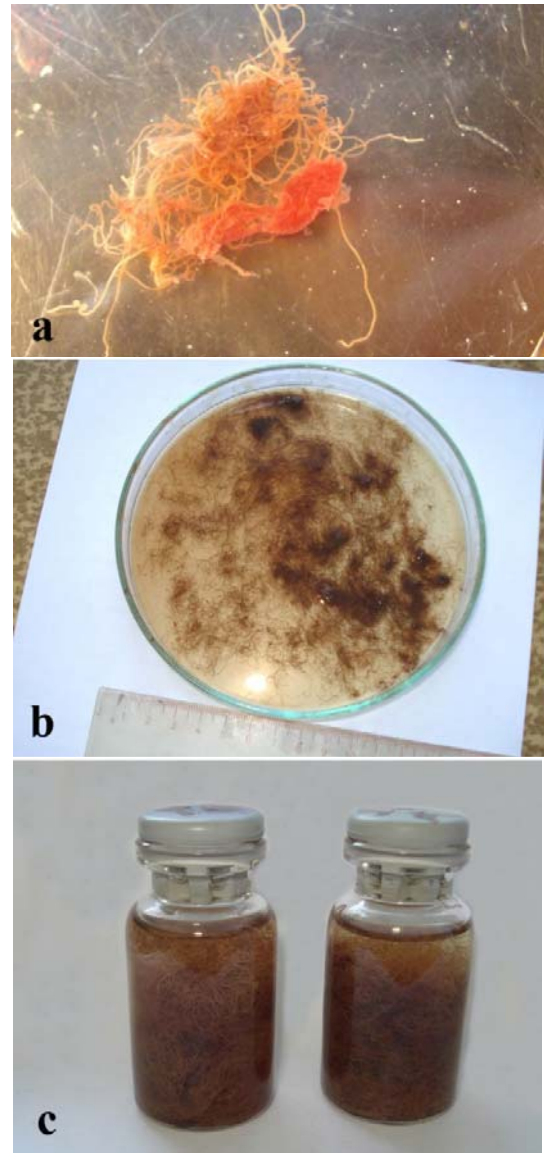


Fig. 5 Adult parasites (*P. tauricus*) from one brown hare: (a) Tangled and gathered as balls; (b), (c) A large quantity of worms found in bronchi and trachea

According to our criteria about subjective heaviness of the lung lesions, it was observed the following: in 71.67% of the cases they were light, in 15% - mild, in 11.67% - heavy and in 1.67% - very heavy. In most of the cases, correlation between the subjective heaviness of the macroscopic changes and infection intensity was observed. Usually, when the alterations were defined as heavy, bronchi were full and obturated by helminths. The parasites were tangled and gathered as balls,

they were hardly torn apart trying to divide and count them (Fig. 5 (a)). Protostrongylids collected from lungs with very heavy alterations of one animal are shown on Figs. 5 (b) and (c). Their quantity demonstrates the correlation between the subjective heaviness of macroscopic changes and infection intensity.

In conclusion, it can be stated that pathomorphological characteristics of the parasitized lungs of brown hares vary according to the species of the parasites which caused them, whereas the infections with *C. pisiformis* and *P. dentatum* lead mainly to superficial small changes in the lungs, protostrongylid infections are connected with different in appearance and burden lesions. The last ones most commonly have nodular character and affect apical parts of the large lung lobes. The study showed correlation between the subjective heaviness of the macroscopic changes in the parasitized lungs of brown hares and infection intensity.

#### REFERENCES

- [1] T. Ilić, T. Petrović, and S. Dimitrijević, "Parasitic infections of wild rabbits and hares," *Vet. glasnik*, vol. 68, no. 3-4, pp. 241-250, 2014.
- [2] V. Alzaga, J. Vicente, D. Villanua, P. Acevedo, F. Casas, and C. Gortazar, "Body condition and parasite intensity correlates with escape capacity in Iberian hares (*Lepus granatensis*)," *Behav. Ecol. Sociobiol.*, vol. 62, pp. 769, 2008.
- [3] K. Chroust, M. Vodnansky, and J. Pikula, "Parasite load of European brown hares in Austria and the Czech Republic," *Vet. Med.*, vol. 57, no. 10, pp. 551-558, 2012.
- [4] C. Lesage, D. Jouet, C. Patrelle, J. Guitton, A. Decors, and H. Ferte, "*Protostrongylus pulmonalis* (Frölich, 1802) and *P. oryctolagi* Baboš, 1955 (Nematoda: Protostrongylidae), parasites of the lungs of European hare (*Lepus europaeus* L.) in France: morphological and molecular approaches," *Parasitol. Res.*, vol. 113, no. 6, pp. 2103-2111, 2014.
- [5] T. Genov, 1970, "A new and dangerous parasite in rabbits of this country," *Priroda, Sofia*, vol. 19, no. 4, pp. 65-68. (in Bulgarian).
- [6] R. G. Thomson, M. D. McGavin, W. Carlton, and J. F. Zachary, *Thomson's Special Veterinary Pathology*, 3rd ed., M. D. McGavin, W. Carlton, and J. F. Zachary, Ed. Mosby, 755 pp., 2001.
- [7] M. Panayotova-Pencheva, "Species composition and morphology of protostrongylids (Nematoda: Protostrongylidae) in ruminants from Bulgaria," *Parasitol. Res.*, vol. 109, no. 4, pp. 1015-1020, 2011.
- [8] A. Battisti, M. Di Paolo, and G. Di Guardo, "Pulmonary protostrongyliasis in a Mountain hare from Italy," *J. Wildl. Dis.*, vol. 36, no. 2, pp. 367-369, 2000.
- [9] J. Laakkonen, T. Nyysönen, M. Hiltunen, K. Kauhala, S. Nikander, and T. Soveri, "Effects of *Protostrongylus* sp. and *Pneumocystis* sp. on the pulmonary tissue and the condition of mountain and brown hares from Finland," *J. Wildl. Dis.*, vol. 42, no. 4, pp. 780-787, 2006.
- [10] M. Panayotova-Pencheva, and M. Alexandrov, "Some pathological features of lungs from domestic and wild ruminants with single and mixed protostrongylid infections," *Vet. Med. Intern.*, vol. 2010, Article ID 741062, 9 pages, 2010.