

STUDY ON INTERNAL PARASITES IN SNAKES GROWN IN DOMESTIC CONDITIONS

Seven Mustafa, Radoslav Rafailov, Kostadin Kanchev, Constantinos Koureas,
Maria-Ioanna Manioti

University of Forestry, Faculty of Veterinary Medicine, Sofia, Bulgaria

E-mail: seven.dentaltech@gmail.com

ABSTRACT

Parasitological study of domestic snakes is a diagnostic approach of great veterinary significance, as many of the internal diseases have similar clinical signs. With modifications of our known diagnostic methods, a number of internal non-infectious diseases can be differentiated from parasitoses or appropriate corrective measures can be identified in breeding conditions.

Domestic snakes have been investigated, with some being found to contain oxirid eggs. A study on this finding was carried out and methods of investigation, parasitosis data and procedure for treatment were presented, with commenting on the importance of oxyuridosis in serpentes

It is necessary to emphasize the importance of a periodic prophylactic control of the parasitological status of domestic snakes as a preventive measure against diseases, which is of great importance for the breeders and the pet shops because there is a gathering of animals and an exchange of inventory.

Key words: snake, internal parasites, nematodes, oxyuriasis, pinworms.

Introduction

Many wild snakes are carriers of endoparasites, but heavy infestations are rarely observed (Wilson et al., 1996). This feature is especially true for helminths with a direct life cycle. Home-grown snakes are subjected to the influence of many different factors (predisposing) - they occupy limited space, poor terrarium conditions, inadequate diet and, in general, stress. Then even with a slight degree of an infestation, there is a high probability of parasites with a direct cycle to accumulate (Russo, 2007; Klingenberg, 2007) and the result in the effects of "reinfestation" and "superinfestation". In the reliable diagnosis of the problem and in taking appropriate hygiene measures, this process can be limited and even eliminated.

Helminths with indirect life cycle do not have much importance in terrarium-grown snakes, so most parasitologists pay attention only to those with a direct development where snakes are the only host for the parasite (Klingenberg, 2007).

Nematodes (roundworms) are the most commonly found parasites of such a cycle, and snakes are no exception as an animal species susceptible to the infestation by them (Mitchell et al., 2009). Infestations have been described in pet snakes, from different parts of the world, with ascarids (*Ophidascaris sp.*), strongylids (*Kalicephalus laticaudae*), strongyloids (*Strongyloides sp.*), as well as pulmonary parasites (*Rhabdias sp.*), but the most common are the infestations with oxyurides also called pinworms (Family *Oxyuridae*) (Jacobson, 2007; Klingenberg, 2007; Wilson et al., 1996).

Trematodes and cestodes in domestic snakes are rarely found, as these parasites require intermediate hosts of different invertebrate species that do not feed these pets in the general practice (Wagner, 2006).

Of the protozoan diseases, amoebiasis is common, caused by *Entamoeba invadens* (Page, 1966) and the coccidiosis (*Isospora sp.*, *Eimeria sp.*). As a particular case, cryptosporidiosis is considered, which in snakes is protozoa caused by *Cryptosporidium serpentis* (Mitchell et al., 2009).

The aim was to study home-grown snakes of different species and to establish whether they are hosts of some of the mentioned endoparasites, then to develop a profile of the parasitoses in Bulgaria in order to elaborate a complex approach in the treatment and prophylaxis.

Materials and methods

The study was conducted on fecal samples of 51 home-grown snakes, of which 12 Boa constrictors (*Boa constrictor*), 35 Corn snakes (*Pantherophis guttatus*), 3 Ball pythons (*Python regius*) and 1 Rainbow boa (*Epicrates cenchria*).

The samples are collected and examined immediately or stored under refrigeration conditions (4 °C).

In addition to direct collection, fecal samples can also be obtained by the so-called "milking" method in the cases of expected but delayed dripping (Klingenberg, 2007). We did not use this approach because it requires mandatory sedation of the animal and should be applied in extreme cases. If necessary, forced collection of samples is carried out using the cloacal wash method, and for this purpose, we used a venous catheter and a sterile saline solution.

All 51 of the fecal samples were oviscoped by the Faust's flotation method (ZnSO₄ solution) – Figure 1, in order to capture the widest possible range of parasitic eggs with a limited amount of fecal sample (Kanchev et al., 2006). Two of the samples were made with direct smears, one of the faeces and the other obtained by cloacal wash.

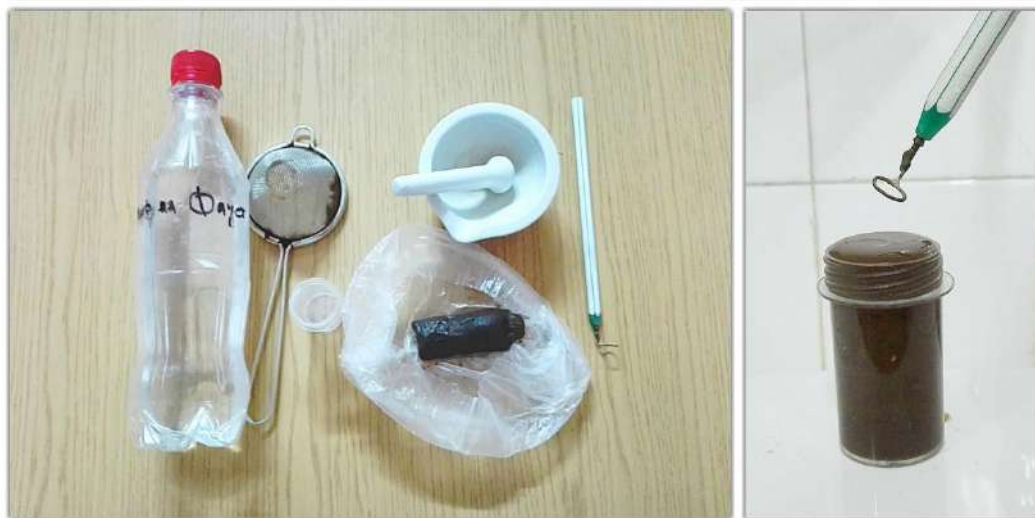

Figure 1:

For the direct smear, we took a little fecal material on a slide and mixed with a few drops of saline, then put a coverslip.

The "cloacal wash" method – is a lavage of a cloacal cavity with sterile saline. An intravenous catheter G16 was used. The needle pulls out slightly so as not to puncture the mucosa, but to serve

as a guide. It is placed in the cloaca, in the cranial direction - after releasing the outer sphincter is inserted inwards and released simultaneously by the needle. From the site of the lock plug, insert several milliliters of saline through a syringe and then pull them back – Figure 2. The amount collected is always less than the penetration - it is enough to draw 1 ml. The collected material was also tested by Faust's flotation method.

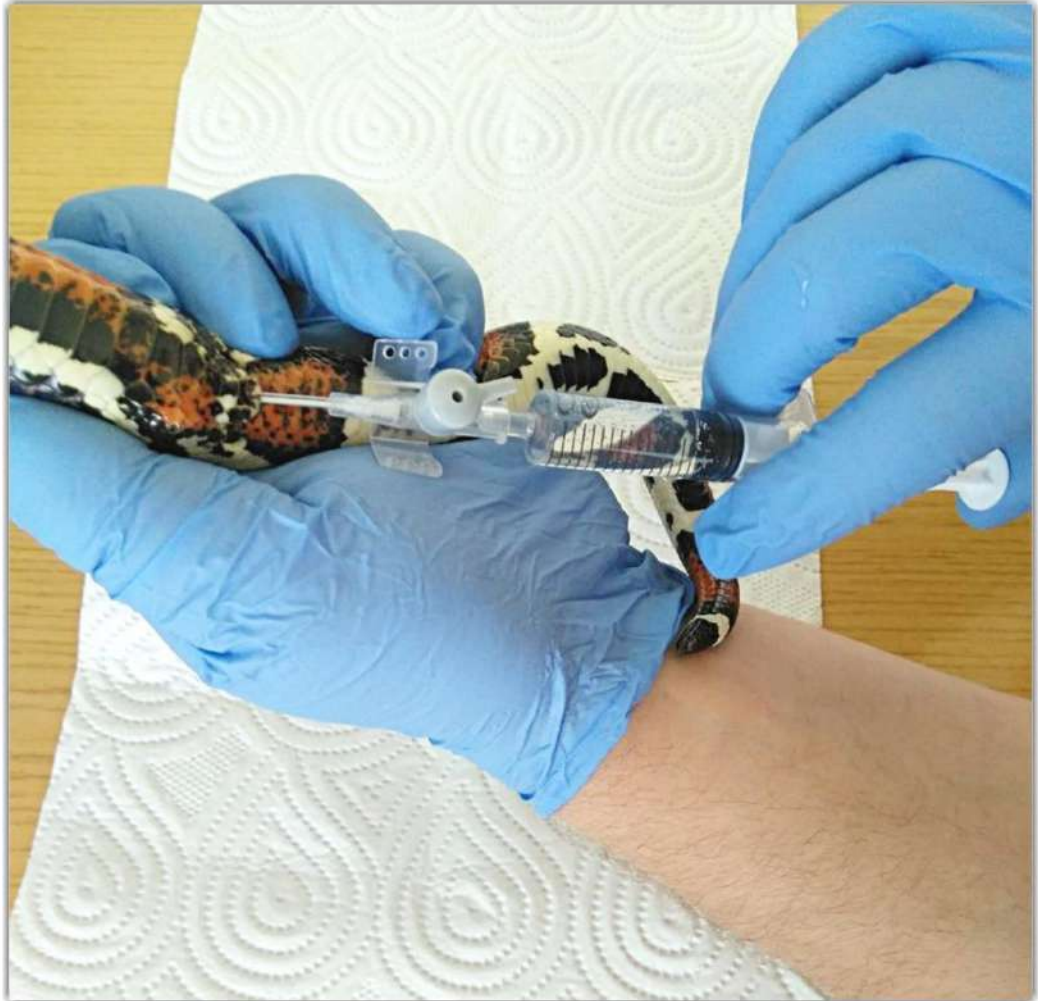


Figure 2:

Results

In nine of the tested fecal samples were found oxyuride ovas (*Oxyuris sp.*). Seven of which are on Corn snakes (*Pantherophis guttatus*), one on Common boa (*Boa constrictor imperator*) and one on Suriname redbtail boa (*Boa constrictor constrictor*). All positive results were found by the Faust's flotation method. The results of the study are presented in Table 1 and Figure 3.

Table 1: Results of the endoparasite study in home-grown snakes

Snake species	Number of samples	Parasitological finding
(+) <i>B. constrictor</i>	2	Oxyuride eggs
(-) <i>B. constrictor</i>	10	negative
(+) <i>P. guttatus</i>	7	Oxyuride eggs
(-) <i>P. guttatus</i>	28	negative
(+) <i>P. regius</i>	0	negative
(-) <i>P. regius</i>	3	negative
(+) <i>E. cenchria</i>	0	negative
(-) <i>E. cenchria</i>	1	negative
Total number	51	-

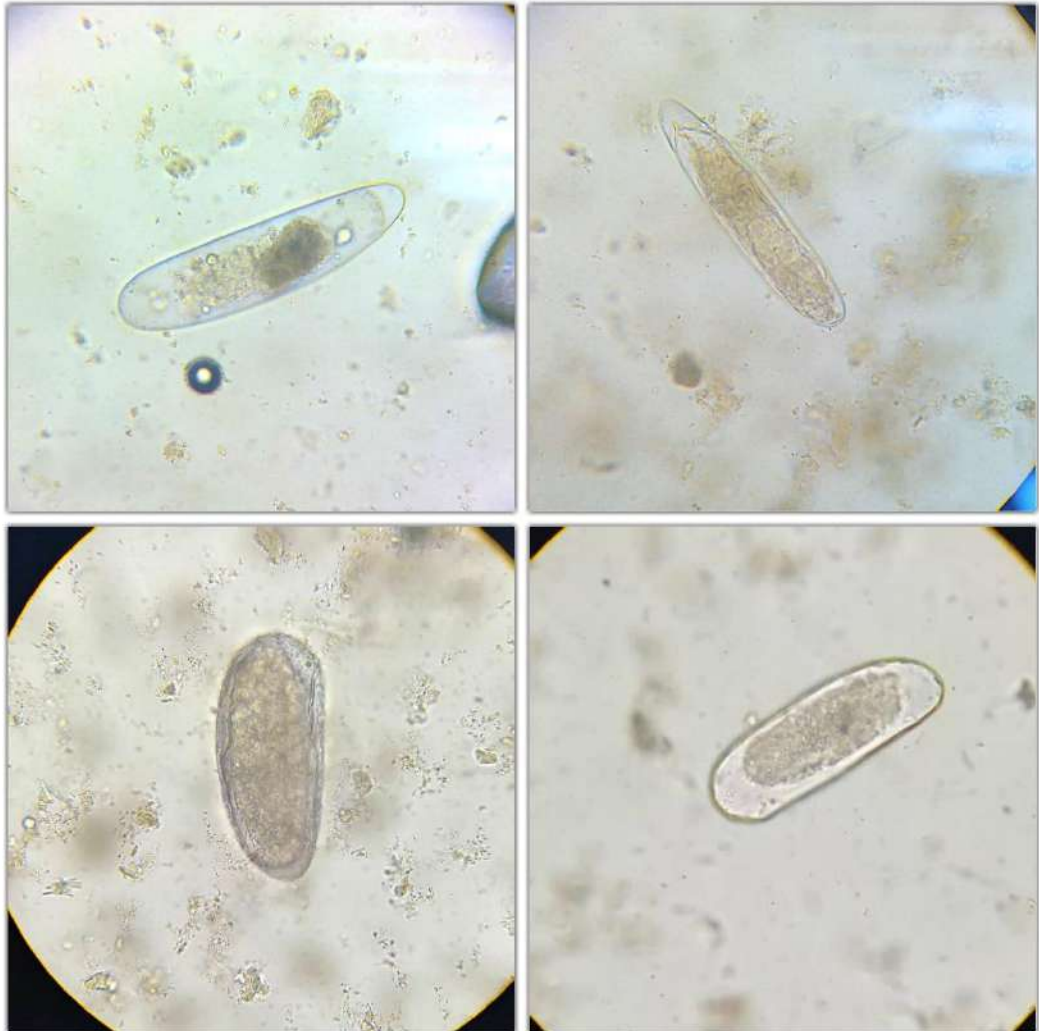

Figure 3:

Possible therapy scheme

In case of need of therapy, the safest and most effective drug is the Fenbendazole (Rossi et al., 2006), a drug of the benzimidazoles group. This antihelminthic inhibits the absorption of glucose in nematodes. The process is slow and this necessitates a consistent application in a scheme for several consecutive days (Klingenberg, 2007). The classical treatment scheme is 25-50 mg kg orally, over 24 hours, for 3 to 5 days, with a repeat after a 10-day rest period (Klingenberg, 2007).

Upon oral administration, fenbenazole is almost non-metabolised and excreted unchanged. There are reports of herpetologists for rectal administration (Innis, 1995) - but it is only effective against nematodes in the cloacal area, not in the anterior sections of the gastrointestinal tract (Klingenberg, 2007).

Prevention

To avoid and minimize stressful situations where even slightly pathogenic parasites have the potential to worsen the general condition of the snakes.

Controlling growing conditions and avoiding the accumulation of parasitic sexual products in the enclosed habitat are a successful approach to prevention of sequential disease. Timely cleaning of feces reduces exposure time and contact with possible parasites in the stools (Russo, 2007). The same goes for the shedded skins (Wagner, 2006).

Since most of the positive findings in the samples are due to rodents fed by snakes, it is necessary to emphasize the maintenance of parasitoses free colonies of such animals (Ballard et al., 2003; Taffs, 1976). For this purpose, they should also be treated regularly and prophylactically and, if necessary, parasitological tests may be carried out.

Discussion

The finding of Oxyuride eggs must be carefully interpreted in a complex way. The mouse Oxyuride eggs are in elongated and larger in sizes (Wright, 2009). Our findings are 175 to 200 μm in length, 47 to 70 μm in width, double wall and morula content. Their transitive character is also guiding.

These eggs are very similar to rodent mite *Myocoptes* eggs, but the animals infested with them show clinical signs with pruritus and poor condition of the fur (Banks et al., 2010).

Most authors recommend at least once a year domestic snakes to be tested for endoparasites (Wagner, 2006; Russo, 2007; Rossi et al., 2006). In the presence of such (most often these are oxyuride eggs), to approach the complex and assess the current condition of the animal and its general condition. It is recommended not to resort immediately to antihelminthics (Bruins, 1999). Wait for the next defecation and take samples again for testing.

In reptiles, even dried fecal samples would give an estimate of infestation - some of the reptiles are adapted to unfavorable conditions, and their parasites are adapted too (Klingenberg, 2007).

Examination the fecal stools from pet snakes is best done using flotation methods. The small amount of fecal sample that makes direct smears does not provide satisfactory results for diagnosing the most parasites unless the infestation is highly elevated but remains a preferable method for the diagnosis of protozoa (Klingenberg, 2007).

In the treatment of snakes against parasites with a direct life cycle, it is also important to take measures to clean and disinfect the terrarium and remove eggs and larvae from the inventory (Wagner, 2006).

Conclusion

1. The findings of oxyuride eggs, in size and morphology, corresponding to mouse Oxyuride eggs.
2. There is no dependence on the age of the snakes (the positive results are from animals between 1 and 9 years old), their type and the oxuroid infestations.
3. The mouse oxyuride eggs pass through the digestive tract of the snakes as these nematodes are host-specific and do not cause infestation and disease in the reptiles.
4. Precise differential diagnosis is based on anamnestic data - specifically the type of diet of domestic snakes.
5. Parasite eggs found must also be differentiated from pseudoparasites - for example, *Myocoptes* rodent ticks, etc.
6. Evidence of the addition of eggs to those of mouse oxyuris are repeated (control) tests with negative results.

References

1. Kanchev, K., Radev, V., Kamenov, Y. (2016). *Rakovodstvo za uprazhnenia po veterinarna parazitologiq*. LTU: pp. 7–11.
2. Ballard, B., Cheek, R. (2003). *Exotic Animal Medicine for the Veterinary Technician*. Blackwell Publishing, 116–117.
3. Banks, R. E., Sharp, J. M., Doss, S. D., Vanderford, D. A. (2010). *Exotic Small Mammal Care and Husbandry*. Blackwell Publishing, 79.
4. Bruins, E. (1999). *The complete encyclopedia of Terrarium*. Rebo International b.v., Lisse, The Netherlands, 194–195.
5. Innis, C. (1995). *Per-cloacal worming of tortoises*. Bulletin of the Association of Reptilian and Amphibian Veterinarians vol. 5, issue 2, 4.
6. Jacobson, E. R. (2007). *Infectious Diseases and Pathology of Reptiles*. Taylor & Francis Group, LLC, 571–665.
7. Klingenberg, R. J. (2007). *Understanding Reptile Parasites*. Advanced Vivarium Systems, Irvine, Second edition, 20–74
8. Mitchell, M. A., Thomas N. T. Jr. (2009). *Manual of Exotic Pet Practice*. Saunders Elsevier, 152–155.
9. Page, L. A. (1966). *Diseases and Infections of Snakes: A Review*. Bulletin of the Wildlife Disease Association: October 1966, Vol. 2, No. 4, pp. 111–126. <https://doi.org/10.7589/0090-3558-2.4.111>
10. Rossi, J., Rossi, R. (2006). *What's Wrong with My Snake?* Advanced Vivarium Systems, Irvine, 62–71.
11. Russo, V. P. (2007). *Boas in Captivity – Professional Breeders Series*. ECO Herpetological Publishing & Distribution, 58-68.
12. Taffs, L. F. (1976). *Pinworms infections in laboratory rodents: A review*. Laboratory Animals vol. 10, issue 1, January 1976, 1–13. <https://doi.org/10.1258/002367776780948862>
13. Wagner, D. (2006). *Boas (A complete pet owner's manual)*. Barron's Educational Series, Inc., Second edition, 45–49.
14. Wilson, S.C., Carpenter, J. W. (1996). *Endoparasitic Diseases of Reptiles*. Seminars in Avian and Exotic Pet Medicine, Volume 5, Issue 2, April 1996, 64–74. [https://doi.org/10.1016/S1055-937X\(96\)80019-3](https://doi.org/10.1016/S1055-937X(96)80019-3)
15. Wright, K. (2009). *Differentiation of reptilian parasites and pseudoparasites*. NAVC Clinician's brief 12, 28–32.