



CODEN [USA]: IAJPBB

ISSN: 2349-7750

INDO AMERICAN JOURNAL OF PHARMACEUTICAL SCIENCES

Available online at: <http://www.iajps.com>

Research Article

MUCOCUTANEOUS SYNDROME IN THE MAXILLOFACIAL AREA IN CHILDREN WITH SYSTEMIC SKLERODERMA

Mamedov A.A.¹, Skakodub A.A.¹, Admakin O.I.², Geppe N.A.³, Morozova N.S.¹,
Kharke V.V.¹, A.B. Maclennan¹

FSAEI of HE I.M. Sechenov First Moscow State Medical University of the Ministry of Health of the
Russian Federation (Sechenov University)

¹Department of Pediatric Dentistry and Orthodontics;

²Department of Prevention and Public Dental Health;

³Chair of Department of Childhood diseases

FSAEI of HE I.M. Sechenov First Moscow State Medical University of the Ministry of Health of
the Russian Federation (Sechenov University).

Address: 2-4 Bolshaya Pirogovskaya st., 119991 Moscow, Russia

Abstract

Systemic scleroderma (SSD) is a rapidly progressing disease with typical changes of the skin in the form of induration and atrophy of locomotor system, internal with fibrosive sclerotic processes in the heart and widespread vascular abnormalities similar to Reynaud's syndrome, in which underlies a conjunctive tissue's damage with fibrosis` predominance and vessels in the form of obliterating endarteritis. Among children this disease can arise at any age, but more often under 10 years old, girls are sick 5 times more often than boys.

The purpose of the research was to identify the main nosological signs of damage to the oral mucosa in children with systemic scleroderma.

Materials and methods of the research: we examined 38 children with diffuse scleroderma and carried out a histomorphologic examination of mucosa.

Results: a typical affection of mouth cavity's mucous membrane is noted having a diffuse scleroderma. The children complain mainly of difficulties when opening the mouth, dryness, numbness of certain areas of the maxillofacial region, burning sensation, taste diversion. Mucousa of the mouth cavity endures 3 phases of main disease's development (non-pitting edema, induration, atrophy). In the beginning we can see such changes of a mouth cavity's mucous membrane as edema, mild hyperemia with obvious vascular pattern, with preserved compliance, sometimes elements of affection, anabrosis, aphthous stomatitis are among common symptoms. If the disease lasts for more than 2 years we can observe the phase of solid edema of mucous membrane turning gradually into the phase of induration when the mucosa is indurated and anematized. Histologic researches of gingival tissue confirm the clinical picture of damage, in 63,3 % determine dystrophy of epithelium, infiltration of epithelium by lymphocytes occurs in about 60%, reduction of blood stream is discovered in 81,8%.

Conclusion: the degree of mouth cavity's mucosa affected in children with diffuse scleroderma depends on the form and duration of the main disease and on complication of baseline therapy which is confirmed by histomorphologic researches of mucous membrane.

Key words:**Corresponding author:****Alla A. Skakodub,**

Postal address: Off.: 204, 2-4 Bolshaya Pirogovskaya st., Moscow 119991, Russia

E-mail: skalla71@mail.ru

Fax: +7(499) 248-01-81

Telephone number: +79032666940

QR code

Please cite this article in press Alla A. Skakodub et al., *Mucocutaneous Syndrome in the Maxillofacial Area in Children with Systemic Skleroderma., Indo Am. J. P. Sci, 2018; 05(10).*

INTRODUCTION:

Systemic scleroderma (SSD) is a progressive disorder of the connective tissue, which includes fibrosis and obliterating endarteritis of the blood vessels. The chief manifestations include thickening, induration and atrophy of the skin, affecting the musculoskeletal system, fibrosis and sclerosis of the internal organs and widespread Raynaud's phenomenon which is defined as a paroxysmal vasospasm [2,3,4,5,6,10].

The disease can occur at any age among the children, but more often up to 10 years. Girls are 5 times more likely to suffer from scleroderma than boys [2,4,6,11].

Etiology of systemic scleroderma is unknown, but there are some theories that it can be caused by supercooling, terebrating and chronic infections, trauma, stress, sensitization, endocrine dysfunction (hypogestrogenia, hypocorticism), inherited factors [3,5,6,7,13].

Previous studies of children with systemic scleroderma by Dr. Skakodub A.A. 2000 [8], showed that there is the entire affection of the maxilla-facial area in 100% of cases (Fig. 1, 2 a-b, 3).

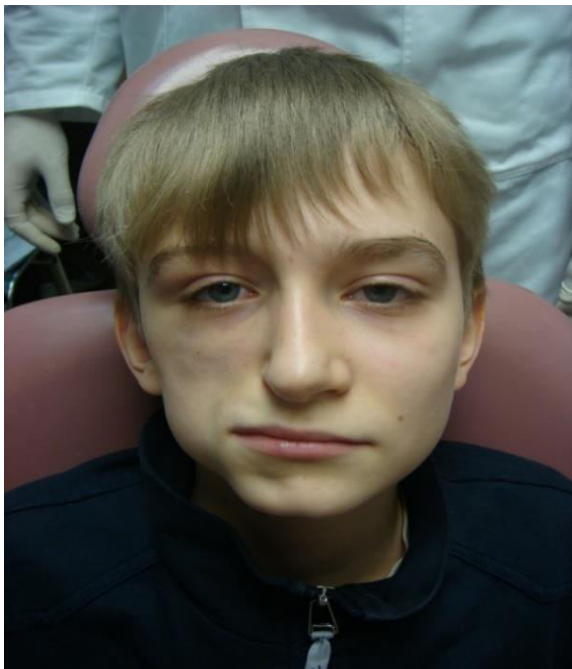


Fig.1: a 12-year-old child, diagnosed with systemic scleroderma, a lesion like “en coup de sabre” in the maxilla-facial area. Published with parent's consent.

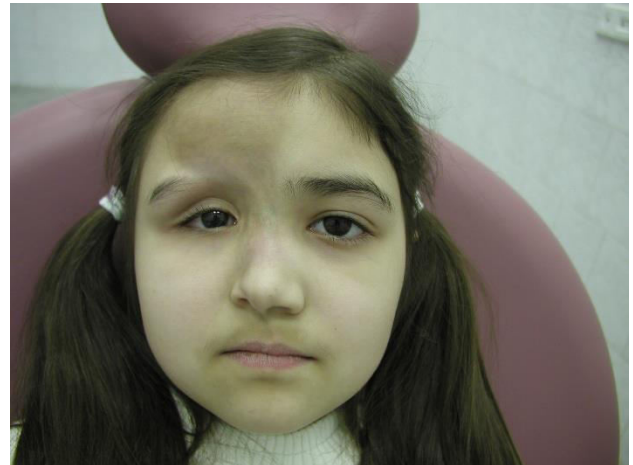

Fig. 2 (a) a 15-year-old child, diagnosed with systemic scleroderma, a lesion like “en coup de sabre” in the maxilla-facial area. Published with parent's consent.

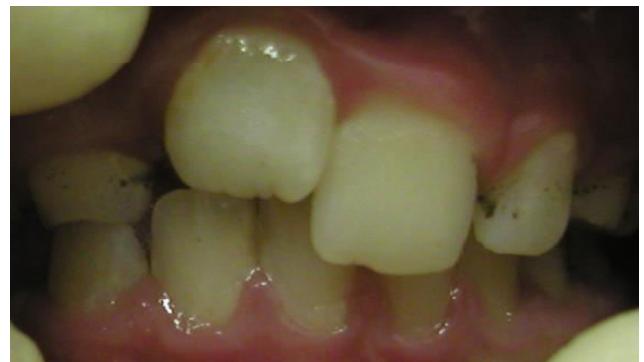

Fig. 2 (b) a 15-year-old child, diagnosed with systemic scleroderma, a lesion of the mouth causes disocclusion of the teeth. Published with parent's consent.

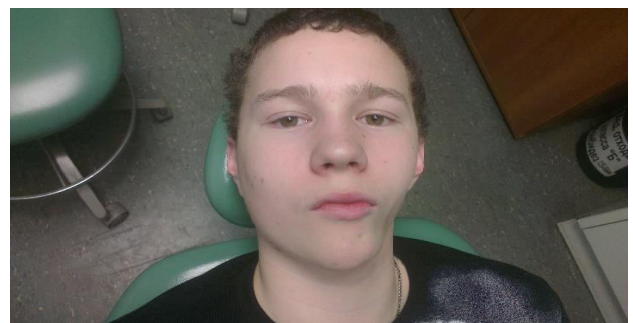


Fig. 3 a 16-year-old child, diagnosed with systemic scleroderma. The «hemiatrophy» lesion in the maxilla-facial area. Published with parent's consent.

The problem of proper diagnostics and dental care was not discussed, therefore we set a goal.

Purpose of the study:

To increase the level of diagnosis of mucosal coat in the oral cavity in children with systemic scleroderma due to identification of the main nosological signs of damage to the oral mucosa in children with systemic scleroderma.

To achieve this goal we set the following objectives.

Objectives of the study

- To conduct a dental examination of children with systemic scleroderma
- To identify the main diagnostic signs of damage to the oral mucosa in children with systemic scleroderma
- To study histo-morphological features of lesions of oral mucosa tissues in children with systemic scleroderma
- To determine the dependence of mucosal lesions on the oral cavity on the duration and nature of the course of the underlying disease and the underlying therapy used.

MATERIALS AND METHODS:

We examined 53 children at the age from 4 to 17 years old with systemic scleroderma. 29 of the children were with a duration of the disease over two years and 24 children up to two years. All children were on the treatment at the University Children's Clinical Hospital of the First Moscow State Medical University named after I.M. Sechenov in the department of rheumatology, where they received basic treatment of glucocorticosteroids, immunosuppressants, cytostatics, drugs that improve microcirculation.

The diagnosis and degree of severity of the disease, among the examined children, were established according to their complaints, clinical and laboratory studies and the medical report of the pediatrician. In order to specify the activity of the disease, it is necessary to study in the blood serum: C-reactive protein (CRP), immunoglobulins (IG), complement, rheumatoid and antinuclear factors, antibodies to DNA.

19 children got through a histo-morphological study of the oral mucosa, such as flushing and mucosal sections were examined to detect histological, morphological, immunohistochemical and viroscopic shifts in the pathological focus and severity of the disease. It also could help to monitor the effectiveness of the local therapy better.

Morphological examination determines the density of the infiltrate of the lamina propria of the gingival mucosa, the structure of the cellular infiltrate: the number of lymphocytes, plasmocytes, macrophages, fibroblasts and fibroblasts, eosinophils and neutrophils.

In the immunohistochemical and virus-optical studies in paraffin sections using the direct immunofluorescent method of Koons, one finds an amount of cells producing IgA, IgM, IgG, IgE, deposition of immune complexes and C3 complement components in the walls of the vessels, as well as the presence of antigens of the Epstein-Barr virus (EBV).

RESULTS AND DISCUSSION:

During dental examination of the children we found that all of them have skin lesions of the face, which are a frequent diagnostic syndrome of the systemic scleroderma. The skin syndrome in 60% (n=17) of patients is the first sign of systemic scleroderma, in 20% it occurs during the first year of the disease, in the others it joins later, after 2-6 years. The skin is cold, dry, due to sweating and sebum, not formed in a crease, the pattern is smoothed. The color becomes parchment or acquires a shade of old ivory with areas of dyschromia and with telangiectasias. The face is masklike, without mimicking and wrinkles (Figure 4 a, b).

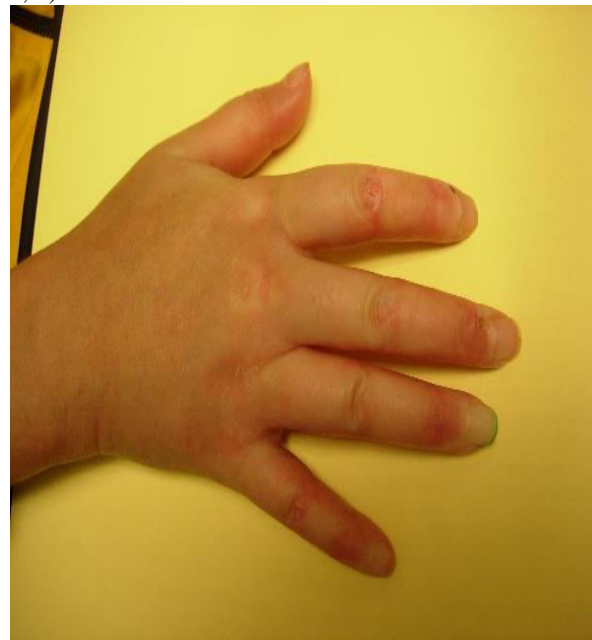

Fig.4 a. the 13-year-old child diagnosed with systemic scleroderma. Published with parent's consent.

- a. - the skin is cold, dry, the color becomes parchment or acquires a shade of old ivory with areas of dyschromia and with telangiectasias.



Fig.4 b. the 13-year-old child diagnosed with systemic sclerosis. Published with parent's consent.

b. - masks face, without mimicking and wrinkles. A specific lesion of the mucous membrane of the oral cavity is noted in patients with systemic sclerosis. The main complaints in children are a difficult opening of the mouth, dryness, numbness of certain areas, burning, change in taste. The mucous membrane of the oral cavity with systemic sclerosis, like the skin, undergoes three stages of development of the disease: complete swelling, induration, atrophy (Fig. 5).

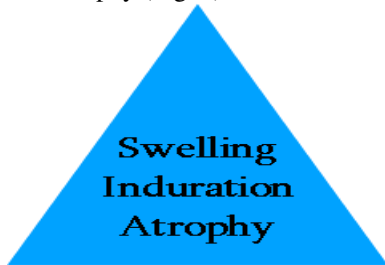


Fig. 5. Stages of the development of mucosal lesions in systemic sclerosis:
complete swelling, induration, atrophy.

The defeat of the oral mucosa in patients with systemic sclerosis begins with the lips. A small swelling, edema of the mucous membrane and submucosal tissue manifest this. In the stage of dense edema, the most frequent feature is a violation of the clear border of the red border of the lips. The second stage of the development of the systemic sclerosis is the stage of induration, which is characterized by a hardening of the patient's lips. In the atrophic stage

there are such characteristics as brown pigmentation, the mucous membrane is sharply thinned, dry, the elasticity is lost and there is total atrophy of the mucous lips and the formation of microheilia. (Fig. 6a, b).

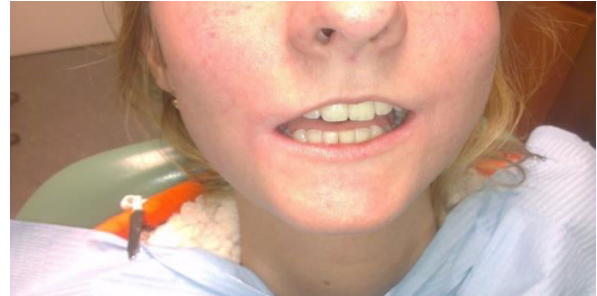

Fig. 6 Systemic sclerosis, violation of a clear boundary of the red border of the lips, sharp thinning, dryness, loss of elasticity. Published with parent's consent.

a. - Formation of microheilia and microstoma.

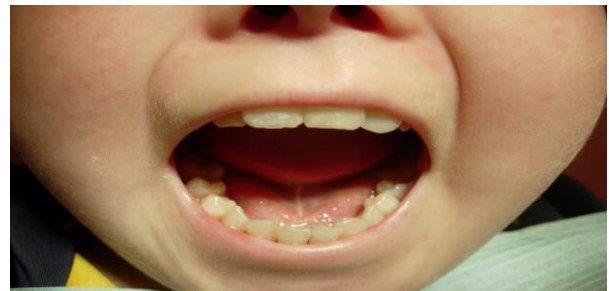

Fig. 6 Systemic sclerosis, violation of a clear boundary of the red border of the lips, sharp thinning, dryness, loss of elasticity. Published with parent's consent.

b. - Formation of the microstoma.

A characteristic symptom of sclerosis is a change in the tongue, with both the mucous membrane and the muscle layers, which leads to microglossia (Fig. 7, 8). In patients due to atrophy of the filiform papillae, the surface of the tongue has a smoothed polished appearance, thus, atrophic glossitis is developing.

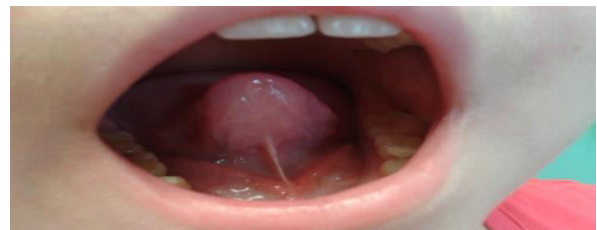

Fig. 7. The 13-year-old child with the systemic sclerosis. Formation of microglossia. Published with parent's consent.

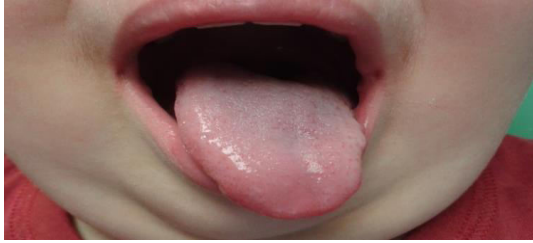

Fig. 8. The 10-year-old child with the systemic scleroderma. There is a local atrophy of the tongue. Published with parent's consent.

There is a fast involving of a lingual frenulum to the process of atrophy and scleroderma, while its shortening and sharp immobility are noted-this is the earliest diagnostic sign of the manifestation of systemic scleroderma (Fig. 9, 10).

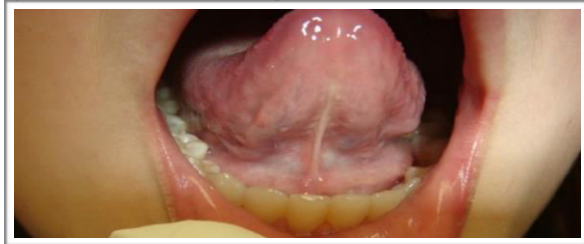

Fig. 9. A 13-year-old child with systemic scleroderma.

Shortening of the frenum of the tongue in children with a duration of disease of more than 2 years suffering from systemic scleroderma. Published with parent's consent.

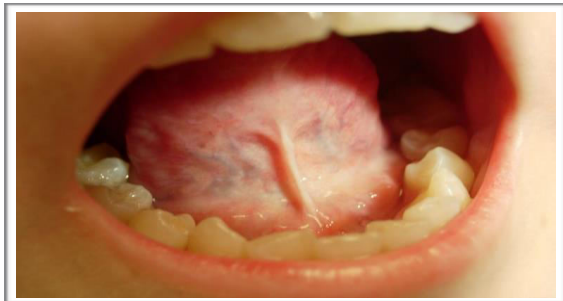


Fig. 10. A 13-year-old child with systemic scleroderma. Sharp thinning, persistent atrophy and immobility of the frenum of the tongue. Published with parent's consent.

In the process of atrophy and sclerosis, the sublingual frenulum is involved particularly quickly, with its shortening, compacting, sharp immobility, which is the earliest diagnostic sign of the manifestation of systemic scleroderma.

Features of changes in the mucosa of the oral cavity in systemic scleroderma: loss of shine and elasticity, the presence of telangiectasias, a sharp thinning of the mucosa, atrophy of periodontal tissue is often primary local, with a duration of the disease more than 2 years, atrophy is generalized (Fig. 11,12,13).

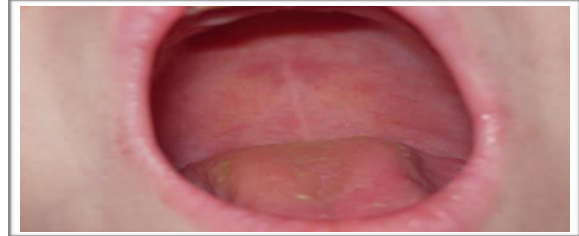

Fig. 11. A 16 year-old-child with systemic scleroderma. There are a mucosal atrophy, loss of shine and elasticity, presence of telangiectasias, sharp thinning. Published with parent's consent.

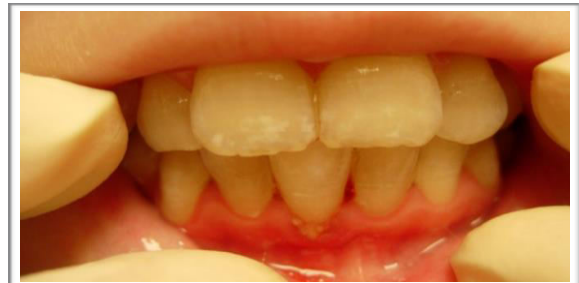

Fig. 12. A child at the age of 13 years old, systemic scleroderma; there is a local atrophy of periodontal tissues in the region of the tooth 4.1. Published with parent's consent.

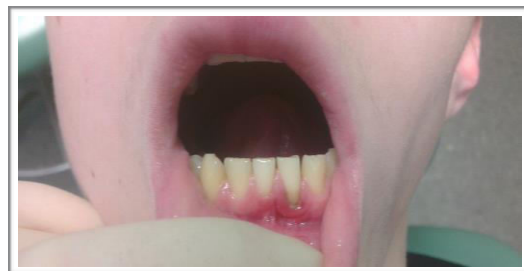

Fig. 13. A 16-year-old child with systemic scleroderma, local atrophy of periodontal tissues in the tooth area 3.1. Published with parent's consent.

The examinations conducted by us allowed us to establish the main diagnostic signs of the lesion of the maxilla-facial region in children with systemic scleroderma (Table 1).

Table. 1: Diagnostic signs of systemic scleroderma in the maxilla-facial area in children

Diagnostical findings	A number of children (n=53) (100%)
Involving of lip's mucosa: - sharp thinning, partial atrophy of the mucosa - atrophy of the lips, narrowing of the oral cavity «microstoma» - symptom "incompletely tightened pouch" induration and atrophy of the mucous and cutaneous part of the lips	n=22 (41.5 %) n=11 n=9 n=2
Lesion of the tongue mucosa: - desquamative glossitis - atrophic glossitis - microglossia	n=19 (35, 85 %) n=9 n=7 n=3
Lesion of the frenulum of tongue - ischemia (whitening) - induration - atrophy	n=25 (47, 16 %) n=6 n=10 n=9
Lesion of the facial skin - partial hemiatrophy - «masc» face	n=15 (28, 3 %) n=8 n=7

All processes of sclerosis of the mucosa are irreversible and lead to severe suffering of patients, due to the limitation of the mobility of the tongue, soft palate, reduction of the depth of the vestibule of the mouth, speech impairment, changes in taste sensations, thinning of the mucosa and easy traumatism. We also observed the adding of a secondary infection after the beginning of treatment with glucocorticosteroids and with the exacerbation of the underlying disease in the form of fungal and viral infections (Figures 14,15).

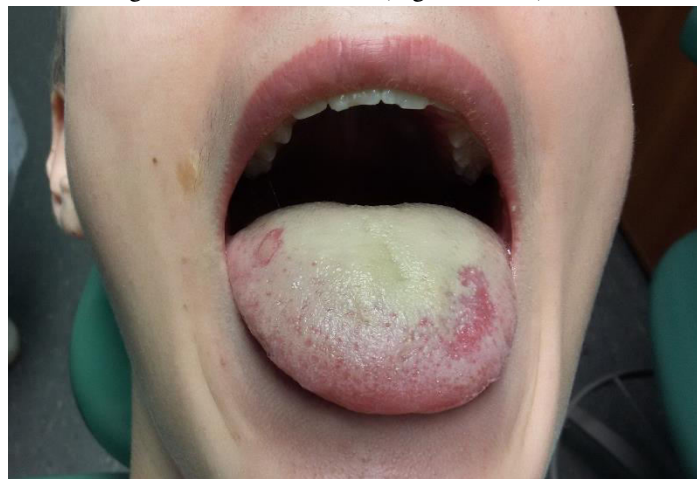


Fig. 14. A 15-year-old child with systemic scleroderma, lesions of the oral mucosa caused by the adding of a secondary infection, candidiasis glossitis. Published with parent's consent.

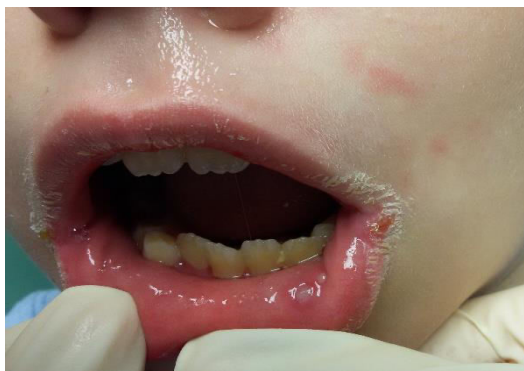

Fig. 15. A 12-year-old child with systemic scleroderma, lesions of the oral mucosa caused by adding of a secondary infection, acute herpetic stomatitis. Published with parent's consent.

In a histo-morphological study of the gingival tissue in patients with systemic scleroderma, epithelial degeneration and hyalinosis were recognized. The reduction of the vascular bed is revealed in patients with systemic scleroderma. Vasculitis were found in 1/3 of the cases, vasculopathy in 54,4%.

The degree of involvement of the oral mucosa in children with systemic scleroderma depends on the form and duration of the disease and the complication of basic therapy, as evidenced by histo-morphological studies of the mucous membrane.

Thus, the results of studying the state of the oral mucosa in patients with systemic scleroderma showed that:

- Skin and mucous syndrome is one of the most important and frequently occurring manifestations of the disease;
- Signs of the damage of the mucous membrane of the oral cavity appear at the earliest stages of the disease and acquire the greatest severity in the course of the development of the disease;
- Changes in the oral mucosa are associated with the development of dystrophic and atrophic processes, noted by almost all examined patients. Their severity usually corresponds to the nature of the stage disease and the adding of a secondary infection.

ACKNOWLEDGEMENTS:

I wish to thank Olga Spitonkova, Head of the Rheumatology Department, for assisting in the complex examination and treatment of children with systemic scleroderma. The authors report no conflicts of interest related to this study.

REFERENCES:

1. Vinogradova T. F. 2014. Dentistry for pediatrician. Russia. M.: MED press-inform : 187–91.

2. Volkov A.V., Starovoitova M.N., Guseva N.G 2004. Features of clinical manifestations and course of systemic sclerosis, depending on sex and age of onset. Russia Ter. Archive. №5, 7-11.
3. Lyskina G.A. 1994. Systemic vaskulitis in children. Clinical manifestations, diagnostic, treatment. Russia. Avtoref. diss. DDS. M.
4. Mamedov Ad.A., Jolobova E.S., Admakin O.I., Kharke V.V., Solop I.A., Kozlitina Yu.A. Disorders of growth and development of maxillofacial area in children with juvenile rheumatoid arthritis. J Dentistry No. 5, 2011, 81-4.
5. Osminina M.K., Gepe N.A., Afonina E.Y., Shpitonkova O.V., Perepelova E.M. Genetically engineered biological preparations in the treatment of scleroderma. A review of the literature and own experience. Doctor. Roux. Pediatrics. No. 13 (114), 2015:53-8.
6. Nasonov E.L., Nasonova V.A. 2008. Rheumatology. National guidance. 25 Russia: M.: GEOTAR-Media;:
7. Gepe N.A., Podchernyaeva N.S., Lyskina G.A. 2011. Pediatric Rheumatology, guidance. Russia: M.: GEOTAR-Media. 13–22, 587–95.
8. Skakodub A.A. Oral cavity disorders in children with diffuse scleroderma. Avtoref. diss. PHD. M., 2000. (Russia)
9. Lange R.P., Miller K.S. 2008. Oral cavity disorders. Atlas. M.: GEOTAR-Media; 182–3.
10. Falanga V, Medsger TA Jr, Reichlin M, et al. Linear scleroderma. Clinical spectrum, prognosis, and laboratory abnormalities. Ann Intern Med 1986;104:849Y857
11. Garcia-de la Torre I, Castello-Sendra J, Esgleyes-Ribot T, et al. Autoantibodies in Parry-Romberg syndrome: a serologic study of 14 patients. J Rheumatol 1995;22:73Y77
12. Suri L, Gagari E, Vastardis H. Delayed tooth eruption: pathogenesis, diagnosis, and treatment.

- A literature review. Am J Orthod Dentofacial Orthop 2004;126:432Y445
13. Dervis E. Progressive hemifacial atrophy with linear scleroderma. *Pediatr Dermatol* 2005;22:436Y439
14. Laskaris G. 2006. Treatment of Oral diseases. A concise textbook. Thiema Stuttgart. New York : 47-9.