

Limited internal fixation in the distal metaepiphyseal shin fractures

Olexandr Koval, MD, PhD Applicant; *Volodimir Vasyuk, MD, PhD, Professor

Department of Traumatology and Orthopedics, Bukovinian State Medical University, Chernivtsi, Ukraine

*Corresponding author: drvasyuk@bigmir.net. Received September 03, 2018; accepted October 10, 2018

Abstract

Background: The scientific papers deal with it reporting different treatment technologies for distal tibia metaepiphysis fractures; meanwhile the complication and failure rates remain high.

Material and methods: 265 patients were examined. Their average age was 45.15 ± 15.98 years (from 18 to 86). The patients were distributed into clinical groups according to the type of surgery performed. Clinical group I included patients who underwent mini-invasive osteosynthesis with K-wires and screws (113 patients, 42.64% from general group); Clinical group II included patients with external fixation osteosynthesis (36 patients, 13.58%); and Clinical group III included patients who underwent osteosynthesis with plates (116 patients, 43.77%).

Results: The technology of mini-invasive osteosynthesis of distal metaepiphysis fractures of the lower leg is improved. Reposition is performed under general or conduction anaesthesia under C-arm control. Ligamentotaxis principle is applied pulling fragments by means of distractor. In case separate bone fragments are not repositioned a pricker, single-toothed tenaculum are used through separate pricks of the skin. Every step is controlled by imagic intensifier. After subluxation is eliminated and reposition completed, trans-articular fixation of fragments is performed inserting 2-3 K-wires 2 mm in diameter from the sole in the direction of the tibia middle part.

Conclusions: The analysis of implementation of the improved mini-invasive osteosynthesis technology for fractures of the distal lower limb compared with the traditional methods of surgical treatment of these injuries in 265 patients from the three clinical groups demonstrated that the use of closed reposition and improved technique results in improved results and considerable reduction of costs for treatment in comparison with traditional osteosynthesis.

Key words: mini-invasive osteosynthesis, distal shin fractures.

Introduction

A number of scientific papers deal with the issues of surgical treatment of distal shin fractures (43 and 44 segments by AO), reporting about different aspects of treatment of distal tibia metaepiphysis (so-called pilon) fractures [2, 5, 6, 7, 9]. The main mechanisms of these fractures are injuries of drivers or passengers during road accidents or falling from a height. As a rule, similar fractures occur in persons of young and middle age. These injuries are characterized by bone fragmentation with considerable dislocation of fragments and formation its defects in the metaepiphysis zone with various injuries of the articular surface, soft tissues and neurovascular bundle. Pilon fractures are known to be a frequent component of multiple traumatic injuries.

The volume and character of injury depends on power properties of the osseous tissue, position of the foot during injury, volume and point of traumatic force application. Pilon fractures, especially in case of multiple traumatic injuries, result in great variety, and their treatment remains one of the most complicated problems [2, 6, 9].

Modern traumatology contains great arsenal of osteosynthesis technologies to perform stable fixation of distal tibia fractures [3, 4, 5, 10, 12, 13, 14]. Unfortunately, fractures of this localization are the leaders by the number of complications (up to 30%) and unfavourable consequences. Certain authors report about development of deforming arthrosis transformed into fibrous ankylosis in 16% of cases. The causes of this condition are first of all circulatory disorders in the area of fracture and technical problems while performing surgery [1, 8, 11, 15].

For recent fifty years the philosophy of AO surgical

treatment of fractures has changed. Surgical AO principles were first defined in 1958 in the following way:

1. Restoration of anatomy ("fragment-to-fragment" reposition was recommended);
2. Stable fracture fixation, compression between fragments;
3. Preservation of blood supply;
4. Early active mobilization.

The AO principles have evolved and changed periodically. In recent 10-15 years they are guided by more comprehensive realization of biological principles as an important factor of proper fracture healing and functional restoration. Traumatology has gradually transformed into X-ray-associated surgery. Major access was changed into minor cuts, step-by-step X-ray inspection, minor access surgery, mini-invasive plate osteosynthesis (splinting), arthroscopy-associated surgery. This technological modernization has resulted in transformation of priorities, and today the AO principles are as follows:

1. Preservation of blood supply;
2. Functional (indirect) reposition;
3. Stable fixation;
4. Early active mobilization.

Placing the care of blood supply of the bone and soft tissues in the first position the role of biology as a prior factor of proper healing is emphasized again.

Objective of the work is to improve the results of surgical treatment of distal metaepiphysis fractures of the tibial and fibular bones by means of development, substantiation and implementation of the improved technology of mini-invasive osteosynthesis.

Material and methods

In the process of investigation the AO classification and Rüedi-Allgöwer (Ruedi-Allgöwer) classification of pilon fractures were used (tab. 1).

In case of impression fracture a trepanation opening is made 5-6 cm proximally from the joint, and through this opening by means of a special instrument articular surface is restored, and autograft is inserted into the opening (fig. 2).

Table 1

Classification of the distal tibia fractures

A	B	C
<p>AO Classification. 43 – tibia/fibula, distal segment.</p>	<p>AO Classification. 44 – tibia/fibula, malleolar segment.</p>	<p>Rüedi-Allgöwer classification of pilon fractures</p>

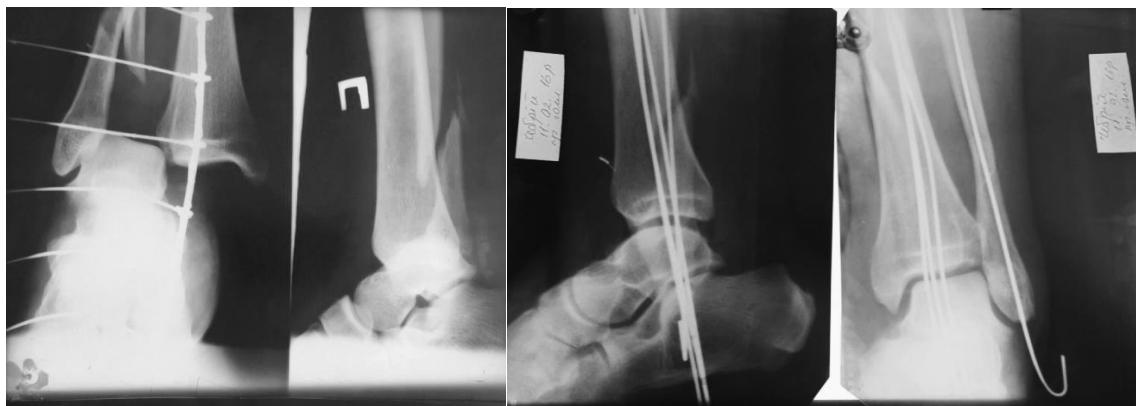

Fig. 1. Trans-articular fixation after luxation elimination and closed intramedullary osteosynthesis of the fibula.

We have improved the technology of mini-invasive osteosynthesis of distal tibia metaepiphysis fractures. Reposition is performed under general or regional anaesthesia controlled by C-arm. Ligamentotaxis principle is applied pulling fragments by means of distractor. In case separate bone fragments are not repositioned a pricker, single-toothed tenaculum are used through separate pricks of the skin. Every step is controlled by imagic intensifier. After subluxation is eliminated and reposition completed, trans-articular fixation of fragments is performed inserting 2-3 K-wires 2 mm in diameter from the sole in the direction of the tibia middle part (fig. 1).

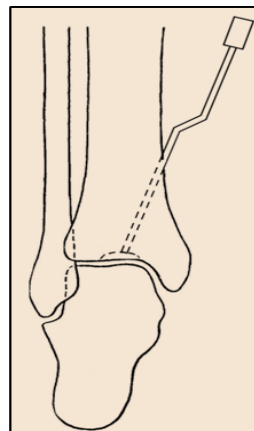


Fig. 2. Figure of impression fracture reposition of the articular surface of the distal tibia epiphysis.

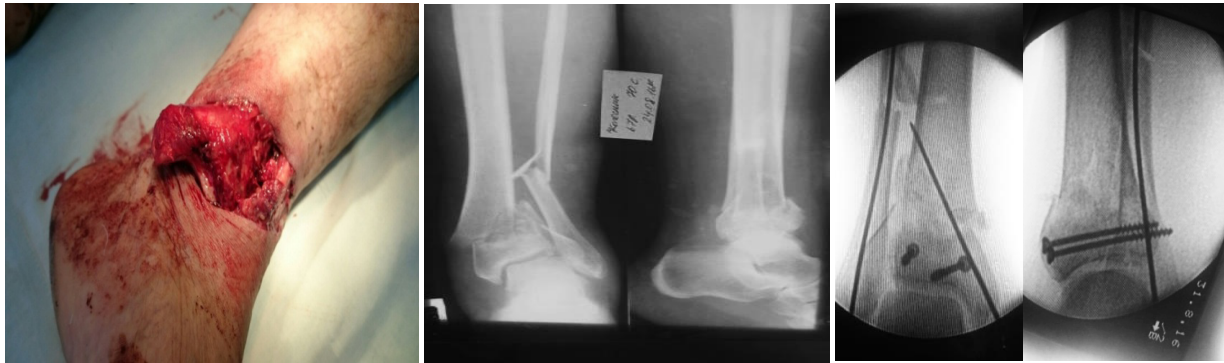

Fig. 3. Mini-invasive osteosynthesis of the distal tibia with screws inserted in sagittal plane.

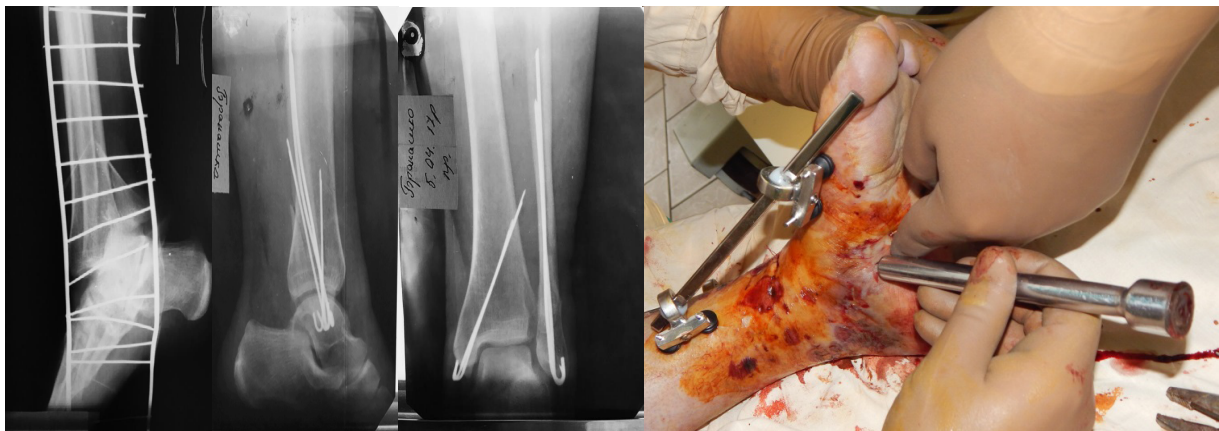


Fig. 4. Mini-invasive osteosynthesis of the internal and external malleolus. K-wires are bent in the shape of a hook and inserted under the skin.

After that, K-wires are inserted through separate pricks in the skin in the sagittal plane 3-4 mm proximally from the ankle joint, and fragments forming the articular surface are fixed. In some cases K-wires are changed into cannula or common screws (fig. 3).

In case of external malleolus dislocation, it is reduced and closed intramedullary osteosynthesis with one or two K-wires is performed. The internal malleolus is fixed in the same way (fig. 4). In some cases K-wires are bent in the shape of a hook and inserted under the skin. It prevents possible infection of tissues round the K-wires.

In case of fractures with partial contact between fragments (43 A and 43 B by the AO classification, or type 1 and

type 2 by Rüedi-Allgöwer classification of pilon fractures) the bone is immobilized with orthosis or plaster splint which is changed into scotch-cast 7 days later. In case of unstable fractures with no contact between the main fragments (43 C or type 3 by Rüedi-Allgöwer classification of pilon fractures) the bone was immobilized by means of an improved variant of external fixation device (EFD) (fig. 5). K-wires were removed 6 weeks later. The period of immobilization lasted for 10-12 weeks.

At the beginning of application of this technique indications for mini-invasive osteosynthesis were: multiple traumatic injuries, diabetes mellitus, old age, severe comorbid pathology, "economic factors". In the course of time, accumulated experience enabled to apply this method wider.

In the clinic of the Department of Traumatology and Orthopedics of Bukovinian State Medical University on the base of Chernivtsi Emergency Hospital during the period from 2007 to 2017, 342 patients – 206 men (60.23%), and 136 women (39.77%) – with fractures of distal segments of the lower leg were operated, including 105 patients with fractures of the distal metaepiphysis of the tibia and fibula (segment 43 by the AO classification, table 1A), and 237 individuals with fractures of the crura (bone segment 44 by the AO classification, table 1B).

265 patients were examined in the process of performing the study. Their average age was 45.15 ± 15.98 years (from 18 to 86), including patients under 30 – 52 (19.62%), from 30

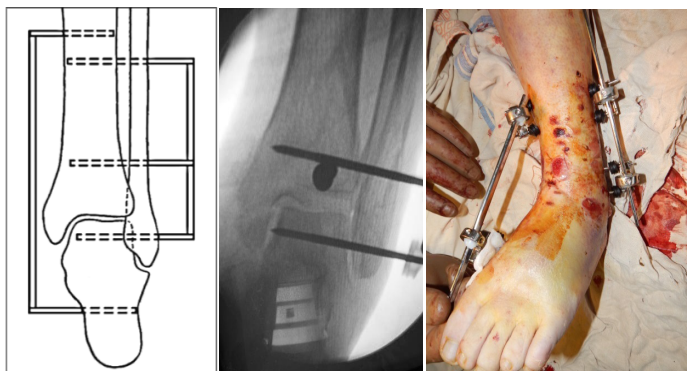


Fig. 5. Drawing and photo of the device for external osteosynthesis of distal tibia fractures.

to 40–56 individuals (21.13%), from 40 to 50– 52 individuals (19.62%), from 50 to 60– 47 (17.74%), older than 60– 58 (21.8%) (fig. 6).

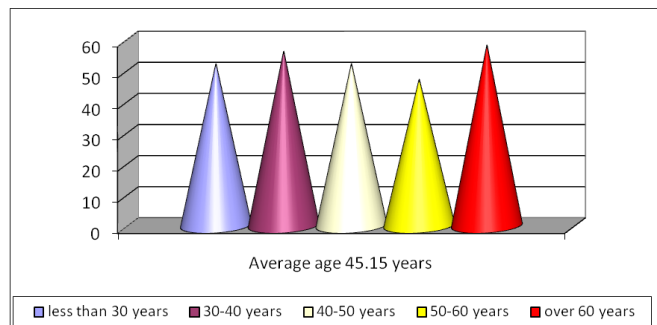


Fig. 6. Distribution of patients by age.

Males constituted the greater part of all the patients examined – 152 individuals (57.36%), females – 113 (42.64%) respectively. Open fractures were registered in 72 (27.17%) patients, closed – 184 (72.83%).

Osteosynthesis was performed on 265 patients, including plates (“clover leaf”) – 63 patients (23.77%), LCP (with angle stability) – 21 patients (7.92%), K-wires – 57 patients (21.51%), external fixation – 19 patients (7.17%), external fixation + K-wires – 14 patients (5.28%), external fixation + plates – 23 patients (8.68%), external fixation for minor segments – 68 patients (25.66%).

Kinds of injuries were evidenced in 265 patients including 7 cases of occupational injuries (2.64%), 21 – road accidents (7.92%), 235 cases of off-the-job injuries (88.68%), 1 case of sport injury and 1 criminal (0.38% each). Thus, off-the-job injuries prevailed (fig. 7). It should be noted that real percentage of off-the-job injuries was not so high, since they included not only home accidents, but also concealed injuries in the street, occupational ones, sport injuries, due to road accidents, etc.

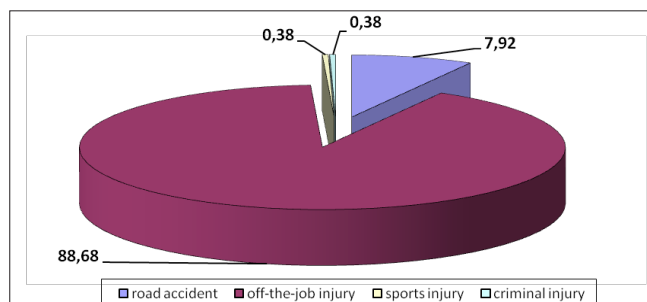


Fig. 7. Distribution of patients by the types of injuries, %.

One of the considerable parameters indicative of the efficacy of the given medical manipulations is the length of hospital stay, including preoperative and postoperative hospital stay. This index is substantially influenced by severity of injury, availability or lack of complications.

In general clinical group the preoperative hospital stay averaged 4.95 days (from one day to a month). The patients were distributed accordingly: less than 10 days before sur-

gery – 210 patients (79.25 %), from 10 to 20 days before surgery – 47 patients (17.73%), from 20 to 30 days – 8 patients (3.02%), (fig. 8).

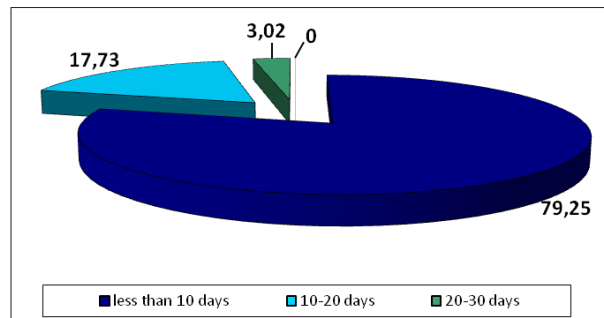


Fig. 8. Distribution of patients by preoperative hospital stay, %.

Postoperative period in general group was on an average 18.69 days (from 1 day, when surgery was performed on the day of admission, to 155 days). Less than 10 days – 69 patients (26.04%), 10 to 20 days – 131 patients (49.43%), 20 days to 1 month – 35 patients (13.21%), and over a month – 30 patients (11.32%), (fig. 9). Although the number of patients with multiple traumatic injuries, infectious complications and protracted traumatic disease was not big, it made an average overall hospital stay considerably longer. We did not think it to be reasonable to exclude those patients from sampling (150,180 bed days). At the same time, in spite of severity of injuries, 75.47% of patients stayed in the hospital less than 20 days.

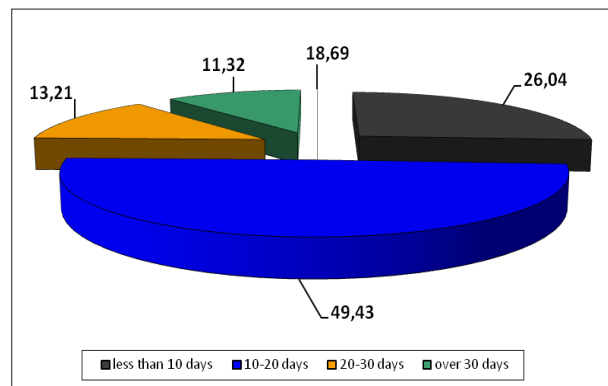


Fig. 9. Distribution of patients by postoperative hospital stay, %.

Distribution of patients into clinical groups depending on surgery performed

The patients were distributed into clinical groups depending on the type of surgery performed.

Clinical group I included patients, who underwent mini-invasive osteosynthesis with K-wires and screws (113 patients, 42.64% from general group); **clinical group II** included patients with external fixation osteosynthesis (36 patients, 13.58%); and **clinical group III** included patients who underwent osteosynthesis with plates (116 patients, 43.77% from general group, fig. 10).

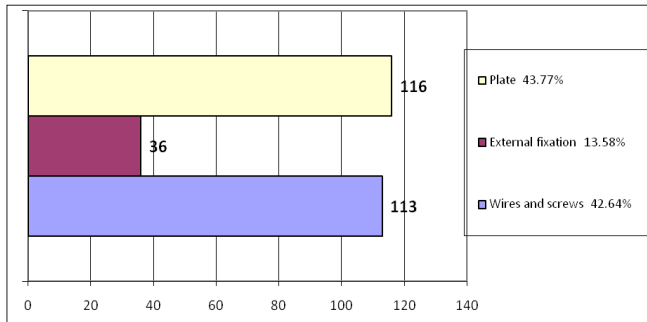


Fig. 10. Distribution of patients by osteosynthesis types into groups.

In **clinical group I** where mini-invasive osteosynthesis was performed, patients older than 60 prevailed – 33 individuals (29.20%). The following age groups included those aged from 30 to 40 (22 patients, 19.47%), 50-60 years (21 patients, 18.58%), less patients in the age group from 40 to 50 (20 individuals, 17.70%), and the least number – under 30 years (17 individuals, 15.04%). There were 51 women among patients (45.13%) and 62 men (54.87%).

This group included 77 patients (68.14%) with closed fractures and 36 patients (31.86%) with open ones. Distribution of patients by diagnosis according to AO code is given in table 2.

Table 2

Distribution of patients by diagnosis (according to AO code)

AO code	Individuals	%
43.A1	3	2,65
43.A2	11	9,73
43.A3	5	4,42
43.B1	2	1,77
43.B2	2	1,77
43.B3	3	2,65
44.A1	1	0,88
44.A2	17	15,04
44.A3	13	11,50
44.B1	2	1,77
44.B2	8	7,08
44.B3	43	38,05
44.C1	1	0,88
44.C2	2	1,77
43.C3	3	2,65
Total	113	100%

Osteosynthesis was performed in 113 patients including 30 patients with primary wound debridement and closure (26.55%), closed osteosynthesis – 13 patients (11.50%), open osteosynthesis – 9 patients (7.96%), and 61 patients with mini-invasive osteosynthesis (53.98%), (fig. 11).

In this clinical group the patients were distributed in the following way by the types of traumas: off-the-job inju-

ries – 98 patients (86.72%), occupational injury – 8 patients (7.09%), and 7 patients after road accidents (6.19%).

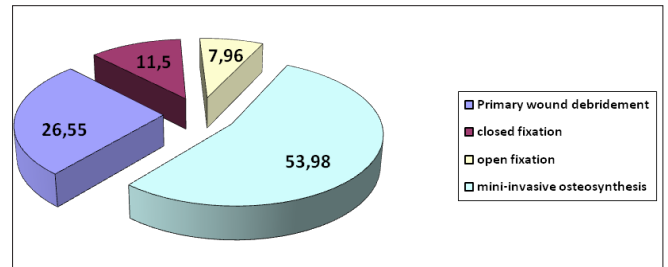


Fig. 11. Distribution of patients from clinical group I by osteosynthesis techniques, %.

Preoperative hospital stay in patients of this clinical group was in an average 4.5 days (from 1 day to 4.5 months). The patients were distributed in the following way: less than 10 days before surgery – 89 (84.08%); from 10 to 20 days before surgery – 17 patients (15.04%); from 20 days to one month – 1 patient (0.88%); more than 1 month – 6 patients (15.04%).

Postoperative hospital stay in this clinical group was on an average 17.32 days (from 1 day to 3 months) – to 10 days – 35 patients (30.97%), from 10 to 20 days – 51 patients (45.13%), from 20 days to 1 month – 17 patients (15.04%) and more than one month – 10 patients (8.85%), (fig. 12).

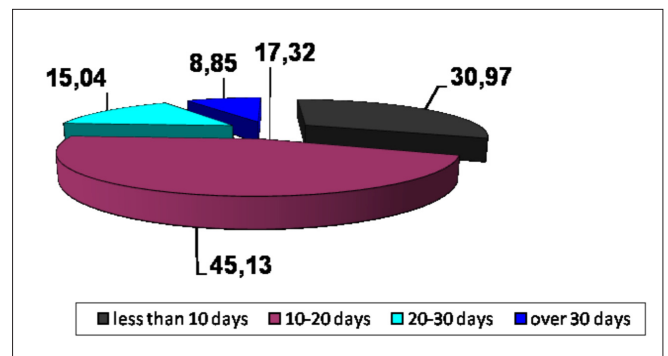


Fig. 12. Postoperative hospital stay in patients from mini-invasive synthesis group, %.

Overall hospital stay was on an average 2.5 weeks (from 2 weeks to 3.5 months).

Clinical group II of patients by the type of surgery – osteosynthesis with external fixation – included 36 patients (13.58%) from the general group.

In the group of patients with external fixation the patients aged from 40 to 50 prevailed – 11 individuals (30.56%) with an average index in the group was 48.20 ± 16.59 years. The following age groups were 30-40 years – 7 patients (19.44%), 50-60 years – 6 patients (16.67%) and older than 60 years – 7 patients, (19.44%). The patients under 30 were in minority – 5 patients (13.89%), (fig. 13).

An average age was 46.05 years including 14 women (38.89%) and 22 men (61.11%).

In this clinical group there were 7 patients with closed fractures (19.44%), and open ones – 29 (80.56%).

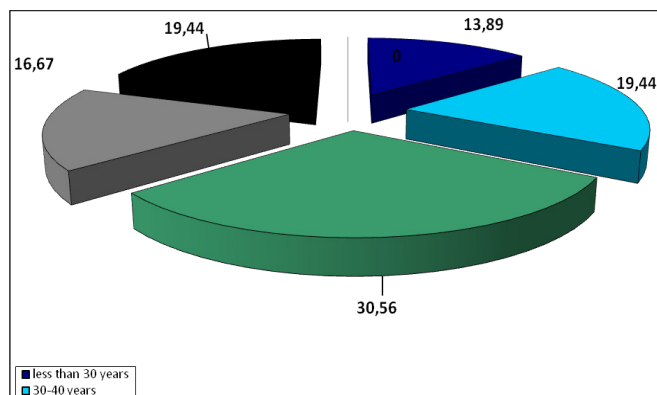


Fig. 13. Distribution of patients by age in the group with external fixation, %.

In this clinical group osteosynthesis was performed in 36 patients, including 18 patients with primary surgical treatment of the wound (50.0%), closed osteosynthesis – 3 patients (8.33 %), open osteosynthesis – 10 patients (27.78%), 1 patient with changed method of treatment of the right tibia to external fixation (2.78%), with Ilizarov’s external fixator – 4 patients (11.11%), (fig. 14).

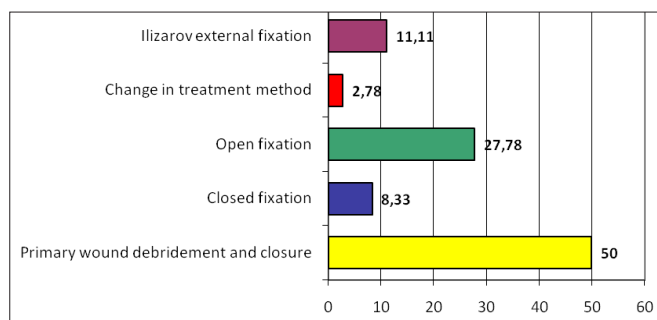


Fig. 14. Distribution of patients from the group of external fixation by the types of osteosynthesis, %.

Types of injuries treated by means of surgical aid among the patients from this clinical group were distributed in the following way: off-the-job injury – 26 patients (72.22%), occupational injury – 6 patients (16.67%) and 4 patients after road accidents (11.11%).

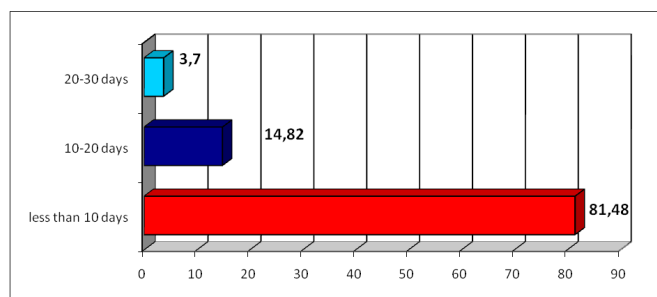


Fig. 15. Distribution of patients from the group of external fixation by preoperative hospital stay, %.

Preoperative hospital stay in this clinical group was on an average 5.19 days (from 1 day to one month). The pa-

tients were distributed in the following way: less than 10 days before surgery – 23 (81.48%), from 10 to 20 days before surgery – 4 patients (14.82%) and more than 1 month before surgery – 1 patient (3.70%), (fig. 15).

Postoperative hospital stay in this clinical group was on an average 4 days (from 1 day to 36 days): to 10 days – 31 patients (86.11%), from 10 to 20 days – 4 patients (11.11%), from 20 days to 1 month – 1 patient (2.78%).

Clinical group III. Patients by the type of surgery were distributed in the following way: plate osteosynthesis – 116 patients (43.77%) from the general group.

The age in the group of patients after plate osteosynthesis averaged 41.76 ± 15.04 years. Patients aged from 18 to 30 years prevailed – 30 patients (25.86%). The following age groups were: 30-40 years – 28 patients (24.15%), 40-50 years – (21 patients (18.10%), and from 50 to 60 years – 21 patients (18.10%). The group of patients older than 60 included 16 individuals (13.79%), (fig. 16).

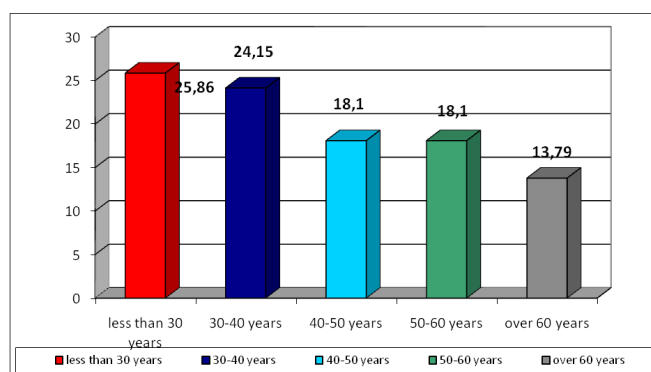


Fig. 16. Distribution of patients by age in the group of plate osteosynthesis, %.

There were 49 women (42.24%) and 67 men (57.76%).

In this clinical group there were 109 patients (93.97%) with closed fractures, and open ones – 7 (6.03%).

The following index of distribution of patients in this clinical group was the type of osteosynthesis performed. Osteosynthesis was performed on 116 patients including 2 patients with primary surgical treatment of the wound (1.72%), closed osteosynthesis – 86 patients (74.14%), open osteosynthesis – 28 patients (24.14%, fig. 17).

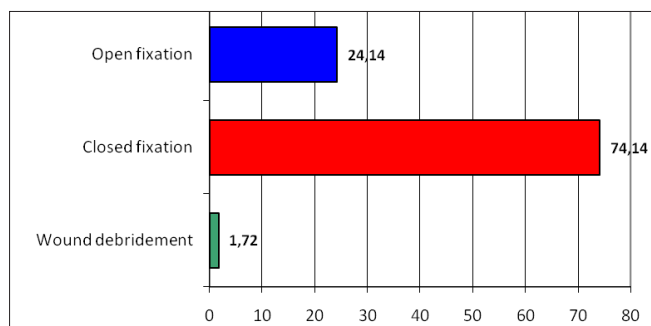


Fig. 17. Distribution of patients from the third clinical group by the type of osteosynthesis, %.

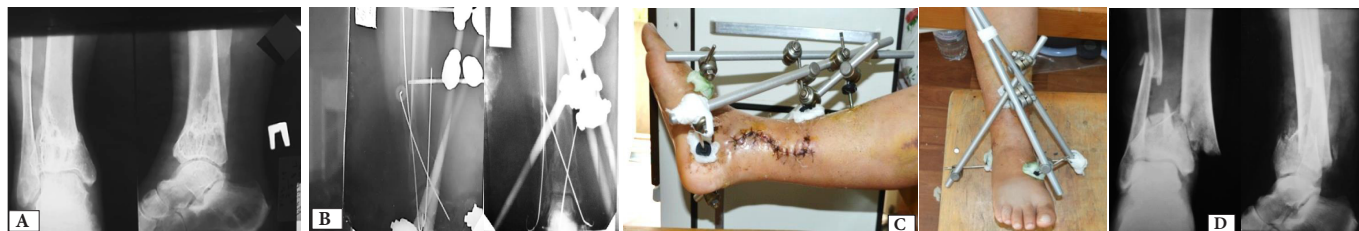

Fig. 18. X-ray and photo of the patient M. A – on the day of getting injury; B – after osteosynthesis with K-wires and pivotal device; C – external view of the limb in the device; D – remote result.

The types of injuries in this group of patients treated by means of surgery were distributed in the following way: off-the-job injury – 84 patients (72.41%), occupational injury – 9 patients (7.76%) and 21 patients after road accidents (18.10%), 1 case of sport injury and 1 of a hooligan attack (0.86% respectively).

Preoperative hospital stay was on an average 6.05 days (from 1 day to month). The patients were distributed appropriately: less than 10 days before surgery – 84 (72.41%), from 10 to 20 days before surgery – 26 patients (22.41%) and more than 20 days of preoperative period – 6 patients (5.17%).

Postoperative hospital stay in this clinical group was on an average 16.75 days (from 1 day to 2 months) – to 10 days – 29 patients (25.00%), from 10 to 20 days – 60 patients (51.72%), from 20 days to 1 month – 14 patients (12.07%) and more than one month – 13 patients (11.21%).

Overall hospital stay was on average 2.5 weeks (from 1.5 weeks to 2 months).

Results and discussion

Remote results were examined in 46 patients.

Clinical group I. Out of 26 patients of this group who were treated by means of mini-invasive osteosynthesis of fractures with K-wires, screws and external fixation or plaster bandage, 21 of them (80.76%) demonstrated good results, secondary dislocation of fragments occurred in 2 (7.69%) patients, and adduction-flexion contracture of the ankle joint occurred in 3 (11.54%) patients.

Clinical group II. Remote results were examined in 20 patients who underwent external fixation osteosynthesis. All of them had open fractures. Good results were found in 9 (45.0%) patients who completed their treatment in the external fixation device, their limb was supporting, volume of movements deficiency was less than 25%. In 7 patients the treatment with external fixation was the first stage of two-stage protocol. Their method of treatment was changed into mini-invasive osteosynthesis with plates. 2 (7.69%) patients developed complication of chronic osteomyelitis, and therefore sequesterectomy and arthrodesis of the ankle joint were performed. 2 (7.69%) patients developed stable adduction-flexion contracture of the ankle joint.

Example. Patient M., born in 1964, was admitted into the Traumatology Department for Adults on 25.08.2015 with the diagnosis: open spiral comminuted fracture of the

distal metaepiphysis of both bones of the right lower limb (tibia and fibula) with dislocation of 43-A3.2 fragments (fig. 18).

The patient was operated on: primary surgical treatment of the wound; osteosynthesis of the right lower limb with external fixation and Ilizarov's apparatus. Bandages were applied. Postoperative wound healed with primary intention. The results were controlled a year after the construction was removed. Positive good result was evidenced clinically and by X-ray.

Clinical group III. Remote results were examined in 26 patients after osteosynthesis with plates. The specific feature of this group was that osteosynthesis with plates was performed for patients with the best condition of the soft tissues, and blood supply of fragments respectively, compared with the patients from clinical group I and especially clinical group II.

In the days of empirical approach to traumatology as a science a well-known postulate existed saying that «the ankle joint does not like a great number of metallic grafts» (similar to that one «the elbow joint does not like thermal procedures»). This statement was added by the facts that the bone in the distal third of the lower limb is surrounded by the tendons, fasciae and skin, and due to this fact blood supply of the bone is not sufficient.

Having compared the remote results of mini-invasive and traditional open bone osteosynthesis, we were convinced in certain advantages of mini-invasive variant of surgical treatment that corresponds to the latest version of the AO principles.

A certain experience has been accumulated concerning indirect reposition of the majority of fractures under step-by-step X-ray control using a traction table, distractor, joysticks, percutaneous pricker, and sharp hook.

Similar manipulations in our clinic have been performed since 1994. While performing surgery more and more often a natural question arose: since fragments are repositioned, anatomical structure of the bone is restored, is open access reasonable in this case, if it produces additional disorders to the periosteal blood supply? (fig. 19).

Is it reasonable to insert from 4 to 6 screws into the distal epiphysis and 3-4 screws through the diaphysis additionally disturbing intraosseous blood supply? Isn't it possible to do without these manipulations harmful for blood supply? In search of an answer to these questions we have chosen the advanced technique of mini-invasive osteosynthesis apply-

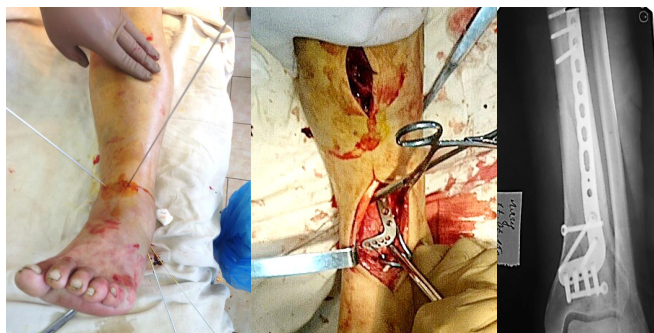


Fig. 19. Visual comparison of closed mini-invasive osteosynthesis and up-to-date osteosynthesis technique with anatomically adjacent plates.

ing K-wires 2 mm in diameter in combination with external fixation or plaster bandage. Immobilization of the limb to some extent produces a positive effect on healing damaged tissues in the place of fracture, and thus promotes restoration of blood supply to fragments. These methods are indispensable when the condition of the soft tissues in the place of fracture is poor, for example, scratches, phlyctena, exfoliation of the soft tissues, necrotic changes, infected wounds, etc. All these factors prevent from performing internal osteosynthesis. Application of mini-invasive methods of treatment of distal tibial fractures to some extent contradicts with the fourth AO principle concerning early function of the operated limb. And what about weight loading? It's not allowed in case of osteosynthesis with plates till consolidation occurs. Meanwhile it is allowed in case of external fixation. In general pathogenesis of fragments consolidation and the influence of such important factors as preservation of blood supply, functions, loading, stable fixation, immobilization of the limb and their interrelations are not completely studied and require considerable scientific investigation.

Economic issues of treatment for injured persons in Ukraine have become of a substantial value, since insurance medicine is not introduced yet, and grafting for patients is not financed from the state budget. Even without making calculations it is clear, that treatment in the first and second clinical groups costs much less than that in the third one. We are planning to determine economic efficacy indices of mini-invasive osteosynthesis. Sometimes a certain conflict arises in the existing system, since both providers of medical equipment and medical staff of hospitals are more interested in application of expensive implants for osteosynthesis than patients themselves.

The results of our study do not mean that we suggest changing the AO protocol concerning treatment of fractures of the distal tibia. All the improvements do not go beyond the scope of the approved AO technologies.

Conclusions

The analysis of implementation of the improved mini-invasive osteosynthesis technology for fractures of the distal

lower limb compared with the traditional methods of surgical treatment of these injuries in 265 patients from the three clinical groups demonstrated that the use of closed reposition and improved technique leads to improved results and considerable reduction of costs for treatment in comparison with traditional osteosynthesis.

References

1. Bets G, Stoiko I, Bets I. Predoperatsionnoe planirovanie i primeneniye malotraumachnoi khirurgicheskoi tekhniki pri perelomakh pilon [Preoperative planning and application of minimally traumatic surgical technique in pilon fractures]. *Ortop Travmatol Protez (Ukraine)*. 2013;(4):30-4. Russian.
2. Korzh NA, Romanenko KK, Goridova LD, et al. Perelomy kostei goleni na urovne distal'nogo epimetafiza (perelomy pilona) i ikh posledstviya, diagnostika i lechenie [Fractures of distal epimetaphysis of tibia (pilon fracture) and their consequences, diagnosis and treatment]. *Travma (Ukraine)*. 2011;12(2):47-54. Russian.
3. Loskutov O, Panchenko S, Krasovskii V. Biomekhanicheskoe obosnovanie nekotorykh variantov maloinvazivnogo osteosinteza pri nadsindesmoznykh perelomakh narujnoi lodyzhki [Biomechanical grounds for some variants of low-invasive osteosynthesis in suprasyndesmotric fractures of the lateral malleolus]. *Ortop Travmatol Protez (Ukraine)*. 2010;(3):64-71. Russian.
4. L'vov SE, Dzhavad Ali, Artem'ev AA, et al. Algoritm osteosinteza vnutrisustavnykh oskol'chatykh perelomov distal'nogo metaepifiza bol'shebertsovoi kosti [Algorithm of osteosynthesis of intraarticular comminuted fractures of distal tibial meta-epiphysis]. *Genii Ortop (Russia)*. 2011;(3):30-4. Russian.
5. Pobel AN, Trufanov II, Gatsak VS. Osobennosti perelomov pilon i vybor ratsional'noi metodiki lecheniia [Features of pilon fractures and the selection of a rational method of treatment]. *Travma (Ukraine)*. 2011;12(4):234-8. Russian.
6. Romanenko KK. Perelomy kostei goleni na urovne distal'nogo epimetafiza (perelomy pilona) i ikh posledstviya, diagnostika i lechenie [Fractures of distal epimetaphysis of tibia (pilon fracture) and their consequences, diagnosis and treatment]. *Ukr Med Alm*. 2011;14(2):155-8. Russian.
7. Calori GM, Tagliabuea L, Mazza E, et al. Tibial pilon fractures: Which method of treatment? *Injury*. 2010;41(11):1183-90.
8. Cannada LK. The no-touch approach for operative treatment of pilon fractures to minimize soft tissue complications. *Orthopedics*. 2010;33(10):734-8.
9. Gaulke R, Krettek C. Tibial pilon fractures: Avoidance and therapy of complications. *Unfallchirurg*. 2017 Aug;120(8):658-66.
10. Hong J, Zeng R, Lin D, et al. Posteromedial anatomical plate for the treatment of distal tibial fractures with anterior soft tissue injury. *Orthopedics*. 2011;34(6):161-69.
11. Meena UK, Bansal MC, Behera P, Upadhyay RJ, et al. Evaluation of functional outcome of pilon fractures managed with limited internal fixation and external fixation: A prospective clinical study. *J Clin Orthop Trauma*. 2017 Nov;8(Suppl 2):S16-S20.
12. Müller FJ, Nerlich M. Tibial pilon fractures. *Acta Chir Orthop Traumatol Cech*. 2010;77(4):266-76.
13. Sohn OJ, Kang DH. Staged protocol in treatment of open distal tibia fracture: using lateral MIPO. *Clin Orthop Surg*. 2011;3(1):69-76.
14. White TO, Guy P, Cooke CJ, et al. The results of early primary open reduction and internal fixation for treatment of OTA 43.C-type tibial pilon fractures: a cohort study. *J Orthop Trauma*. 2010;24(12):757-63.
15. Zhang ZD, Ye XY, Shang LY, et al. Case-control study on minimally invasive percutaneous locking compression plate internal fixation for the treatment of type II and III pilon fractures. *Zhongguo Gu Shang*. 2011;24(12):1010-12.