

R Mahdoufi\*, I Barhmi, N Tazi, R Sami,  
R Abada, M Roubal and M Mahtar

ENT-Neck and Face Surgery, Hospital August 20,  
1953, University Hospital IBN ROCHD, Casablanca,  
Morocco

**Dates:** Received: 24 June, 2016; Accepted: 01 July,  
2016; Published: 04 July, 2016

\*Corresponding author: R Mahdoufi, ENT-Neck and  
Face Surgery, Hospital August 20, 1953, University  
Hospital IBN ROCHD, Casablanca, App. H1, Résidence  
Mawlid IX, Rue Brahim Nakhaii, Maarif, Casablanca,  
Morocco, Tel: +212663466994; +212617173539;  
E-mail: mahdoufir@gmail.com

www.peertechz.com

ISSN: 2455-1759

**Keywords:** Larynx; Plexiforme; Neurofibroma; Child

## Case Report

# Plexiform Neurofibroma of the Larynx in Children: About an Unusual Case Report

### Abstract

**Introduction:** The plexiform neurofibroma is a rare benign tumor which is often associated to type 1 neurofibromatosis or Von Recklinghausen's disease. The laryngeal involvement in neurofibromatosis is extremely rare.

The objective of our report is the consideration of laryngeal neurofibromatosis in the differential diagnosis of dyspnea in infants and children.

**Summary of the clinical case:** We report the case of a 4 year-old child who presented with inspiratory dyspnea. Laryngoscopy revealed a mass obstructing completely the laryngeal vestibule. Pathological examination of the resected tissue revealed a plexiform neurofibroma after immunohistochemical examination. The patient had regular follow up and she remained symptom free.

**Discussion:** There is an association between neurofibromatosis type 1 and plexiform neurofibromas of the larynx. Analysis of the margins of neurofibromas of the larynx associated with neurofibromatosis type 1 may help predict clinical behavior.

## Abbreviations

NF: Neurofibroma; CT: Computed Tomography; MRI: Magnetic Resonance Imaging

## Introduction

The plexiform neurofibroma is a benign tumor of the peripheral nerves, made at the expense of the connective cells perineurium, often considered pathognomonic of neurofibromatosis type 1.

The patient can develop tumors of neural origin at any age and at any location. However, laryngeal involvement in neurofibromatosis remains rare, and is usually manifested by obstructive airway symptoms. Because its rarity and our inexperience, it is often misdiagnosed.

In this review we discuss the pertinent clinical findings of this rare lesion and review the literature relative to laryngeal neurofibroma.

## Case Report

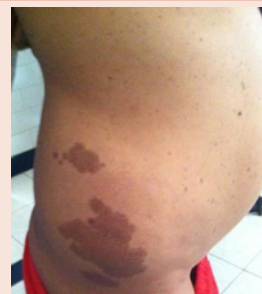A 4 year-old-girl was admitted to our department with obstructive respiratory symptoms. She had a history of laryngeal stridor since birth, more intense during physical activity and screams, associated with progressive dyspnea and nocturnal snoring; there was no history of previous intubation or foreign body ingestion.

The physical exam showed a substernal draw with flaring nose. And found many café-au-lait spots over the trunk and limbs [Figure 1](#).

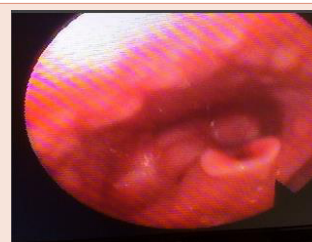Fiberoptic laryngoscopy revealed a mass obstructing the laryngeal vestibule. A tracheotomy was indicated to improve respiratory function [Figure 2](#).

The CT scan showed a mass hypodense endolaryngeal behind the epiglottis. The laryngeal cartilages are individualized [Figure 3](#).

Modified supraglottic laryngectomy, included the resection of epiglottis, aryepiglottic folds and incomplete false vocal folds resection was indicated because the tumor infiltrating the larynx was



**Figure 1:** multiple cafe-au-lait spots over the trunk and limbs.



**Figure 2:** mass at the laryngeal surface of the epiglottis.

large. Nevertheless a partial approach was decided for two reasons: young age of a patient and because the tumor was benign **Figure 4**.

Immediate postoperative course was uneventful.

Histopathological examination with immuno-histochemical exam showed a plexiform neurofibroma.

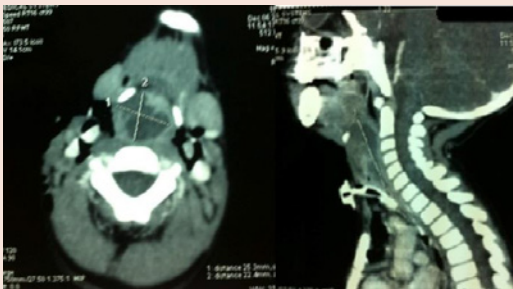The evolution was marked by the improvement of respiratory signs.

The patient was asymptomatic for almost 4 years and had not yet received another surgical intervention.

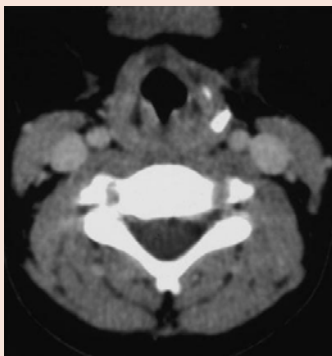
## Discussion

Neurogenic laryngeal tumor is rare. Neurofibromas are not encapsulated and are often associated with NF-1. Still, they can occur sporadically. Laryngeal involvement of neurofibroma in NF-1 is uncommon.

Up to 1996 there were only 35 cases reported, of which 19 were in pediatric patients [1]. The clinical symptoms of the disease are those usually associated with a slow growing lesion of the larynx: the patient gradually develops hoarseness, globus sensation, dysphagia, inspiratory dyspnea on exertion, sometimes biphasic stridor [2,3]. Some patients complain about dyspnea in the supine position which seems to be associated with the location of the lesion [3,4].



**Figure 3:** Axial CT with coronal view scan shows a 20 × 30 × 25 mm mass, large hypodense mass slightly less dense than the muscle, obliterating the laryngeal vestibule and invading the larynx.



**Figure 4:** Contrast-enhanced axial CT scan at 4-year postsurgical follow-up shows a small of residual disease.

Most laryngeal lesions would produce stridor during the inspiratory phase. The first diagnosis would be laryngomalacia [5]. Other common etiologies in pediatric respiratory distress include vocal paralysis, subglottic stenosis, and vascular anomaly. When swallowing difficulty is encountered, supraglottic tumor should also be considered [6].

The diagnostic workup should include indirect and fiberoptic laryngoscopy, computed tomography (CT) and magnetic resonance imaging (MRI) aid the differential diagnosis possible. Definitive diagnosis can only be made histologically [7].

Surgery is the choice of treatment and depends on the location and the size of the tumor. Most authors favor external approaches with alternative airway provisions such as a preliminary tracheotomy in larger tumors. Median or lateral thyrotomy or median or lateral pharyngotomy are recommended [1,8-12]. In smaller tumors, endoscopic (laser-assisted) resection of the tumor can be a reasonable treatment option [1,13].

Due to the relative big sized tumor of our case, external approach would guarantee a wider exposure [2,5,7]. Surgical morbidity includes hemorrhage, scarring with or without laryngeal stenosis, vocal paralysis, and postoperative pulmonary edema [7]. Nevertheless, long-term follow up is necessary and a second operation will be necessary if the symptoms recurred again.

## Conclusion

The association between laryngeal plexiform neurofibroma in children and neurofibromatosis is very rare, revealed by respiratory signs such as dyspnea and stridor. The imaging including CT and / or MRI is a valuable aid to the diagnosis and assessment of extension of the lesion. The treatment is based on a conservative cervical surgery or endoscopy.

## Consent to publish

Written informed consent was obtained from the parent of the patient for publication of this case report and accompanying image.

## References

- Weiss SW, Goldblum JR (2008) editors. Enzinger and Weiss's soft tissue tumors. 5th ed, Elsevier 827-828.
- Friedman J, Birch P (1997) Type 1 neurofibromatosis: a descriptive analysis of the disorder in 1,728 patients. *Am J Med Genet* 70: 138-143.
- Huson SM, Harper PS, Compston DA (1988) Von Recklinghausen neurofibromatosis. A clinical and population study in south-east Wales. *Brain* 111: 1355-1381.
- Lin VY, Daniel SJ, Papsin BC (2004) Button batteries in the ear, nose and upper aerodigestive tract. *Int J Pediatr Otorhinolaryngol* 68: 473-479.
- Pinson S, Wolkenstein P (2005) [Neurofibromatosis type 1 or Von Recklinghausen's disease]. *Rev Med Interne* 26: 196-215.
- Heuze Y, Piot B, Mercier J (2002) [Difficult surgical management of facial neurofibromatosis type I or von Recklinghausen disease in children]. *Rev Stomatol Chir Maxillofac* 103: 105-113.
- Chang-Lo M (1977) Laryngeal involvement in Von Recklinghausen's disease: a case report and review of the literature. *Laryngoscope* 87: 435-442.
- Meric F, Arslan A, Cüreoglu S, Nazaroğlu H (2000) Schwannoma of the larynx: case report. *Eur Arch Otorhinolaryngol* 257: 555-557.



9. Ho WK, Lo SD, Ng RW (2005) Schwannoma of the larynx. *Ear Nose Throat J* 84: 554-555.
10. Lo S, Ho WK (2004) Schwannoma of the larynx-an uncommon cause of vocal cord immobility. *Hong Kong Med J* 10: 131-133.
11. Elias MM, Balm AJ, Peterse JL, Keus RB, Hilgers FJ (1993) Malignant schwannoma of the parapharyngeal space in von Recklinghausen's disease: a case report and review of the literature. *J Laryngol Otol* 107: 848-852.
12. Syeda F, Hussain A (2005) Schwannoma of the larynx: a case report. *Ear Nose Throat J* 84: 732-734.
13. Cihangiroglu M, Yilmaz S, Topsakal C, Gok U, Altinsoy B, et al. (2002) Laryngeal neurofibroma associated with neurofibromatosis type 2. *AJNR Am J Neuroradiol* 23: 1637-1369.
14. Peltonen J, Jaakkola S, Lebwohl M, Renvall S, Risteli L, et al. (1988) Cellular differentiation and expression of matrix genes in type 1 neurofibromatosis. *Lab Invest* 59: 760-771.
15. Masip MJ, Esteban E, Alberto C, Menor F, Cortina H (1996) Laryngeal involvement in pediatric neurofibromatosis: a case report and review of the literature. *Pediatr Radiol* 26: 488-492.

**Copyright:** © 2016 Mahdoufi R, et al. This is an open-access article distributed under the terms of the Creative Commons Attribution License, which permits unrestricted use, distribution, and reproduction in any medium, provided the original author and source are credited.

**Citation:** Mahdoufi R, Barhmi I, Tazi N, Sami R, Abada R, et al. (2016) Plexiform Neurofibroma of the Larynx in Children: About an Unusual Case Report. *Arch Otolaryngol Rhinol* 2(2): 035-037. DOI: 10.17352/2455-1759.000020