

Tirotta Daniela* and Durante Vittorio

Internal Medicine, Cervesi Hospital, Cattolica (AUSL Romagna), Italy

Dates: Received: 30 April, 2016; Accepted: 24 June, 2016; Published: 25 June, 2016

***Corresponding author:** Daniela Tirotta, Medicina Interna, ospedale Cervesi di Cattolica (AUSL Romagna), Via Beethoven 1, 47841, Cattolica (AUSL Romagna), Italy, Tel: 0541/966291; Fax: 0541966290; E-mail: danitrotta@libero.it

www.peertechz.com

ISSN: 2455-2283

Keywords: Gastrointestinal AL amyloidosis; Enteropathy protein-losing; Malabsorption

Case Report

Gastrointestinal Amyloidosis: An Unusual Case Where Protein-Losing Enteropathy is Associated to Malabsorption

Abstract

Introduction: The systemic amyloidosis usually doesn't save the digestive tract, but this involvement is present in approximately 60% of patients with AA Amyloidosis and only in 8% and 1% of patients with AL Amyloidosis (respectively through biopsy and clinically). Beside gastrointestinal involvement is rarely symptomatic and clinical events are not specific.

Enteropathy protein-losing is a rare condition caused by excessive loss of serum protein in the gastrointestinal tract, resulting in hypoproteinaemia, edema, and, sometimes, pleural/pericardial effusions. The diagnosis should be taken into account only when other causes have been excluded.

Gastrointestinal AL amyloidosis usually appears with constipation and mechanical obstruction/pseudobstruction, on the contrary enteropathy protein-losing and malabsorption are rare.

Case report: We report the case of a 59-year -old patient, with AL amyloidosis, who suffered from weight loss and ascites effusion related to an AL amyloidosis.

Discussion: The case is unusual, both because of the extension in the gastrointestinal tract and for its unusual clinical presentation as enteropathy protein-losing associated with malabsorption.

Introduction

The systemic amyloidosis usually doesn't save the digestive tract, but this involvement is present in approximately 60% of patients with AA Amyloidosis and only in 8% and 1% of patients with AL Amyloidosis (diagnosis respectively made through biopsy and clinically) [1]. Beside gastrointestinal involvement is rarely symptomatic and clinical events are not specific [2].

Enteropathy protein-losing is a rare condition caused by excessive loss of serum protein in the gastrointestinal tract, resulting in hypoproteinaemia, edema, and, sometimes, pleural/pericardial effusions. The diagnosis should be taken into account only when other causes have been excluded (malnutrition, heavy proteinuria, and reduced protein synthesis due to liver diseases).

Gastrointestinal AL amyloidosis usually appears with constipation and mechanical obstruction/pseudobstruction, on the contrary enteropathy protein-losing and malabsorption are rare [1,2].

Case Presentation

A 59 years old man was admitted for loss weight, taste perversion, diarrhea. Medical history:

A month earlier, due to an exertional dyspnea, he carried out an ECG (right ventricular hypertrophy and previous anterior septal ischemia)

He carried out an echocardiogram, positive for mild cardiac hypertrophy (apical prevalence), left atrial enlargement, and small pericardial effusion.

The Diagnosis. Physical examination showed basal pulmonary obtusity, abdomen US confirmed ascites and pleural effusion. Macroglossia was absent.

Blood tests showed low cholesterol levels (122 mg/dl total, 79 mg/dl LDL, 29 mg/dl HDL, 70 mg/dl), hypoproteinemia (54 g/l protein, 64.1% albumin); hypogammaglobulinemia (9.6% gamma-globulins).

Thoracoabdominal computed tomography confirmed modest ascites and lung interstitium thickening.

Because of gastrointestinal symptoms, ascites, hypoproteinemia and low cholesterol levels (in absence of malnutrition, proteinuria, and liver disease), we assumed the hypothesis of enteropathy protein-losing. The cardiopathy and the hypogammaglobulinemia encouraged us to think about lymphoproliferative disease.

Therefore, we planned an esophagogastroduodenoscopy and a colonoscopy, with evidence of widespread gastrointestinal amyloidosis.

In particular endoscopy showed erythematous striate in the gastric antrum, wall thickening, erythema and erosions in the second portion of the duodenum, extensive scarring of the whole circumference in the proximal transverse.

Histological examination showed the homogeneous eosinophilic material in duodenal and gastric withdrawals, in the vascular and in the lamina propria, with epithelial erosions, finally deposits in the vessel wall of submucosa of large intestine. No evidence of lymphoma. Positive staining with Congo red.

Blood tests revealed mild proteinuria (0.19 g/24 hours), urine Bence Jones positive, peripheral CD4/CD8 ratio inversion. Blood tests also showed high pro-BNP (4829 ng/l) and positive troponin on two points (63 ng/l). LDH and serum urea were normal.

Therefore it was planned a bone marrow biopsy, positive for monotypic kappa myeloma, first pathological stage associated to monotypicity for the light chain kappa immunoglobulin.

In the context of vascular walls there is a deposition of amorphous homogeneous substance and positive PAS: compatible with amyloid (Congo red staining positive) (Figures 1,2).

Cardiac MRI confirmed typical altered kinetics of gadolinium. *Abdominal fat aspiration* was positive for amyloidosis.

Due to the presence of an unusual manifestation of an unusual disease, the patient was sent to the Centre of reference for amyloidosis.

Discussion

Gastrointestinal tract involvement is almost constant in patients with systemic amyloidosis (70-100% of patients), but a significant number is asymptomatic [1-4]. Only 30-60% develop digestive symptoms [5,6], therefore the diagnosis of digestive amyloidosis is often difficult. In our case, in fact, it was made quite late.

Symptoms, if present, are aspecific:

- diarrhea and malabsorption (due to rapid intestinal transit) usually in AA amyloidosis, while obstruction/pseudo-

obstruction (due to dysmotility) in AL amyloidosis (39-50%) [1,2].

- bleeding (25-45 % of patients) due to ischemia, infarction, vascular friability, mucosal lesions
- malabsorption (due to mucosal infiltration, pancreatic insufficiency, bacterial overgrowth), loss weight, diarrhea, steatorrhea
- Protein losing gastroenteropathy: diarrhea, ascites, edema, pleural/pericardial effusion, evidence of hypoalbuminemia
- Macroglossia (25%)

Our case is characterized by rare clinical manifestation for AL amyloidosis: a combination of enteropathy protein-losing and malabsorption.

Enteropathy protein-losing is related to an increased capillary permeability to plasma proteins, to exudation through an inflamed mucosa and, also, to the functional disruption of the lymphatic flow in the bowel and mesenterium [7].

Gastrointestinal amyloidosis may be localized or widespread [4]. The most common sites of amyloid deposits are the veins and arteries of the submucosa and muscularis propria. Also lymphatic vessels of submucosal and subserosal are involved, as well as the muscularis mucosae and, finally, mucosal or neuromuscular infiltration or extrinsic autonomic neuropathy [1].

In AL amyloidosis polypoid protrusion, the thickening of the valvulae conniventes are more common

In AA amyloidosis erosions, mucosal friability and granular appearance are prevalent

In our case the macroscopic aspect is not usual and is more typical for AA amyloidosis.

In gastrointestinal amyloidosis endoscopic signs are various and non-specific [4], 3/4 of endoscopic examination are normal [4]. Possible endoscopic aspects are: grainy appearance of the mucosa, hematoma, submucosal polyps, thickening of mucosa, superficial erosions or ulcerations; villous atrophy (rare).

Digestive amyloidosis has poor prognosis (specially for bleeding complications and malnutrition). The median survival is 12 months [4]. In the diffuse forms, the treatment is poorly codified [4].

Our case is emblematic for gastrointestinal amyloidosis: clinical symptoms can be long silent; the endoscopic appearance is varied and non-specific, therefore clinician should think about the gastrointestinal histological examination.

The widespread involvement of the gastroenteric tract, the enteropathy protein-losing are unusual for AL amyloidosis, but due to the poor prognosis, it is necessary for the clinician to think earlier about this diagnosis.

Acknowledgements

To Giovanna Fabbretti, Anatomia Patologica of Rimini Hospital (AUSL Romagna).

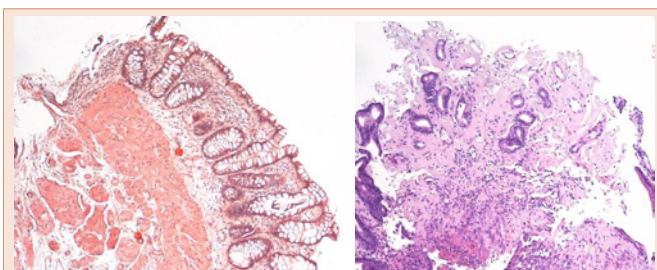


Figure 1: Gastric histological examination: homogeneous eosinophilic material, attributable to amyloid perivascular and in the lamina propria, with epithelial erosions. Positive staining with Congo red in the polarized light.

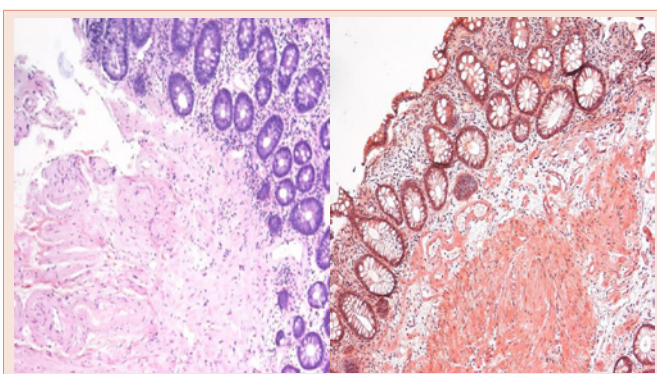


Figure 2: Intestinal histological examination: homogeneous eosinophilic material, attributable to amyloid in the vessel wall of submucosa. Positive staining with Congo red in the polarized light.



References

1. Camilleri M, Friedman LS, Grover S (2015) Gastrointestinal amyloidosis: Clinical manifestations, diagnosis and management.
2. Pavic M, Camus C, Pasquet F, Karkowski L, Galoo E, et al. (2011) [Seriousness of AL amyloidosis of the digestive system]. *Rev Med Interne* 32: e52- e54.
3. Milovic V, Grand RJ, Lamont JT (2013) Protein-losing gastroenteropathy. *Up To Date*.
4. Béchade D, Carmoi T, Algayres JP (2008) Amylose digestive (foie exclu). EMC (Elsevier Masson SAS, Paris), Gastroentérologie 9-089-C-15.
5. James DG, Zuckerman GR, Sayuk GS, Wang HL, Prakash C (2007) Clinical recognition of AL type amyloidosis of the luminal gastrointestinal tract. *Clin Gastroenterol Hepatol* 5: 582–588.
6. Repiso A, Valle J, Rodriguez-Merlo R, Munoz-Rosas C, Bolano F, et al. (2003) Gastrointestinal bleeding and small bowel amyloidosis. *Rev Esp Enferm Dig* 95: 578–580.
7. Kawaguchi M1, Koizumi F, Shimao M, Hirose S (1993) Protein-losing enteropathy due to secondary amyloidosis of the gastrointestinal tract. *Acta Pathol Jpn* 43: 333-339.

Copyright: © 2016 Daniela T, et al. This is an open-access article distributed under the terms of the Creative Commons Attribution License, which permits unrestricted use, distribution, and reproduction in any medium, provided the original author and source are credited.

Citation: Daniela T, Vittorio D (2016) Gastrointestinal Amyloidosis: An Unusual Case Where Protein-Losing Enteropathy is Associated to Malabsorption. *Arch Clin Gastroenterol* 2(2): 050-052. DOI: 10.17352/2455-2283.000020