



ISSN NO. 2320-5407

Journal Homepage: -www.journalijar.com

INTERNATIONAL JOURNAL OF ADVANCED RESEARCH (IJAR)

Article DOI:10.21474/IJAR01/7399
DOI URL: <http://dx.doi.org/10.21474/IJAR01/7399>



INTERNATIONAL JOURNAL OF
ADVANCED RESEARCH (IJAR)
ISSN 2320-5407
Journal Homepage: <http://www.journalijar.com>
Journal DOI:10.21474/IJAR01

RESEARCH ARTICLE

MANAGEMENT OF PULSELESS HAND IN CHILDREN FOLLOWING CLOSED SUPRACONDYLAR FRACTURE HUMERUS - BEFORE FRACTURE REDUCTION A CASE SERIES.

Dr. M. Krishna MS MCh¹, Dr. Jayanth. V. Kumar MS MCh¹, Prof. N. Sritharan MS MCh¹, Dr. I. Devarajan MS, MCh² and Dr. K. Raja Dip. N. B¹.

1. Assistant Professor, Institute of vascular surgery, MMC, RGGGH, Chennai - 03.
2. Senior resident , Institute of vascular surgery, MMC, RGGGH, Chennai - 03.

Manuscript Info

Manuscript History

Received: 12 May 2018
Final Accepted: 14 June 2018
Published: July 2018

Keywords:-

Supracondylar humeral fractures, pulseless hand, spasm of artery, entrapment of artery, Brachial artery.

Abstract

Closed supracondylar humerus fracture in children with pulseless hand though appear to have vascularity even after skeletal stabilisation may need surgical exploration for addressing vascular injury which is often accomplished by thrombectomy , primary repair or interposition graft repair. Between August 2017 and June 2018, 15 children presented with displaced closed supracondylar fracture of the humerus , 10 of them presented with absent radial and ulnar pulses treated either before or after fracture reduction based on the clinical examination findings and hand doppler assessment . Amongst these, seven patients were explored for vascular compromise even after fracture reduction and ended up in revascularisation by thrombectomy or interposition graft repair . Three patients were explored before fracture reduction , one was found to have entrapment of the brachial artery between the fracture fragments and two of them were found to have spasm of the brachial artery by the tractional force from the displaced fracture. surgical exploration before fracture reduction in all these three patients ended up in release of the brachial artery from the tractional force or from entrapped fracture fragment, resulted in distal pulse restoration and thereby avoided thrombectomy or graft repair in the growing children. children presenting with closed supracondylar humerus fracture with absent distal pulses with warm hand need high index of suspicion for exploration before fracture reduction to avoid fracture reduction manipulation associated vascular injury and thereby avoid thrombectomy and graft repair in the growing children.

Copy Right, IJAR, 2018., All rights reserved.

Introduction:-

Supracondylar fracture of the humerus in children follows fall from height or while at play with an outstretched arm and this constitutes 17 % of all fractures in children (a). This type of fracture accounts for 55–80% of all fractures around the elbow joint and mostly occurs in children around 7 years of age (b). Acute vascular injury may be present in approximately 10% of children with supracondylar humeral fractures (c). Brachial artery lesion may be secondary to various insults, such as entrapment, division, spasm of the vessel, the presence of an intimal tear or thrombus formation. The indications for exploration of the Elbow in children with pulseless, cold hand are clear, but the management of patients with a pulseless, well perfused hand is still a debate whether to proceed after or before

Corresponding Author:-Dr.Jayanth.V.Kumar.

Address:-Assistant Professor, Institute of vascular surgery, MMC, RGGGH, Chennai - 03.

fracture reduction . High index of clinical suspiciousness based on clinical examination coupled with hand doppler assessment can avoid thrombectomy and graft repair .

Aim and objectives:-

The aim of this study is to have high index of suspiciousness and low threshold for cubital fossa exploration before fracture reduction in children presenting with Closed supracondylar humerus fracture with absent radial and ulnar pulses with thumpish flow but still with warm hand so as to avoid vascular injuries associated with fracture manipulation and surgical procedures like thrombectomy, primary artery repair and interposition graft repair in growing children.

Type of study:-

Prospective study

Study duration:-

August 2017 to june 2018

Sample size:-15

Material AndMethods:-

15 children who presented with supracondylar humerus fracture with absent radial and ulnar pulses were included in the study. clinical examination and hand doppler assessment was made for radial and ulnar flow and pressure measurement were taken on both limbs, and a search was made for thumpish flow at and just above the fracture site was done. Age of these patients were between 4 yrs and 12yrs. Of these, 11 were male and 4 were female children The study was conducted at the Institute of vascular surgery, Rajiv Gandhi Government General Hospital , Chennai.

In these, seven children were subjected for cubital fossa exploration in view of non return of distal pulses after fracture reduction and 3 children were subjected for cubital fossa explortion before fracture reduction in view of absent forearm pulses associated with thumpish flow on hand doppler assessment at or just above the fracture site.

Baseline characters

Male	11(73.3%)
Female	4(26.7%)
No forearm pulse after fracture reduction	7(46.67%)
No forearm pulse after fracture reduction – Male	6(85.71%)
No forearm pulse after fracture reduction - Female	1(14.29%)
Restoration of forearm pulse after fracture reduction	5(41.67%)
Thrombectomy after fracture reduction- Male	2(33.33%)
Thrombectomy after fracture reduction- Female	1(100%)
Vein graft repair - Male	4(66.67%)
Vein graft repair - Female	0(0)
Brachial artery entrapment - before fracture reduction	1(33.33%)
Tractional force on Brachial artery before fracture reduction	2(66.67%)

Operative Technique Details:-

under general anesthesia, under sterile precautions the patient was placed close to the edge of the operating table with countertraction around the chest. With the shoulder at 90° abduction, constant traction was applied on the wrist followed by maximum flexion of the elbow. Once adequate closed reduction was obtained, percutaneous fixation with two Kirschner wires (K-wires) was done in the position of full reduction. However, if the hand remained pulseless, surgical exploration was the treatment of choice. In the absence of forearm pulses ,cubital fossa exposed through "lazy s" incision (Fig 1). Brachial artery control taken proximally and distally away from fracture site followed by exploration of brachial artery at the fracture site and a search was made for injury of artery , entrapment ,contusion thrombosis or spasm of artery (Fig 2).

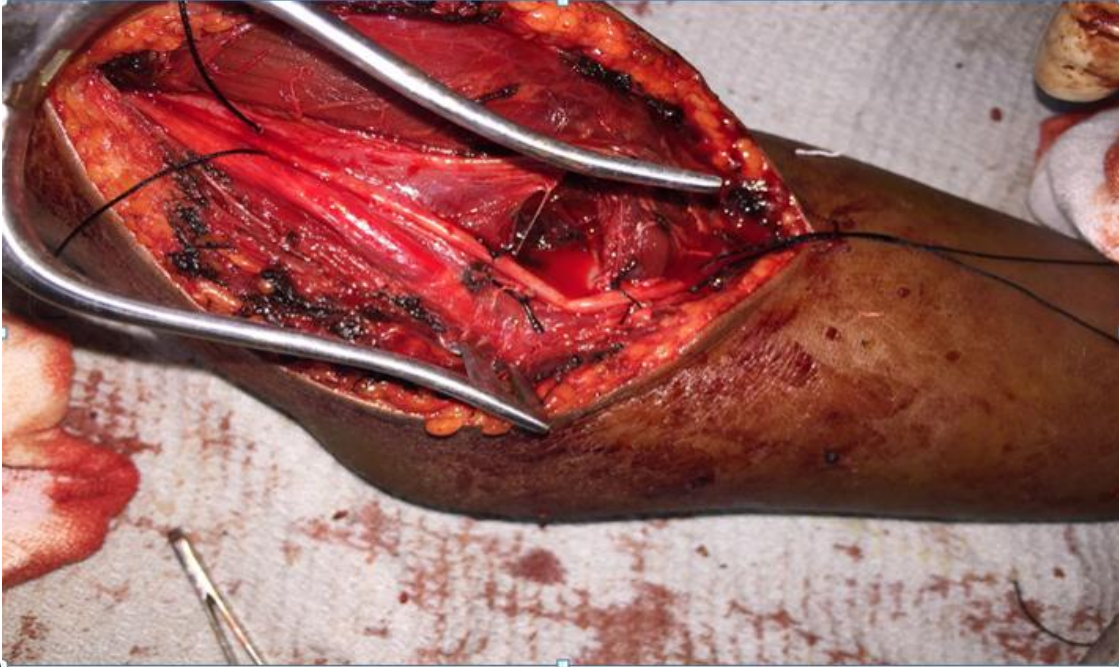


Fig 1:-Showing exposure of Brachial artery, proximal and distal control on artery and tractional force on the artery by fracture supracondylar humerus causing spasm.

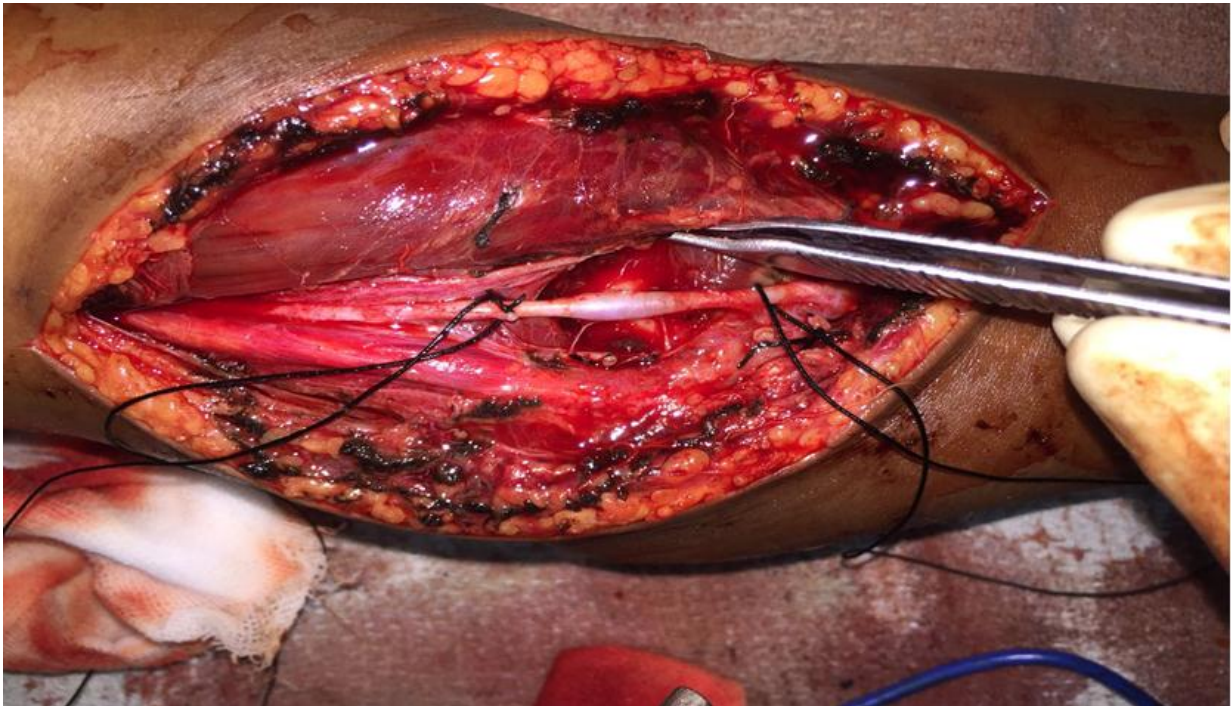
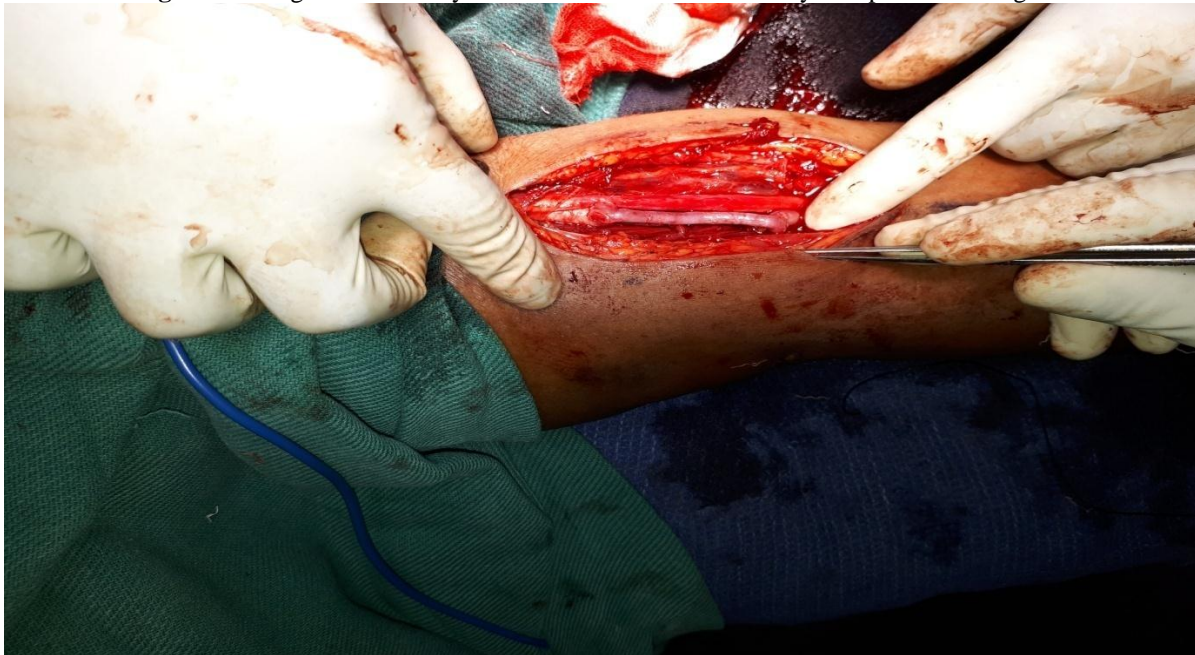

Fig 2:-Showing release of brachial artery from the tractional force of fracture site restored normal brachial pulse.

Fig 3:-Showing brachial artery contusion thrombosis treated by interposition vein graft



After restoration of forearm pulses, the elbow was immobilised with a plaster cast from the hand to just below the shoulder for 4 weeks. In all cases, continuous evaluation of the neurovascular status of the hand was required after the surgery. Four weeks postoperatively, the cast and the K-wires were removed and the rehabilitation programme was started.

Result:-

In this prospective study done at Institute of Vascular Surgery, Rajiv Gandhi Government General Hospital Chennai, during the period August 2017 to June 2018, we had totally 15 cases of Closed supracondylar fracture humerus in the age group of 4yrs to 12 yrs. This includes 11 (73.3%) male children and 4 (26.7%) female children. Amongst the 11 male children, 3(27.27%) of them developed normal forearm pulse after fracture reduction and 6(54.4%) of them were explored for absence of pulse after fracture reduction. In the latter group, 2(33.33%) of them were found to have spasm of the artery on exploration treated by thrombectomy, 3(50%) children were found to have contusion thrombosis and 1(16.6%) was found to have incomplete tear of brachial artery, these vessels were treated by interposition vein graft (Fig 3). Amongst the 4 female children, 2(50%) were restored with normal pulse after fracture reduction, one (25%) child was explored for absent pulse after fracture reduction and she was found to have spasm of the artery managed by thrombectomy. Three children(2 male and 1 female)(20%) were explored of cubital fossa before fracture reduction in view of absent forearm pulses and thumpish flow at or just above the fracture site. In the latter group, 1 (33.33%) male child was found to have entrapment of artery between the fracture fragments managed by release of artery from entrapment site, two children(1 male and 1 female)(66.67%) were found to have spasm of the artery by tractional force from fracture fragment, managed by release of artery with forearm pulse restoration, thereby avoided need for thrombectomy or graft repair in these children. Post operatively these children were managed with heparin (100units/kg body wt /6th hrly) for 48hrs followed by low dose antiplatelet for 4 weeks. These children were followed up by clinical examination and hand doppler assessment for 3days, after 10days and 4 weeks. None of them had vascular compromise in both groups(cubital fossa exploration before and after fracture reduction) and no wound complications noted.

Discussion:-

Closed Supracondylar fracture of the humerus in children is a surgical emergency, especially when associated with vascular compromise. Surgical exploration of the cubital fossa is mandatory in patients with absent forearm pulses and a cold hand (d,e). However, a delay to determine the nature and the extension of the vascular injury with time-consuming imaging studies is probably unnecessary(f). Though we have available evidence for exploration of cubital fossa in the absence of forearm pulses after fracture reduction (f), we do not have literatures on exploration

of cubital fossa before fracture reduction in the absence of forearm pulses. It has been demonstrated that there is no correlation between the signs of ischaemia and the type of vascular injury. Because one of the most reliable clinical signs of vascular injury is an absent pulse (g,h), patients with the absence of a palpable radial and ulnar pulses, regardless of the lack of other signs of ischaemia, should also be considered as candidates for surgical management and should be treated without delay as an emergency. In children with closed supracondylar fractures and pulseless yet pink hand, an urgent reduction of the fracture should be attempted, followed by stabilisation with K-wires. If the pulse does not return and the hand remains pulseless after fracture reduction, exploration of the injured vessel should follow, regardless of the presence of a pink, warm hand with a good capillary refill. At this point, it should be mentioned that a well perfused pulseless hand may be complicated by severe ischaemia during reduction manoeuvres or due to inadequate reduction of the fracture (i).

According to the literature, however, several options have been proposed for the treatment of a pulseless but otherwise well perfused hand. Observation is recommended by some authors (d, j,k.) If the hand remains pulseless but well perfused after stabilisation, they suggest that the vascular injury should not be treated and instead rely on collateral circulation. Absence of the forearm pulses after 24 hr observation indicates that the brachial artery is unlikely to recover patency. The rich collateral circulation around the elbow is sufficient for the viability of the forearm. However, the possibility of limb length discrepancy (k,l) effort intolerance (m,l), cold intolerance (n) and thrombus migration (o) should be considered if non operative method of treatment is selected. Moreover, there are no series available with long follow-up and a significant number of cases to support the superiority of a treatment option that finally leads to an fore arm that relies only on collateral circulation. Finally, an arm without an original dominant brachial artery may probably be too inefficient to handle a future trauma complicated with an arm-threatening vascular injury or be a donor or recipient of surgical flaps.

The use of these radiographic procedures in the estimation of the vascular status in children with a pulseless but otherwise well perfused hand raises questions and controversy. Sabharwal et al. (k) supported the view that the combination of segmental pressure monitoring, colour-flow duplex ultrasound and magnetic resonance angiography are sufficient evaluation tools for the patency of the brachial artery. On the contrary, some believe that these techniques do not have the specificity and sensitivity of angiography (p). The latter is sufficient to define the extension and localisation of the vascular injury and provide the necessary information for the surgical plan (q). Copley et al. (g) reported that a formal angiography should be performed before surgery if either the pulseless limb has no clinical signs of severe ischaemia and the essence or location of the vascular injury remains unknown due to previous vascular pathology or combined limb trauma, or when a surgical exploration is being debated. In our study we did not do imaging for vascular injury assessment except for hand doppler assessment considering the time factor to avoid delay and difficulties in subjecting these children for angiography or CT/MR imaging.

In a recent study, Luria et al. (q) analysed the vascular complications of 24 children with supracondylar fractures of the humerus. In their series, reduction of the fracture was followed by a return of the pulse in 58% of the cases. They concluded that, rest of the cases in which the forearm pulses were not returned after reduction of the fracture, exploration of the cubital fossa was indicated. Angiography may not be sufficient to distinguish arterial spasm from an intimal tear which necessitates surgical intervention.

In this study we made on closed supracondylar fracture humerus in 15 children under 12yrs of age, three children were explored before fracture reduction in the absence of forearm pulses with warm hand based on clinical examination and hand doppler assessment. All these children were demonstrated with thumpish flow either at the level of fracture site or just above it. On exploration spasm of the brachial artery secondary to tractional force by impingement of fracture fragment noted in two children and entrapment of the artery between fracture fragments in one child noted. All of them were managed by simple release of the artery from impinging tractional force or from entrapped fracture fragment without thrombectomy or graft repair(k) thereby avoids the risk of reocclusion and stenosis that might follow repair procedures. Post operative follow up of these patients revealed normal pulse in the radial and ulnar arteries. No wound complications noted in the follow up period.

Conclusion:-

Closed supracondylar fracture humerus in children is a surgical emergency in view of associated vascular injury. The absence of forearm pulses should not always be attributable to spontaneously resolvable vascular spasm. A high index of suspicion with low threshold for cubital fossa exploration in the absence of forearm pulses even in warm hand should be considered before fracture reduction in the presence thumpish flow at or just above the

fracture site. This can avoid iatrogenic vascular injury risk associated with fracture manipulation, incomplete reduction, thereby avoids thrombectomy and graft repair(k) in growing children.

Disclosure Statement:-

No conflict of interest.

References:-

1. Cheng JC, Ng BK, Ying SY, Lam PK. A 10-year study of the changes in the pattern and treatment of 6,493 fractures. *J PediatrOrthop.* 1999;19:344–350. doi: 10.1097/00004694-199905000-00011.
2. Landin L, Danielsson L. Elbow fractures in children. An epidemiological analysis of 589 cases. *ActaOrthop Scand.* 1986;57:309–312.
3. Schoenecker PL, Delgado E, Rotman M, Sicard GA, Capelli AM. Pulseless arm in association with totally displaced supracondylar fracture. *J Orthop Trauma.* 1996;10:410–415. doi: 10.1097/00005131-199608000-00008.
4. Garbuz DS, Leitch K, Wright LG. The treatment of supracondylar fractures in children with an absent radial pulse. *J PediatrOrthop.* 1996;16:594–596.
5. Gosens T, Bongers KJ. Neurovascular complications and functional outcome in displaced supracondylar fractures of the humerus in children. *Injury.* 2003;34:267–273. doi: 10.1016/S0020-1383(02)00312-1.
6. Clement DA. Assessment of a treatment plan for managing acute vascular complications associated with supracondylar fractures of the humerus in children. *J PediatrOrthop.* 1990;10:97–100
7. Copley LA, Dormans JP, Davidson RS. Vascular injuries and their sequelae in pediatric supracondylar humeral fractures: toward a goal of prevention. *J PediatrOrthop.* 1996;16:99–103.
8. Endean ED, Veldenz HC, Schwarcz TH, Hyde GL. Recognition of arterial injury in elbow dislocation. *J Vasc Surg.* 1992;16:402–406. doi: 10.1067/mva.1992.37881.
9. Louahem DM, Nebunescu A, Canavese F, Dimeglio A. Neurovascular complications and severe displacement in supracondylar humerus fractures in children: defensive or offensive strategy? *J PediatrOrthop B.* 2006;15:51–57.
10. Malviya A, Simmons D, Vallamshetla R, Bache CE. Pink pulseless hand following supra-condylar fractures: an audit of British practice. *J PediatrOrthop B.* 2006;15:62–64.
11. Sabharwal S, Tredwell SJ, Beauchamp RD, Mackenzie WG, Jakubec DM, Cairns R, LeBlanc JG. Management of pulseless pink hand in pediatric supracondylar fractures of humerus. *J PediatrOrthop.* 1997;17:303–310. doi: 10.1097/00004694-199705000-00007.
12. Shaw BA, Kasser JR, Emans JB, Rand FF. Management of vascular injuries in displaced supracondylar humerus fractures without arteriography. *J Orthop Trauma.* 1990;4:25–29. doi: 10.1097/00005131-199003000-00004.
13. Pirone AM, Graham HK, Kraijbich JI. Management of displaced extension-type supracondylar fractures of the humerus in children. *J Bone Joint Surg Am.* 1988;70:641–650.
14. Marck KW, Kooiman AM, Binnendijk B. Brachial artery rupture following supracondylar fracture of the humerus. *Neth J Surg.* 1986;38:81–84
15. Broudy S, Jupiter J, May JW., Jr Management of supracondylar fracture with brachial artery thrombosis in a child: case report and literature review. *J Orthop Trauma.* 1979;19:540–554.
16. Schuler JJ, Flanigan DP, Meyer JP. Combined vascular and orthopedic injuries. In: Flanigan DP, editor. *Civilian vascular trauma.* Pennsylvania: Lea &Febiger; 1992. pp. 265–267.
17. Luria S, Sucar A, Eylon S, Pinchas-Mizrachi R, Berlatzky Y, Anner H, Liebergall M, Porat S. Vascular complications of supracondylar humeral fractures in children. *J PediatrOrthop B.* 2007;16:133–143.