

Cortical thickness in provisional and chronic tic disorder

Kevin J. Black, MD¹⁻⁴ *
Jimin Ding, PhD⁵
Sarah C. Grossen, BS^{1,2}
Jonathan M. Koller, BSEE, BSBME³
Amel Lilic, BS¹
Luis A. Gonzalez, BS¹
Tamara Hershey, PhD^{1,3}
Deanna J. Greene, PhD⁶
Bradley L. Schlaggar, MD, PhD⁷

Departments of ¹Psychiatry, ²Neurology, ³Radiology, ⁴Neuroscience, and ⁵Statistics & Data Science, Washington University in St. Louis;

⁶Department of Cognitive Science, University of California San Diego;

⁷Kennedy Krieger Institute, Baltimore, MD, and Departments of Neurology and Pediatrics, The Johns Hopkins University School of Medicine.

* to whom correspondence should be addressed at

✉ kevin@WUSTL.edu

☎ +1 (314) 362-5041

📍 MSC 8134-70-2205, 660 S. Euclid Avenue, St. Louis, Missouri 63110-1010

Abstract

Background: Structural MRI studies have found thinner cortex in Tourette syndrome (TS) than in tic-free controls (TFC) in several cortical regions. Whether this thinning precedes or follows the first tic is unknown. Cortical thickness has not been reported in patients with a tic disorder less than one year in duration (Provisional Tic Disorder, PTD).

Objectives: Compare regional cortical thickness in TS, PTD and TFC.

Methods: T1-weighted brain MRI was acquired in 391 children 5-10 years old: 83 with PTD, 103 with TS, and 205 TFC. FreeSurfer measured cortical thickness in 34 cortical regions in each hemisphere. An ANCOVA compared regional cortical thickness between groups, controlling for age, sex, handedness and intracranial volume and correcting for multiple comparisons with Holm's method.

Results: Brain volume and mean cortical thickness differed significantly among groups (TS < PTD < TFC). That pattern was observed in 34 of 68 cortical regions, including in the subset of highest quality images acquired with prospective motion correction. The typical developmental cortical thinning from age 5.0-11.0 occurred 2-3 times faster in the tic groups. Predicted cortical thickness in the PTD group at tic onset was identical to that of the TFC group, but diminished over the first year to match the TS group at one year after tic onset.

Conclusion: These data from one of the largest imaging studies of tic disorders suggest that the thinner cortex in TS develops after rather than before tics begin. As such, it is

more likely to represent a consequence rather than a cause of tics. We hypothesize that it may reflect earlier maturation of inhibitory circuits because of extended experience suppressing tics.

Introduction

Tourette syndrome and chronic motor or phonic tic disorder (hereinafter, TS) are defined by unwanted, repeated movements and vocalizations (tics) that collectively occur over a period of a year or more without another cause.¹ Tics differ from other movement disorders phenomena in that they are relatively stereotyped but nonrhythmic, can be suppressed with effort for a period of time, and are often preceded by focal or generalized sensory phenomena or an urge to tic.²

In vivo structural MRI studies have found thinner precentral and/or postcentral gyrus in TS than in tic-free controls (TFC).³⁻⁸ These gyri contain primary motor cortex (M₁) and primary somatosensory cortex (S₁). This finding has been taken as supporting a model of tic disorders as characterized by hyperarousal, deficits in sensorimotor gating, and impaired cortical inhibition.⁹ However, results were not consistent,¹⁰ and most studies were relatively small. Other cortical regions showing thinning in structural MRI studies of TS include insula and orbital cortex.¹¹

Crucially, whether cortical thinning represents a cause or an effect of ticcing is unknown. Chronic ticcing or adaptation to chronic ticcing could result in structural changes to cortical regions.¹² Cortical thinning present when tics begin, or shortly afterwards, would support the interpretation that it contributes to causing tics. To date, however, cortical thickness has not yet been reported in Provisional Tic Disorder (PTD, defined as current tics with no tics present a year or more ago).

To investigate this question, we examined structural MRI data from the New Tics study,¹³

supplemented with data from additional TS and TFC scans on the same MRI scanners. We hypothesized that both TS and PTD would have thinner somatomotor cortex than TFC at the same age.

Methods

MR images from a total of 391 children were analyzed for this study: 83 with PTD, 103 with TS and 205 TFC. A parent or guardian gave informed consent to each child's participation in research. All children with PTD, along with 43 with TS and 26 TFC, were enrolled in the New Tics study. Others had previously given permission to share data with future research studies. For this analysis, diagnosis for all tic patients followed DSM-5 criteria¹ and was confirmed by an experienced Tourette clinician (authors KJB or BLS).

All participants had a T₁-weighted MRI of the brain (MP-RAGE sequence) on either a Siemens Trio or Prisma scanner with 0.5-1.0 mm³ voxels. Sequence details varied, and 217 scans were performed with prospective motion correction (vNavs) to minimize partial volume effect from head motion during scan acquisition (see Supplemental Table A).^{14, 15}

If a participant had more than one MP-RAGE image at a given session, the image with the highest *snr_total* value according to MRIQC was used in the analysis.¹⁶ FreeSurfer v. 7.3.2 was used to measure thickness of 34 cortical regions in each hemisphere and to estimate brain volume (eTIV).¹⁷⁻¹⁹ The cortical parcellation by FreeSurfer was visually reviewed for all subjects (original N = 409), and 18 scans with incorrect identification of the cortical ribbon were excluded.

Whole-brain effects of diagnosis were tested by a general linear model (hereinafter GLM) controlling for age, sex, handedness, and scanner. This analysis was done with estimated intracranial volume (eTIV) as the dependent variable, but to ensure robustness, it was repeated with eTIV replaced by mean cortical thickness and by total gray plus white matter volume (GM+WM).

Based on prior studies, we specified one *a priori* regional hypothesis; namely, that sensorimotor cortex would be thinner in children with tics. We tested this hypothesis by defining M₁S₁ in each participant as the average of bilateral mean precentral thickness (M₁) and bilateral mean postcentral thickness (S₁). An ANCOVA compared M₁S₁ between groups, controlling for age, sex, handedness and eTIV.

We also examined all 34 cortical regions in each hemisphere, with a GLM controlling for age, sex, handedness, scanner and eTIV. The effect of interest was a trend TS < PTD < TFC or in the opposite direction. Multiple comparisons correction used Holm's method with a family-wise Type I error (FWE) rate of .05 as the criterion for significance.²⁰

Exploratory analyses included the following. Cortical thickness in regions with a significant diagnosis-related trend was tested for correlation with YGTSS total tic score (TTS), available for $N = 202$, after accounting for age and sex. After predicting cortical thickness in significant regions based on the age and sex of the child using the ANCOVA model in the TFC group, the prediction error for children with tics (observed - predicted) was plotted against duration of illness (measured as days between tic onset and the scan), available for $N = 157$ including all PTD participants. The date of tic onset was estimated

carefully as described in detail elsewhere.²¹ We also tested for correlations of regional thickness among cortical regions. Finally, we used a principal components analysis (PCA) and a support vector machine (SVM) approach to assess how much diagnosis-related information was contained in the collection of all regional data, beyond what can be explained by effects in any single cortical region. The SVM included all the regional cortical thickness data in addition to age, sex, handedness, scanner and eTIV.

Results

Effects of age, sex, handedness and scanner

Brain volume showed essentially the same results whether measured with eTIV or GM+WM. Older children have larger brains, boys have larger brains, and brain volume was smaller in scans from the Trio than in the prospective motion-corrected Prisma scans. As for mean cortical thickness, older children have thinner cortex ($p = 3.7 \times 10^{-8}$) and boys have thinner cortex than girls ($p = .0003$). Handedness, scanner, and the age \times sex interaction were not statistically significant.

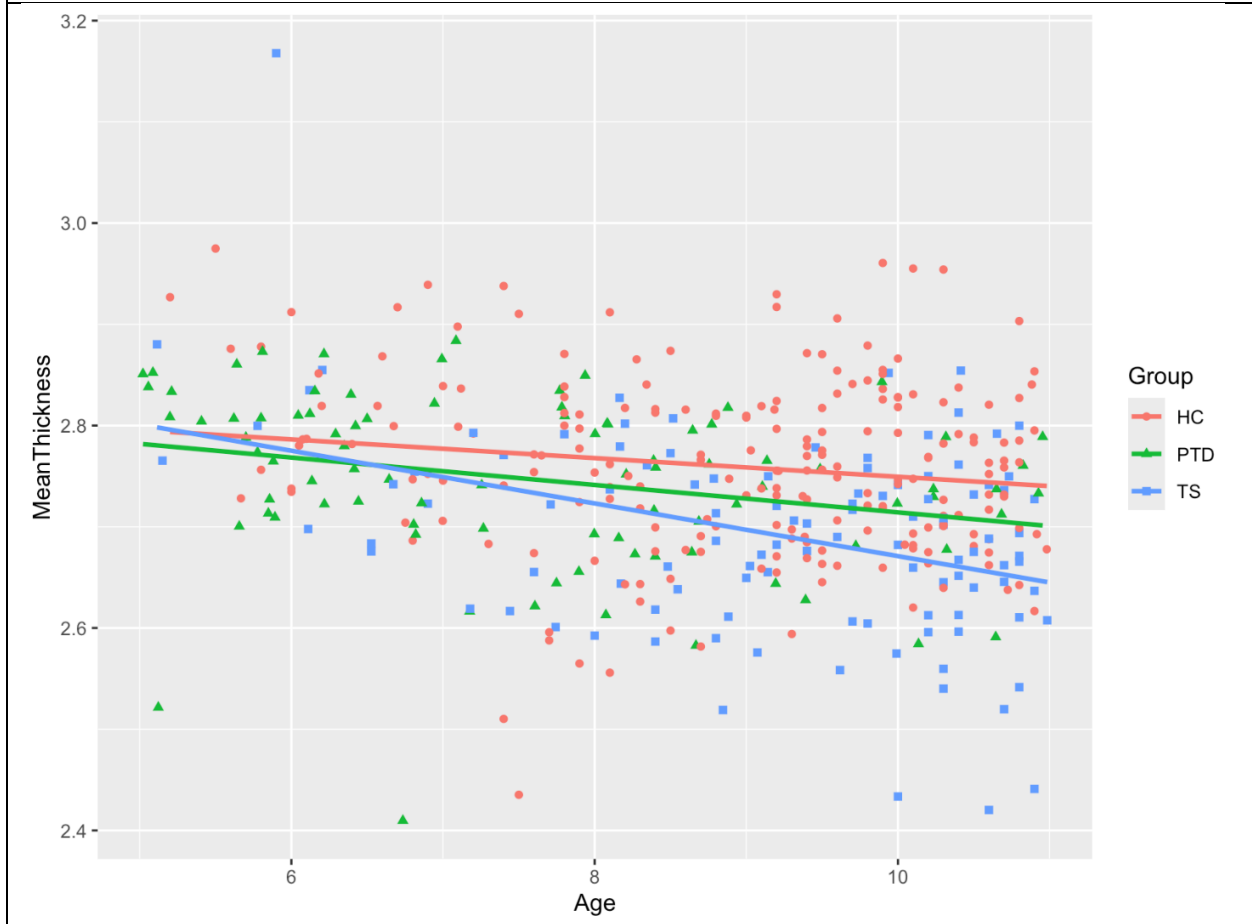Global effects of diagnosis

Controlling for age, sex, handedness and scanner, whole brain volume differed significantly by diagnosis (TS < PTD < TFC, $p < .00001$). Post-hoc comparisons found TS < TFC $p = .0001$, PTD < TFC, $p = .09$. For eTIV, factor and covariate p values included PTD diagnosis .0016, TS diagnosis .0001, age 1.6×10^{-7} , sex 4.5×10^{-22} , handedness .09, and scanner 9.0×10^{-6} . Results were roughly similar for total gray and white matter volume, including PTD diagnosis $p = .0070$, TS diagnosis $p = 2.6 \times 10^{-5}$.

Mean left or right cortical thickness also differed significantly by diagnosis (TS < PTD < TS), controlling for age, sex, handedness and scanner, whether or not eTIV was included as an additional covariate (left, $p = .08$ for PTD, $.0001$ for TS; right, $.10$ for PTD, $.0001$ for TS). Mean left hemisphere cortex was about 1.4% thinner in TS (mean 2.87 mm) than in TFC (mean 2.91 mm), with PTD intermediate (mean 2.89 mm), only 0.6% thinner than in TFC.

All three groups had similar cortical thickness at age 5, but children with tics experienced faster cortical thinning than those without the tics. The slopes of cortical thinning as the children grow older are ranked TS < PTD < TFC < zero (Figure 1). The slope seen in typical development is nearly doubled in PTD and tripled in TS. This result still holds when sex, handedness and eTIV are included in the model.

Figure 1. Mean whole-brain cortical thickness decreases with age from 5 to < 11 years old, and does so faster in children with tics.



A priori hypothesis

Controlling for age, sex, handedness, scanner and brain volume, M_1S_1 differed significantly among groups ($p < .0001$). It is smaller in TS than in controls (LSE = $-.05$, $p = .0003$), and nonsignificantly smaller in PTD (least squares difference LSE = $-.01$, $p = .36$ vs TFC). The difference is all explained by precentral gyrus (M_1), $p_{FWE} = .0116$ left, NS right; postcentral gyrus did not differ significantly.

Whole-cortex analysis

Numerous cortical regions showed diagnosis-related differences in thickness, correcting for age, sex, handedness, scanner and brain volume (Table 1). All were thinner in TS than in PTD and TFC.

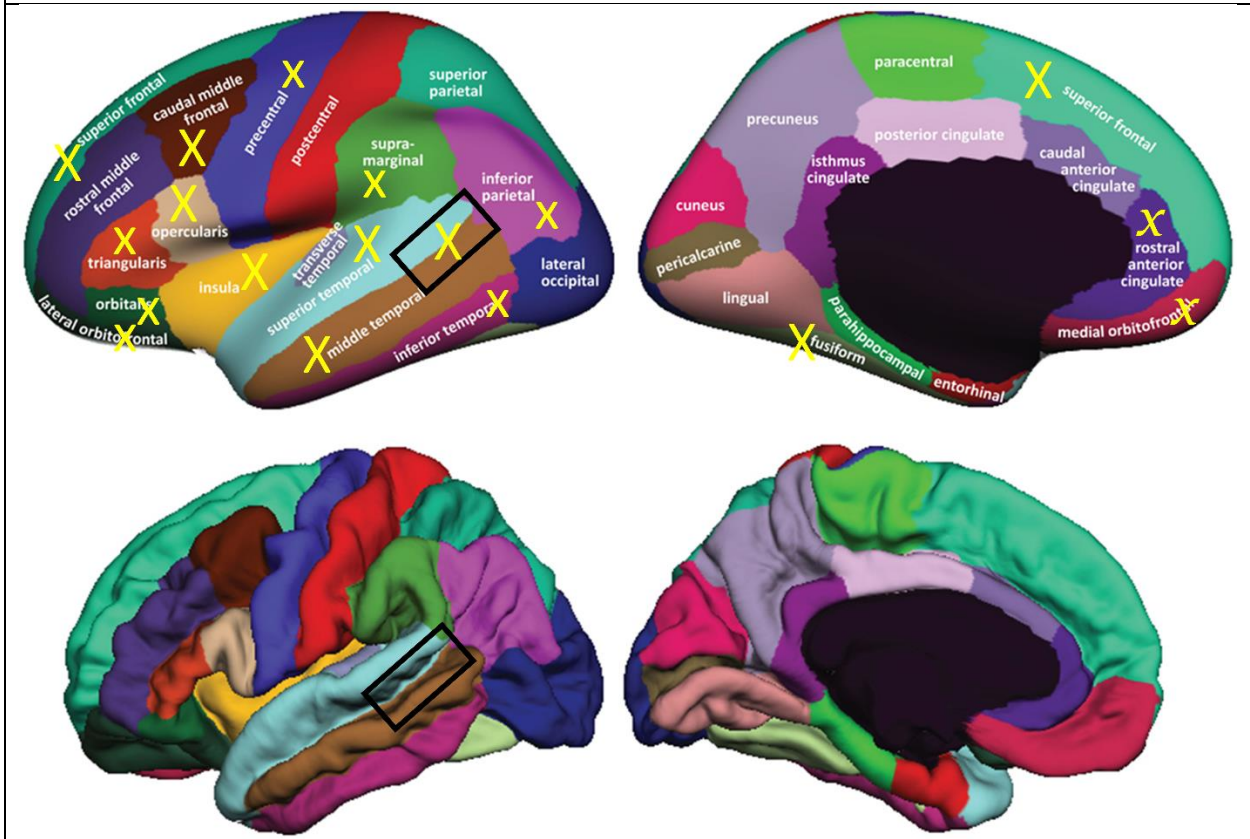Table 1. FWE-corrected p values for cortical regions with a TS < PTD < TFC trend.

LHem = left hemisphere. RHem = right hemisphere. “.0000” means <.00005.

region	p (LHem)	p (RHem)
caudal middle frontal	.0000	.0009
pars opercularis	.0001	.0054
banks of superior temporal sulcus	.0001	
superior temporal	.0001	.0001
middle temporal	.0002	.0102
superior frontal	.0005	.0028
insula	.0007	
fusiform	.0009	.0000
inferior parietal	.0013	
inferior temporal	.0027	
pars triangularis	.0066	
precentral	.0116	
lateral orbitofrontal	.0193	
supramarginal	.0287	.0489
pars orbitalis	.0319	.0388
medial orbitofrontal		.0404
rostral anterior cingulate		.0409

Figure 2. Cortical regions showing a significant trend TS < PTD < TFC.

A capital X indicates a region with $p_{FWE} < .001$, and a lower-case x indicates $.05 < p_{FWE} < .001$, for the left hemisphere, which underlies them. The italic, serif x marks two regions that are only significant on the right hemisphere. The black rectangles mark the approximate location of the FreeSurfer “banks of superior temporal sulcus” region. The underlying figure is from ref. ²², © Klein and Tourville, 2012, released under a Creative Commons Attribution License.



These regions cover the lateral and inferior temporal lobe and most of the lateral frontal lobe, plus the rostral anterior cingulate and the medial orbitofrontal cortex (yellow markers in Figure 2).

The PCA showed that 33.4% of the variance was explained by the first principal component alone, with subsequent components individually contributing little additional information. The first 4 PCs explain just over half of the total variance. The tic groups are not well separated by the first few PCs. In the SVM analysis, age, sex, handedness, scanner

and eTIV left a diagnostic group misclassification rate of 41%, but adding all the cortical thickness data reduced the misclassification rate to 17%. One third of this improvement can be achieved using only mean cortical thickness.

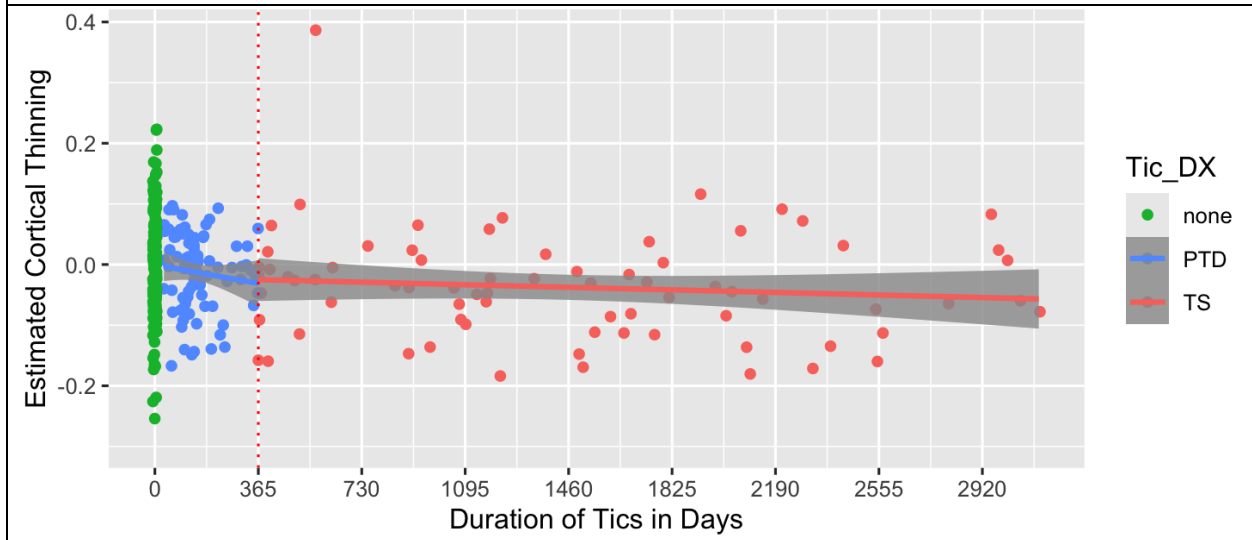
Effects of illness severity or duration

Mean TTS was higher in TS than in PTD (20.0 ± 7.0 vs. 16.9 ± 5.6 , $p = .001$, two tails).

Cortical thickness did not correlate significantly with YGTSS total tic score (TTS) across the entire tic group, but differed significantly between the PTD and TS groups. This finding held either with or without correction for age, sex and scanner.

Cortical thickness in the PTD group was examined in terms of its deviation from the expected values from the TFC group for each child's age and sex (blue dots between 0 and 365 days after tic onset in Figure 3). Cortical thickness at tic onset was identical to that of the TFC group (*i.e.*, the y -intercept of the linear fit in the PTD group was .000), but diminished over the first year to match the TS group at one year after tic onset (the TS group is shown in red dots in Figure 3).

Figure 3. Cortical thickness in the M1S1 region compared to the predicted value based on age and sex compared to the TFC group, plotted by days after tic onset (PTD in blue between 0 and 365 days, TS in red after 365 days). The TFC group is plotted in green at time = 0.



Discussion

In vivo structural MRI studies have found thinning of primary motor or somatosensory cortex in TS.^{3-5, 8, 23} These findings have been taken as supporting a model that characterizes tic disorders as involving hyperarousal, deficits in sensorimotor gating, and impaired cortical inhibition.⁹ Other structural MRI studies have found reduced cortical thickness or volume in insula or orbital prefrontal cortex, which comprise part of the brain's social decision-making network, dysfunction in which is hypothesized to explain important features of TS.^{6, 24-27}

However, these studies left three important questions in their wake. First, results were only partially replicated across studies. Given the variability, one is left with the question of which cortical areas are truly thinner in tic patients? Second, among various

differences in these studies, some studied children and others adults. When does cortical thinning develop relative to age, or relative to the onset of ticcing? Third, most prior reports discuss the results as explaining the existence or characteristics of tics, though the cross-sectional association of cortical thinning with diagnosis does not imply that the thinning causes or mediates the appearance of tics. The present study helps resolve these questions by virtue of a sample size more than 3 times larger than any of these previous studies and, importantly, including for the first time a large sample of children with tics for less than a year.

First, our results confirm many of these earlier findings and suggest that in fact numerous cortical regions are thinner in TS. Likely the differences in specific regions previous studies identified reflects in part Type II errors that the larger sample minimizes. Second, thinning appears not to be present at tic onset but to progress over the first year to match that of TS participants at one year's duration. At the same age, cortical thinning is greater in magnitude in chronic than in recent-onset tics. Such results suggest not lesions causing tics but cortical thinning that develops over time with tics. What might explain this result? One possibility is suggested by the observation that from age 5 to 10, cortex *thins* with age even in TFC. Several large studies find the same pattern, while others have reported that thinning starts around age 8.²⁸⁻³¹ In that light, cortical thinning in TS may represent not a lesion but rather faster maturation than is evident in children without tics. Possibly this early maturation could reflect experience inhibiting tics. Structural correlates of such inhibition would be expected to develop gradually over time after the onset of tics, and to develop to a greater extent than in children without tics, who do not

experience the same nearly constant need to suppress tics. This is in fact the pattern observed in the PTD group in the present study. This model may explain why in other studies thinning in various cortical regions has correlated with greater tic severity.^{4, 5, 24} Fahim et al showed that progressive cortical thinning regions continued from ages 10 to 25 years, though in 3 of 4 regions, extrapolating from linear regression in each group suggested that the thinning in TS would slow over that age interval so as to match the thickness of the TFC group by age 20–30.⁵ This result would fit the clinical observation that tics generally improve from approximately 10 to 25 years. In the early inhibitory maturation model above, these results would be interpreted as reflecting decreased need to suppress tics over that time interval, plus the eventual development in TFC of inhibitory control for non-tic behavior.

Limitations

Children with different tic diagnoses were not balanced across scanners. However, this imbalance does not explain our key results. The children with PTD were more likely to be scanned on the Prisma, which was associated with thicker cortex, yet they had thinner cortex than did tic-free controls. Additionally, the GLM included a factor for scanner.

Head movement during scan acquisition can lead to apparent artifactual thinning of the cortex.³²⁻³⁵ The finding that cortex was thinner if measured on the Trio than on the Prisma, all other factors being equal, is consistent with this known artifact. In this setting it is natural to wonder whether the presence during the scan of tics that moved the head created artifactual results. Again, however, this concern does not affect our key results.

The Prisma vNav scans, which minimize movement-related effects on structural MRI,¹⁵ show the same differences by diagnostic group. Although tics are more severe in the TS group (at least outside of the scanner), cortical thinning did not differ significantly by diagnosis. Finally, tics are suppressible, and most of the children in these studies had practice holding still, including training in a mock scanner. Thus tics on the day of the scan do not necessarily imply that tics that caused head movement were present during the scan acquisition.

Conclusion

In conclusion, the brain is slightly smaller in children age 5-10 who have TS than in tic-free controls, and less so in children the same age with tics for less than a year ($TS < PTD \lesssim TFC$). The cortex is overall thinner in the same pattern ($TS < PTD \lesssim TFC$). Numerous cortical regions contribute to this pattern, with mean cortical thickness supplying a meaningful fraction of the total pattern, yet thickness in numerous regions contains information relevant to diagnosis. Overall, these data suggest that the thinner primary motor cortex in TS develops beginning at tic onset and gradually progresses over the first 8 years after tic onset. As such, thinning of M_1 (and of other cortical regions) is more likely to represent a consequence than a cause of tics. The data are consistent with the hypothesis that over time, chronic tic suppression affects brain structure in the same direction as does growth and maturation over this age range.

Acknowledgments

Emily C. Bihun, M.Ed., was indispensable in data collection and curation. We thank the Tourette Association of America for recruitment support and our study participants and families for their time and efforts to support the research.

Funding

Research reported in this publication was supported by the National Institute of Mental Health, the National Institute of Neurological Disorders and Stroke, the Eunice Kennedy Shriver National Institute of Child Health and Human Development, the National Cancer Institute, and the National Center for Advancing Translational Sciences of the National Institutes of Health under award numbers K24MH087918, R01MH104030, R01MH126213, R01HD070855, R01DK064832, R21NS091635, K01MH104592, P30CA091842, U54HD087011, UL1RR024992, UL1TR000448, UL1TR002345, and by the Neuroimaging Laboratories Research Center of the Mallinckrodt Institute of Radiology and Washington University. The content is solely the responsibility of the authors and does not necessarily represent the official views of the sponsors.

References

1. American Psychiatric Association. *Diagnostic and Statistical Manual of Mental Disorders, Fifth Edition*. Arlington, VA: American Psychiatric Association; 2013.
2. Black KJ. Tics. In: Kompoliti K, Verhagen Metman L, Comella C, et al., eds. *Encyclopedia of Movement Disorders*. Vol 3. Oxford: Elsevier (Academic Press); 2010:231-236. doi 10.1016/B978-0-12-374105-9.00385-3
3. Sowell ER, Kan E, Yoshii J, et al. Thinning of sensorimotor cortices in children with Tourette syndrome. *Nat. Neurosci.* 2008;11:637-639. doi 10.1038/nn.2121
4. Worbe Y, Gerardin E, Hartmann A, et al. Distinct structural changes underpin clinical phenotypes in patients with Gilles de la Tourette syndrome. *Brain : a journal of neurology.* 2010;133 Pt 12:3649-3660. doi 10.1093/brain/awq293
5. Fahim C, Yoon U, Das S, et al. Somatosensory-motor bodily representation cortical thinning in Tourette: Effects of tic severity, age and gender. *Cortex.* 2010;46:750-760. doi 10.1016/j.cortex.2009.06.008
6. Draper A, Jackson G, Morgan P, Jackson S. Premonitory urges are associated with decreased grey matter thickness within the insula and sensorimotor cortex in young people with Tourette syndrome. *J. Neuropsychol.* 2015;10:143-153. doi 10.1111/jnp.12089
7. Muellner J, Delmaire C, Valabrègue R, et al. Altered structure of cortical sulci in Gilles de la Tourette syndrome: Further support for abnormal brain development. *Mov. Disord.* 2015;30. doi 10.1002/mds.26207
8. Kong L, Lv B, Wu T, et al. Altered structural cerebral cortex in children with Tourette syndrome. *Eur. J. Radiol.* 2020;129:109119. doi 10.1016/j.ejrad.2020.109119
9. Grados MA, Mathews CA. Clinical phenomenology and phenotype variability in Tourette syndrome. *J. Psychosom. Res.* 2009;67(6):491-496. doi 10.1016/j.jpsychores.2009.07.011
10. Draganski B, Martino D, Cavanna A, et al. Multispectral brain morphometry in Tourette syndrome persisting into adulthood. *Brain.* 2010;133:3661-3675. doi 10.1093/brain/awq300
11. Wan X, Zhang S, Wang W, et al. Gray matter abnormalities in Tourette Syndrome: a meta-analysis of voxel-based morphometry studies. *Transl Psychiatry.* 2021;11(1):287. doi 10.1038/s41398-021-01394-8
12. Plessen KJ, Bansal R, Peterson BS. Imaging evidence for anatomical disturbances and neuroplastic compensation in persons with Tourette syndrome. *J. Psychosom. Res.* 2009;67(6):559-573. doi 10.1016/j.jpsychores.2009.07.005
13. Black KJ, Kim S, Schlaggar BL, Greene DJ. The New Tics study: A novel approach to pathophysiology and cause of tic disorders. *J Psychiatr Brain Sci.* 2020;5:e200012. doi 10.20900/jpbs.20200012

14. Tisdall MD, Hess AT, Reuter M, Meintjes EM, Fischl B, van der Kouwe AJ. Volumetric navigators for prospective motion correction and selective reacquisition in neuroanatomical MRI. *Magn. Reson. Med.* 2012;68(2):389-399. doi 10.1002/mrm.23228
15. Tisdall MD, Reuter M, Qureshi A, Buckner RL, Fischl B, van der Kouwe AJ. Prospective motion correction with volumetric navigators (vNavs) reduces the bias and variance in brain morphometry induced by subject motion. *Neuroimage.* 2016;127:11-22. doi 10.1016/j.neuroimage.2015.11.054
16. Esteban O, Birman D, Schaer M, Koyejo OO, Poldrack RA, Gorgolewski KJ. MRIQC: Advancing the automatic prediction of image quality in MRI from unseen sites. *PLoS One.* 2017;12(9):e0184661. doi 10.1371/journal.pone.0184661
17. Fischl B, Dale AM. Measuring the thickness of the human cerebral cortex from magnetic resonance images. *Proc. Natl. Acad. Sci. U. S. A.* 2000;97(20):11050-11055. doi 10.1073/pnas.200033797
18. Fischl B, van der Kouwe A, Destrieux C, et al. Automatically parcellating the human cerebral cortex. *Cereb. Cortex.* 2004;14(1):11-22.
19. Desikan RS, Segonne F, Fischl B, et al. An automated labeling system for subdividing the human cerebral cortex on MRI scans into gyral based regions of interest. *Neuroimage.* 2006;31(3):968-980. doi 10.1016/j.neuroimage.2006.01.021
20. Holm S. A simple sequentially rejective multiple test procedure. *Scandinavian Journal of Statistics.* 1979;6(2):65-70.
21. Grossen SC, Arbuckle AL, Bihun EC, et al. We've all been wrong about provisional tic disorder. *Compr. Psychiatry.* 2024;134:152510. doi 10.1016/j.comppsy.2024.152510
22. Klein A, Tourville J. 101 Labeled Brain Images and a Consistent Human Cortical Labeling Protocol. *Front. Neurosci.* 2012;6. doi 10.3389/fnins.2012.00171
23. Muellner J, Delmaire C, Valabregue R, et al. Altered structure of cortical sulci in Gilles de la Tourette syndrome: Further support for abnormal brain development. *Mov Disord.* 2015;30(5):655-661. doi 10.1002/mds.26207
24. Draganski B, Martino D, Cavanna AE, et al. Multispectral brain morphometry in Tourette syndrome persisting into adulthood. *Brain.* 2010;133(Pt 12):3661-3675. doi 10.1093/brain/awq300
25. Vicario CM, Martino D. Social communication in Tourette syndrome: a glimpse at the contribution of the insula and the prefrontal cortex. *Brain.* 2018;141(8):e58. doi 10.1093/brain/awy140
26. Albin RL. Tourette syndrome as a disorder of the social decision making network. *Front Psychiatry.* 2019;10:742. doi 10.3389/fpsy.2019.00742
27. Jackson SR, Loayza J, Crighton M, Sigurdsson HP, Dyke K, Jackson GM. The role of the

- insula in the generation of motor tics and the experience of the premonitory urge-to-tic in Tourette syndrome. *Cortex*. 2020;126:119-133. doi 10.1016/j.cortex.2019.12.021
28. Walhovd KB, Fjell AM, Giedd J, Dale AM, Brown TT. Through Thick and Thin: a Need to Reconcile Contradictory Results on Trajectories in Human Cortical Development. *Cereb. Cortex*. 2017;27(2):1472-1481. doi 10.1093/cercor/bhv301
 29. Brown TT, Jernigan TL. Brain development during the preschool years. *Neuropsychol. Rev.* 2012;22(4):313-333. doi 10.1007/s11065-012-9214-1
 30. Sanders AFP, Baum GL, Harms MP, et al. Developmental trajectories of cortical thickness by functional brain network: The roles of pubertal timing and socioeconomic status. *Dev. Cogn. Neurosci.* 2022;57:101145. doi 10.1016/j.dcn.2022.101145
 31. Luby JL, Belden AC, Jackson JJ, et al. Early Childhood Depression and Alterations in the Trajectory of Gray Matter Maturation in Middle Childhood and Early Adolescence. *JAMA Psychiatry*. 2016;73(1):31-38. doi 10.1001/jamapsychiatry.2015.2356
 32. Reuter M, Tisdall MD, Qureshi A, Buckner RL, van der Kouwe AJW, Fischl B. Head motion during MRI acquisition reduces gray matter volume and thickness estimates. *Neuroimage*. 2015;107:107-115. doi 10.1016/j.neuroimage.2014.12.006
 33. Alexander-Bloch A, Clasen L, Stockman M, et al. Subtle in-scanner motion biases automated measurement of brain anatomy from in vivo MRI. *Hum. Brain Mapp.* 2016;37(7):2385-2397. doi 10.1002/hbm.23180
 34. Pardoe HR, Kucharsky Hiess R, Kuzniecky R. Motion and morphometry in clinical and nonclinical populations. *Neuroimage*. 2016;135:177-185. doi 10.1016/j.neuroimage.2016.05.005
 35. Savalia NK, Agres PF, Chan MY, Feczko EJ, Kennedy KM, Wig GS. Motion-related artifacts in structural brain images revealed with independent estimates of in-scanner head motion. *Hum. Brain Mapp.* 2017;38(1):472-492. doi 10.1002/hbm.23397

Supplemental Table A

Acquisition details, by diagnostic group, for all MRI scans used in this analysis.

Scanner	Sequence	Head Coil	TR (ms)	TE (ms)	TI (ms)	Voxel Size (mm)	TS	PTD	TFC
<i>Siemens Prisma, 166038</i>	tfl3d1_16ns\tfl_mgh_epinav_ABCD	32-channel	2500	2.9	1070	1x1x1	18	0	0
<i>Siemens Prisma, 67064</i>	tfl3d1_16ns\tfl	64-channel	2400	2.22	1000	0.8x0.8x0.8	0	4	0
	tfl3d1_16ns\tfl_mgh_epinav_ABCD	20-channel	2500	2.9	1070	1x1x1	0	0	54
	tfl3d1_16ns\tfl_mgh_epinav_ABCD	64-channel	2500	2.9	1070	1x1x1	40	59	35
<i>Siemens Trio, 35177</i>	tfl3d1_16ns\tfl	12-channel	2200	2.34	1000	1x1x1	14	20	1
	tfl3d1_16ns\tfl	12-channel	2400	3.08	1000	1x1x1	15	0	30
	tfl3d1_16ns\tfl	12-channel	2400	3.12	1000	1x1x1	3	0	14
	tfl3d1_16ns\tfl	12-channel	2400	3.13	1000	1x1x1	7	0	4
	tfl3d1_16ns\tfl	12-channel	2400	3.14	1000	1x1x1	3	0	11
	tfl3d1_16ns\tfl	12-channel	2400	3.17	1000	1x1x1	1	0	2
	tfl3d1_16ns\tfl_mgh_epinav_ABCD	12-channel	2530	1.74	1000	1x1x1	0	0	3
	tfl3d1_16ns\tfl_mgh_epinav_ABCD	12-channel	2530	1.74	1070	1x1x1	2	0	3
	tfl3d1_16ns\tfl_mgh_epinav_ABCD	12-channel	2530	1.74	1100	1x1x1	0	0	1
	tfl3d1_16ns\tfl_mgh_epinav_ABCD	12-channel	2530	1.74	1200	1x1x1	0	0	2
<i>Siemens Trio, 35248</i>	tfl3d1_16ns\tfl	12-channel	1900	2.92	1100	0.8x0.8x0.8	0	0	2
	tfl3d1_16ns\tfl	12-channel	1900	2.92	1100	1x1x1	0	0	25
	tfl3d1_16ns\tfl	12-channel	2400	3.16	1000	1x1x1	0	0	18