

COMPUTER TOMOSYNTHESIS:
A VERSATILE THREE-DIMENSIONAL IMAGING TECHNIQUE

U.E. Ruttimann, R.A.J. Groenhuis, and R.L. Webber

National Institute of Dental Research
National Institutes of Health
Bethesda, Maryland, USA

Abstract

Tomosynthesis permits the representation of internal structures of an object by an arbitrary number of frontal sections (tomosynthetic slices), from a finite set of radiographs, each imaging the object at a different projection angle. Tomosynthetic reconstructions produce a sharp image of structures lying in the desired tomosynthetic slice, on which blurred images of object detail lying outside the plane of interest are superimposed. Slice thickness is largely determined by the projection angle. Advantageous features of tomosynthesis are the limited size of the projection angle required, the selective positioning of the tomosynthetic plane after recording of the radiographs, and the computational simplicity permitting real-time implementation. Applications to dental radiography demonstrate the feasibility to synthesize tomographic slices with a thickness of about 3 mm from as few as 8 radiographs exposed on a circular projection cone with half-angle of 4.5° . The reconstructions not only indicate the relative spatial position of the dental tissues, but also show clinically relevant structures not visible in the original radiographs.

Introduction

The basic principle of tomosynthesis has been formulated originally by Ziedes des Plantes in 1935¹. It permits representation of the internal structures of an object in frontal cross-sections by summation of a set of component radiographs, each imaging the object at a different projection angle. In the summation process, the radiographs are translated properly such that there is complete coincidence of the images corresponding to object points in the tomographic plane. E.g., to form a tomosynthetic reconstruction of a plane containing point A, as shown in Fig. 1, radiographs are displaced in such a way that the projections A1 and A2 coincide. The projections of points outside that plane will not coincide exactly in the superposition of the component radiographs, and thus, a blurring of detail will be affected. As a result, a tomosynthetic reconstruction produces a sharp image of structures in the desired plane, on which blurred images of object details lying outside the plane of interest are superimposed.

This is in contrast to the more familiar computerized axial tomography (CAT) where the image produced is an actual slice of given thickness through the object (Table 1. There, the

direction of the projection is parallel to the slice, and the summation (back-projection) is performed with filtered one-dimensional projections of the slice, obtained over the entire angle of 180° . While the visual quality of tomosynthetic reconstructions is inferior to that obtained from CAT, there are features of tomosynthesis which could make it a viable alternative, particularly for imaging objects of high intrinsic contrast such as calcified tissues. (1) Tomosynthesis is readily applicable to radiographic projections obtained over a limited angle of view; (2) the position of the tomosynthetic plane can be varied after the radiographs have been recorded; (3) the lateral shifts and summation of the radiographs required for the synthesis are computationally simple and can be done in real time with commercially available image frame buffers.

This report explores the potential use of computerized tomosynthesis in dental applications. The ability to synthesize reconstruction from projections obtained over a limited angle of view is of primary interest in this application because it permits the use of imaging geometry which is compatible with anatomical constraints imposed by oral structures. With an appropriate detector-source configuration the thickness of the layer of tissues to be imaged can be kept at a minimum. This layer typically consists of about 1 cm of soft tissues obscuring the object of primary interest, which is about 1 cm of calcified tissues. Such a small object thickness potentially reduces the impact of the major shortcoming of tomosynthesis, the appearance of blurred structures lying outside the tomosynthetic plane.

Materials and Methods

Grant² showed that the blurring of detail lying in unwanted planes is basically a linear filtering process with the transfer function specified by the radiographic projection geometry. The latter is determined largely by the number of tomosynthetic slices desired, and the object thickness. The total facial-lingual dimension of the teeth and periodontal tissues constitute the object thickness which is normally about $z_0 = 10$ mm. A number of 3 slices over this depth are considered diagnostically sufficient. The size of the trabeculae in inter-dental bone is approximately 0.5 mm, which was taken as the characteristic size, d_c , of object detail. The magnification of the imaging configuration is close to 1, because the distance between object and x-ray film is much shorter than the distance between object and x-ray

source. The source was positioned uniformly on a circular array as shown in Fig. 2. With the spatial constraints given above, it can be shown³ that the projection angle required is $\alpha = 4.5^\circ$, and the minimum number of radiographs to be taken on this projection cone is 8.

For this feasibility study, the set of component radiographs required to satisfy the described projection geometry was obtained by the experimental arrangement shown in Fig. 3. Dry human mandibles were mounted together with a holder for the x-ray film (Kodak dental film, Ultraspeed D), and metal crosshairs on a mechanical device. This device assured a reproducible spatial relationship between the x-ray source, object, and film, and permitted horizontal and vertical rotation of object and film with respect to the x-ray beam. The effects of soft-tissue scatter were produced by a 1 cm thick slab of tissue-equivalent plastic interposed between the mandible and the cone tip of the x-ray machine. The radiographs obtained under these conditions were converted to 512 x 512 x 8 bit (256 gray-levels) digital images by a TV camera interfaced with an analog-to-digital converter, and stored in an image frame buffer (De Anza IP 6400). From there, the images could be displayed under control of the host computer (PDP-11/34) on conventional video monitors, or stored on magnetic disks. Registration of the images before digitization was achieved by positioning the radiographs with the aid of a micromanipulator under the TV camera, while viewing on the monitor the result of the video-signal subtraction from a reference radiograph stored in the frame buffer. When the images of the crosshairs cancelled in the subtraction images, registration was attained and the radiograph was digitized. This process was repeated for the complete set of component radiographs.

The tomosynthetic slices were generated by shifting the digitized radiographs under computer control laterally with respect to each other, and averaging over the set of properly shifted images. The amount of the relative shift determines the tomosynthetic plane³.

The edge contrast of the tomosynthetic images was subsequently increased by means of a three-dimensional constrained iterative restoration algorithm⁴. In this process, properly blurred replica of tomograms from the other reconstruction planes are subtracted from the tomogram of the desired plane. As a result, a partial cancellation of the blurred structures arising from details lying in other planes is achieved, and the resulting images have better edge contrast.

Results

Fig. 4 shows one of the component radiographs used in this study. The cross is the projection of the metal crosshairs used for registration purposes as discussed in the Methods section. Figures 5, 6, and 7 show three tomosynthetic reconstructions made from 8 radiographs with a circular projection geometry and a cone angle of 4.5° . In Figure 6 the reconstruction slice is a frontal plane through the central groove of the

molars. Figures 5 and 7 correspond to frontal planes located 2.5 mm lingually and buccally, respectively.

The reconstructions indicate the relative position of the structures in space. E.g., the artificially induced interproximal lesion in the second molar is visible in the lingual and central planes only (Figures 5 and 6), and thus is positioned somewhere between these planes. The slope of the bone crest between the molars is different in the lingual plane from that in the buccal plane. Notice further the appearance or disappearance as a function of depth of the spicule of calculus on the mesial surface of the second molar, the pulpstone in the third molar, and the cracks in the second molar.

The reconstructions also show features definitely not visible in the original radiographs. In Figure 5 the exact shape of a third root of the third molar is clearly seen. Also, the fracture in this root, which was caused when the molar was extracted to induce an artificial lesion, can be discerned. In Figure 6, only the tip of the third root is in focus, indicating that the root curls under the molar toward the central plane.

Discussion

The results demonstrate that clinically interesting tomosynthetic images can be reconstructed by computer. Theory indicated that for the specific application intended a set of as low as 8 radiographs, obtained on a circular projection cone with an angle of 4.5° , was sufficient. This expectation has been confirmed. Not only were the relative spatial positions of dental tissues made apparent in this way, but also structural details unrecognizable in the original radiographs became visible in the tomographic reconstructions. It is to be re-emphasized that these results were obtained with an angle of view of only 4.5° , which is extremely limited when compared to the 180° required by the familiar transaxial methods. With this small angle the slice thickness is about 3 mm. Doubling it would reduce the slice thickness to one half this value. However, once the cone angle is chosen for a particular set of radiographs, slice thickness is fixed. What can be varied after the radiographic exposures have been made is the position of the slice within the object. This flexibility enables the clinician to scan through the object and bring planes of particular interest into focus.

The importance of the projection geometry in dental radiography has been long recognized^{5,6}, because structures or pathological changes visible in one projection may become completely obliterated by anatomical overlay in another projection. With the exception of interproximal caries, the exact location of tissue changes of clinical interest are usually not known beforehand, and hence, an optimal projection geometry is difficult to attain. One solution to this problem is to take multiple exposures at different angles, and choose the radiograph which is most diagnostic for the specific task. Taking the multiple samples in a controlled and specific way permits, as shown in this study, the reconstruction of tomosynthetic

planes. Not only does this technique make use of all radiographs simultaneously so that no information is lost, it also provides the additional benefit of a three-dimensional perception of the anatomical structures. At the same time, each component of the multiple sample is a radiograph in its own right and may be used, if desired, to produce subtraction images in serial radiographic examinations.

The application of tomosynthesis in dental practice must await the solution of some technical problems, which do not appear to lay beyond the current state of the art. Because it is mandatory that the patient remain stationary during the time all component radiographic projections are recorded, conventional x-ray sources and film cannot be used. Systems using a multiple-focal-spot, pulsed x-ray source in conjunction with a photo-electronic x-ray detector under computer control are a possible technical realization. A system based on these principles is currently under investigation and being developed by the Radiation Physics Group at the National Bureau of Standards (NIH-BUDR-8-80-9, interagency agreement).

In conclusion, the study shows the feasibility to synthesize tomograms with a slice thickness of about 3 mm from as few as 8 radiographs exposed on a circular projection cone with a half-angle of 4.5° . The resulting reconstructions not only indicate the relative spatial position of the dental tissue, but also show clinically relevant structures not visible in the original radiographs.

References

1. Ziedses des Plantes, B.G. Selected works of B.G. Ziedses des Plantes, Amsterdam, The Netherlands, 1973, Excerpta Medica. pp. 129-143.
2. Grant, D.G. Tomosynthesis: a three dimensional radiographic imaging technique, IEEE Trans Biomed Eng, BME-19: 20-28, 1972.
3. Groenhuis, R.A.J., Webber, R.L., and Ruttimann, U.E. Computerized tomosynthesis of dental tissues, submitted to Oral Surg, 1983.
4. Schafer, R.W., Merserau, R.M., and Richards, M.A. Constrained iterative restoration algorithms, Proc IEEE, 69: 432-450, 1981.
5. Wege, W.R. A technique for sequentially reproducing intraoral film, Oral Surg 23: 454-458, 1967.
6. Duinkerke, A.S.H., Poel, A.C.M., et al. Evaluation of a technique for standardizing periapical radiography, Oral Surg 44: 645-651, 1977.
7. Ruttimann, U.E., Webber, R.L., and Grondahl, H.G. Subtraction radiography in dentistry. Sixth Annual Symposium of Computer Applications in Medical Care, Washington, D.C., 1982, pp. 937-942.

Table 1
Comparison of Tomosynthesis
with Axial Computer Tomography

	Tomosynthesis	Axial CT
Applicable with limited angle of view	yes	no
Cancellation of out of slice details	incomplete	complete
Slice position variable after recording	yes	no

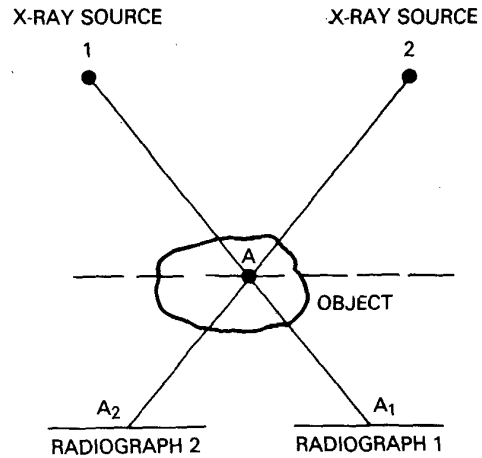


Fig. 1 Principle of tomosynthetic reconstruction. Shift of radiographs 1 and 2 such that A1 and A2 coincide and subsequent addition yields a tomogram through point A.

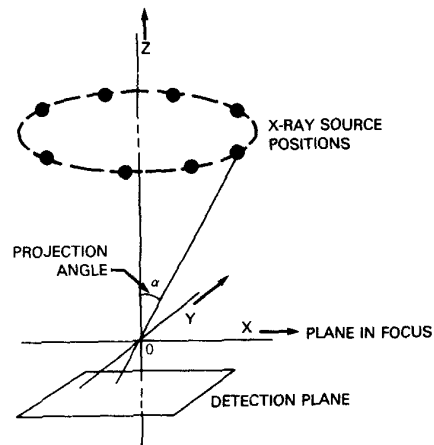


Fig. 2 Circular tomographic projection procedure.

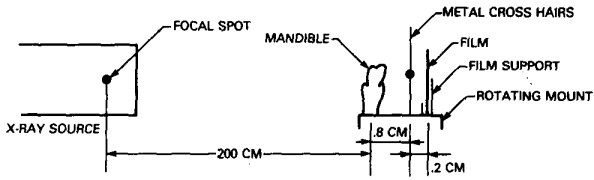


Fig. 3 Experimental arrangement to obtain the component radiographs.

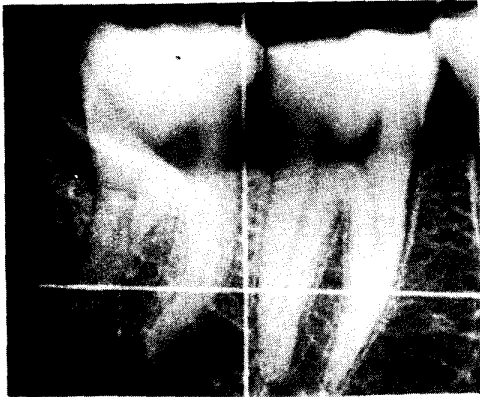


Fig. 4 Component radiograph used for the tomosynthetic reconstruction.

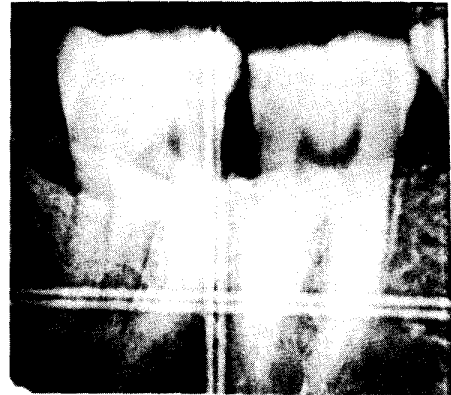


Fig. 5 Tomosynthetic reconstruction of a frontal slice on the lingual side of the dentition.

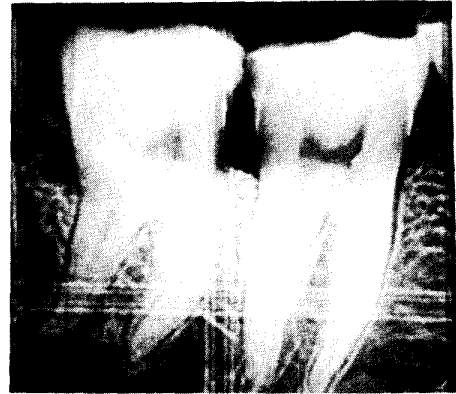


Fig. 6 Tomosynthetic reconstruction of a frontal slice through the center of the dentition.

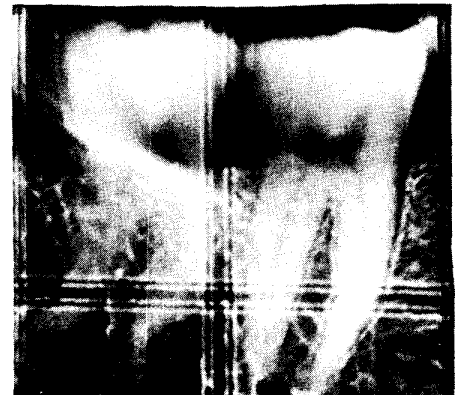


Fig. 7 Tomosynthetic reconstruction of a frontal slice on the buccal side of the dentition.