

# ASSOCIATION FOR ACADEMIC SURGERY, 2008

## Preoperative Thyroid Ultrasound In All Patients Undergoing Parathyroidectomy?<sup>1</sup>

Jeremy D. Gates, M.D.,\* Linda C. Benavides, M.D.,\* Craig D. Shriver, M.D.,† George E. Peoples, M.D.,\*‡ and Alexander Stojadinovic, M.D.‡<sup>2</sup>

\*Department of Surgery, General Surgery Service, Brooke Army Medical Center, Ft. Sam Houston, Texas;

†General Surgery Service, Walter Reed Army Medical Center, Washington, DC; and

‡Cancer Vaccine Development Program, United States Military Cancer Institute, Department of Surgery, Uniformed Services, University of the Health Sciences, Bethesda, Maryland

Submitted for publication February 6, 2008

**Background.** Coexisting thyroid nodules are the most common cause of false positive localization by radioscintigraphy in the preoperative evaluation for MIPS in patients with primary hyperparathyroidism (pHPT). This false positive finding can prompt full neck exploration in the setting of an unanticipated and incompletely evaluated thyroid nodule. Therefore, we are studying prospectively the routine use of preoperative thyroid US in patients with pHPT to determine the prevalence of concurrent thyroid disease and to assess how frequently this added information could alter the surgical plan.

**Materials and Methods.** Twenty-four patients with biochemically confirmed pHPT were evaluated with thyroid US after localizing <sup>99m</sup>Tc-sestamibi scintigraphy prior to parathyroid operation.

**Results.** Of the 24 patients, 38% ( $n = 9$ ) had their operations altered from a planned MIPS or four-gland exploration due to coexisting thyroid nodule(s). Of these, 33% ( $n = 3$ ) had underlying thyroid malignancy (all papillary thyroid cancer) requiring thyroidectomy in addition to parathyroidectomy. All but one patient had parathyroid adenoma as the cause of pHPT.

**Conclusion.** The routine use of preoperative thyroid US in patients with pHPT undergoing parathyroid surgery may aid in the timely diagnosis and treatment of coexisting thyroid disease. This added information secured before operation may avoid

difficult intraoperative decision dilemmas and prevent the increased morbidity associated with a second neck exploration. A large scale prospective study is ongoing. Published by Elsevier Inc.

**Key Words:** hyperparathyroidism; sestamibi; ultrasound; thyroid; disease.

### INTRODUCTION

Primary hyperparathyroidism (pHPT) is a common endocrine disorder with an incidence of 1 in 1000 and a peak during the fifth and sixth decade of life [1]. Symptomatic patients and those without symptoms meeting established guidelines for the 2002 NIH Consensus Development Panel for asymptomatic primary hyperparathyroidism (pHPT) are candidates for parathyroid surgery [2]. The etiology of pHPT is a solitary adenoma secreting excessive parathyroid hormone (PTH) in 80% of cases, multi-gland disease in nearly 20%, and parathyroid carcinoma in a minority (0.5%) of patients. Surgical treatment options for pHPT include standard four-gland exploration, minimally invasive parathyroid surgery (MIPS), or endoscopic parathyroidectomy [3, 4].

Preoperative localization of parathyroid adenomas with <sup>99m</sup>Tc-sestamibi scintigraphy or other localizing techniques is a requirement for MIPS, although it is not essential when standard neck exploration is planned. The use of surgeon-conducted ultrasound prior to planned parathyroidectomy is considered to be an accurate and cost effective diagnostic tool for

<sup>1</sup>This work was presented at the 2008 Academic Surgical Congress, February 13, 2008, Huntington Beach, CA.

<sup>2</sup>To whom correspondence and reprint requests should be addressed at Department of Surgery, General Surgery Service, Walter Reed Army Medical Center, Washington, DC, USA. E-mail: alexander.stojadinovic@amedd.army.mil.

the localization of parathyroid adenomas. Although some authors indicate that surgeon-performed ultrasound may be the only localization test needed prior to surgery, parathyroid ultrasound remains an imperfect diagnostic test, as it is highly operator-dependent. Thyroid ultrasound prior to planned parathyroidectomy to search for concomitant disease is not considered part of standard of practice guidelines in endocrine surgery, although it is practiced by some surgeons [5].

Observational studies have documented the frequent association of thyroid disease and hyperparathyroidism emphasizing the need for clinical awareness of this significant finding, one that may influence operative decision-making. Krause *et al.* reported an 8% prevalence of differentiated thyroid cancer in a retrospective study of patients explored for pHPT that also underwent simultaneous thyroid resection [6]. Only one of the nine patients with thyroid malignancy in that study had thyroid cancer suspected on the basis of intraoperative findings, including intraoperative frozen section. Strichartz and Giuliano conducted a retrospective review of 308 patients who underwent operation for hyperparathyroidism [7]. Fifty-two (17%) patients had grossly apparent thyroid abnormalities, and 11 (4% of total) of these had differentiated thyroid cancer. In Kossem's study of 51 consecutive patients with pHPT, 43 (84%) were found to have co-existing thyroid pathology preoperatively, and 9 (18%) patients were diagnosed with thyroid cancer [8].

The frequent finding of thyroid abnormalities in patients undergoing formal neck exploration for hyperparathyroidism established the basis for recommending careful examination of the entire thyroid gland at time of operation. With the increasing use of  $^{99m}\text{Tc}$ -sestamibi scintigraphy prior to minimally invasive parathyroidectomy and intraoperative quick parathyroid hormone assay, the ability to adequately assess the thyroid gland at time of operation is diminished. This makes missed or delayed diagnosis of thyroid disease increasingly likely. The combined operative management of simultaneous thyroid and parathyroid disease is prudent given its demonstrated safety, its avoidance of the increased operative morbidity of a second neck exploration [7, 9, 10, 11]. This may be important in patients with unanticipated thyroid malignancy that can be treated safely at the time of initial operation for hyperparathyroidism, avoiding the risk and expense of neck re-exploration at a later time when the malignancy is clinically apparent and possibly more locally advanced.

A prospective single-arm study is under way in patients undergoing operation for pHPT to determine the prevalence of concomitant thyroid disease detected by preoperative thyroid ultrasound. This study further examines the clinical impact of preoperative thyroid ultrasound findings on operative planning.

## MATERIAL AND METHODS

### Patient Characteristics and Clinical Protocol

The study was approved by the Institutional Review Board of Walter Reed Army Medical Center (WRAMC), Washington, DC. All patients had biochemically confirmed pHPT. Preoperative imaging included  $^{99m}\text{Tc}$ -sestamibi scintigraphy and ultrasound of the neck. Patients who were unable to consent, had previously undergone thyroid or parathyroid operation, had medullary thyroid carcinoma and hyperparathyroidism, or were suspected of having multiple endocrine neoplasm syndrome were excluded. All study participants provided informed consent prior to enrollment in the trial.

### Overall Study Design

Patients underwent preoperative imaging as specified above. Operative planning was developed based on clinical and radiological findings. The number and type of thyroid nodules was determined based on the preoperative ultrasound. A change in standard treatment included patients having partial or complete resections of the thyroid gland because the patients would have undergone MIPS or four-gland exploration alone if not for the results of the preoperative ultrasound.

### Statistical Analysis

Descriptive statistics were obtained utilizing established methods. Study sample means are presented with standard deviations (mean  $\pm$  SD).

## RESULTS

### Demographics and Preoperative Evaluation

There were 24 patients enrolled in the study to date, six males and 18 females with mean age of  $53.2 \pm 14.6$  (median: 50) y. Two patients reported prior history of neck radiation, however, did not require thyroidectomy. A family history of thyroid cancer was identified in one patient who had multinodular goiter (MNG) and underwent a total thyroidectomy for what later proved to be papillary thyroid cancer (PTC; Table 1).

Preoperative laboratory evaluation confirmed hypercalcemia (mean:  $10.9 \pm 0.7$  mg/dL), elevated parathyroid hormone (mean:  $112.7 \pm 33.7$  pg/mL) and Cl:Phosphate ratio (mean:  $36.0 \pm 6.0$ ) consistent with pHPT. All 24 patients had pHPT confirmed biochemically (Table 1).

Each patient underwent preoperative  $^{99m}\text{Tc}$ -sestamibi scintigraphy for preoperative localization. Sestamibi identified parathyroid abnormalities in 83% ( $n = 20$ ) of patients suggesting a single parathyroid adenoma in 95% ( $n = 19$ ) and a double parathyroid adenoma in 5% ( $n = 1$ ), with the remaining four patients having a non-localizing study. Minimally invasive parathyroid surgery was planned in 16 patients and standard neck exploration in eight patients. Table 2 demonstrates the reasons for eight patients undergoing a planned neck exploration despite presumably localized tumors on preoperative  $^{99m}\text{Tc}$ -methoxyisobutyl isonitrile (MIBI) scans.

**TABLE 1**  
**Patient Demographics With Preoperative Laboratory and Radiographic Results**

Demographics	Patients (n = 24)
Age; mean ± SD (y)	53.2 ± 14.6
Gender (female:male)	18:6
Race (White:African American)	18:6
Prior neck radiation	2
Family history of thyroid cancer	1
Preop lab test (n)	Mean ± SD
Serum calcium, mg/dL	10.9 ± 0.7
PTH, pg/mL	112.7 ± 33.7
Serum chloride:phosphate ratio	36.0 ± 6.0
Urine calcium, mg/24 h	333.2 ± 154.4
99m-technetium sestamibi results	Patients (n = 24)
Localized parathyroid abnormality	20
No visualized parathyroid	4
Indication for operation	Patients (n = 24)
Suspected single adenoma	19
Suspected double adenoma	1
Suspected parathyroid hyperplasia	4
Planned operation	Patients (n = 24)
MIPS	16
Four-gland exploration	8

**Operative Management**

Extent of operation (MIPS *versus* neck exploration) was determined by the attending surgeon based upon clinical findings and <sup>99m</sup>Tc-sestamibi scintigraphy. Patients were then prospectively evaluated prior to planned operation with thyroid ultrasound, and 67% (n = 16) were found to have coexisting thyroid abnormalities. Consideration of these abnormalities led to a change in planned operation in 38% of patients (n = 9; Figs. 1 and 2). Surgical decision-making in these

nine patients was influenced by family history, size, and multiplicity of thyroid nodules, preoperative FNA cytology (indeterminate and malignant nodules), and suspicious sonographic findings, including microcalcifications and increased vascularity within thyroid nodules.

**Pathologic Assessment**

Twenty-one (88%) patients had histologically confirmed solitary adenomas, including one intrathyroidic parathyroid adenoma. Two (8%) patients had double adenomas, and one (4%) had parathyroid hyperplasia as the etiology of pHPT. Among the nine patients who underwent either thyroid lobectomy/isthmusectomy (n = 5) or total thyroidectomy (n = 4), three (33%) had papillary thyroid carcinoma, five had benign adenomatoid nodules, and one was found to have an intrathyroidal parathyroid adenoma (Figs. 1 and 2).

**Evaluation of Changed Operations**

Thyroid abnormalities identified during preoperative assessment contributed to changes in the surgical plan in nine (38%) patients. Table 2 summarizes the preoperative findings, extent of operation, and final surgical pathology in these patients.

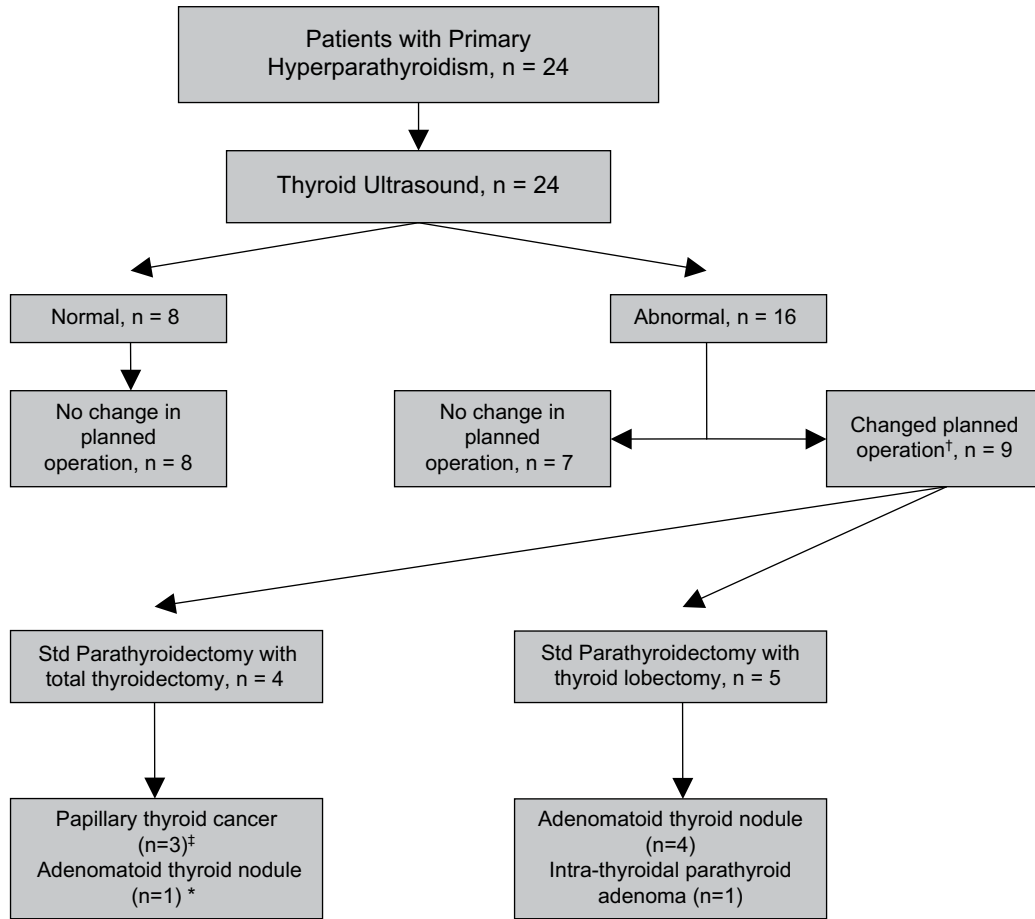
The first patient had a cytologically malignant 0.8 cm thyroid nodule ipsilateral to a localized parathyroid adenoma and underwent total thyroidectomy. Final pathology was benign. The second patient with two thyroid nodules ipsilateral to a localized parathyroid adenoma requested diagnostic thyroid lobectomy/isthmusectomy due to concerns of underlying malignancy. The third patient with multiple thyroid

**TABLE 2**  
**Comparison of Thyroid Ultrasound Reports to FNA and Pathologic Findings in Patients Who Underwent a Change in Their Planned Operations**

Preoperative location of PT adenoma	Thyroid ultrasound results	FNA	PT + thyroid operation	Thyroid pathology
LLP	0.8 cm: L Mid	PTC	Std + Total	Adenomatoid nodule
LLP + RLP	0.8cm: L Mid and 0.4 cm: LLP	—	Std + Lobe	Adenomatoid nodule
LLP	Two <1 cm: RLP	Benign	Std + Total	PTMC
RLP	1.9 cm: RLP	Indeterminate	Std + Lobe	Intra-thyroidal PT adenoma
LLP	0.4 cm: LUP and 0.7cm: RLP	—	Std + Lobe	Adenomatoid nodule
LLP	3.6cm: LLP	Indeterminate	Std + Total	PTMC (multi-focal)
LLP	1.4 cm: L Mid and 1.3 cm: LLP	Benign	Std + Lobe	Adenomatoid nodule
RLP	4.9 cm: RLP and 0.7 cm: isthmus	Benign	Std + Lobe	Adenomatoid nodule
PT not visualized preop	0.6 cm: Isthmus and Two 0.4 cm: right	Benign	Std + Total	PTMC (multi-focal)*

L: left; R: right; Mid: middle; LLP: left lower pole; RLP: right lower pole; LUP: left upper pole; PTC: papillary thyroid carcinoma; Std: standard parathyroidectomy (four-gland exploration); Total: total thyroidectomy; Lobe: thyroid lobectomy/isthmusectomy; PTMC: papillary thyroid microcarcinoma (<1 cm).

\*Patient with a family history of thyroid cancer.



†Thyroid US altered planned operation in 38% (9/24) of patients

‡PTC identified in 33% of operations modified due to thyroid US results

\* Pre-op FNA of nodule suggest PTC; however frozen section found no PTC. Final pathology: adenomatoid thyroid nodule; no evidence of malignancy.

**FIG. 1.** Evaluation of patients with pHPT by thyroid ultrasound and subsequent management based upon results.

nodules contralateral to a  $^{99m}\text{Tc}$ -sestamibi-concentrating parathyroid adenoma elected to undergo a total thyroidectomy in view of her significant family history for thyroid cancer; she was found to have papillary thyroid microcarcinoma (PTMC: <1 cm). One patient had a dominant 1.9 cm cytologically indeterminate thyroid nodule ipsilateral to a localized parathyroid adenoma prompting diagnostic thyroid lobectomy. Intraoperative frozen section confirmed an intrathyroidal parathyroid adenoma. This adenoma was the missing ipsilateral inferior parathyroid gland at time of exploration.

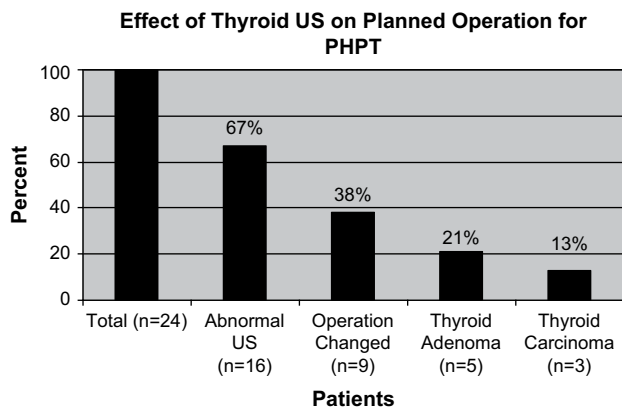
The fifth patient with localizing parathyroid adenoma had two thyroid nodules, one in each lobe; she requested diagnostic lobectomy, despite having a sub-centimeter, nonsuspicious nodule, which proved to be benign. The sixth patient had a large, solitary, solid, indeterminate thyroid nodule ipsilateral to a  $^{99m}\text{Tc}$ -sestamibi-concentrating parathyroid adenoma. Total thyroidectomy in conjunction with four-gland para-

thyroid exploration was completed. Pathologic evaluation found the indeterminate nodule to be benign, surrounded by multifocal PTMC. Two other patients had thyroid nodules (1.4 cm and 4.9 cm) ipsilateral to localizing parathyroid adenomas and elected to undergo lobectomy, despite benign cytology. Both proved to be adenomatoid thyroid nodules.

The last patient with a nonlocalizing parathyroid adenoma on  $^{99m}\text{Tc}$ -sestamibi in the setting of MNG underwent total thyroidectomy concurrently with the four-gland exploration. Final pathology demonstrated multifocal PTMC.

## DISCUSSION

The purpose of this prospective single-arm study was to determine the prevalence of concomitant thyroid disease detected by preoperative thyroid ultrasound in patients undergoing operation for pHPT and to



\*One of the nine patients had an intra-thyroidal parathyroid adenoma

**FIG. 2.** Comparison of thyroid ultrasound reports, change in planned operations, and pathologic findings to total patients enrolled in study.

examine the effect of these findings on operative planning and decision making. In 24 patients scheduled to undergo surgical treatment of pHPT, preoperative thyroid ultrasound altered the planned operative management in 38% ( $n = 9$ ). When this subset of patients was examined closely, 33% ( $n = 3$ ) had differentiated thyroid carcinoma. This suggests that preoperative thyroid ultrasound in patients with pHPT scheduled for parathyroid surgery may be useful, given the high prevalence of coexisting thyroid pathology. Although utilization of preoperative thyroid ultrasound in these patients could eliminate the operative morbidity of a second operation for unanticipated thyroid disease, surgical judgment to avoid over-treatment is imperative.

Despite the high prevalence of nodular disease of the thyroid in the setting of hyperparathyroidism, Lever *et al.* found that the rate of grossly apparent or macroscopic thyroid lesions coexistent with hyperparathyroidism was no different from that identified in autopsy controls (54% versus 46%); however, the rate of macroscopic nonmedullary thyroid cancer was significantly higher in the hyperparathyroid group (5.6% versus 0.0%,  $P < 0.001$ ) [12]. The association of medullary thyroid carcinoma and hyperparathyroidism as part of sporadic and hereditary endocrine syndromes is well established. However, the coexistence of nonmedullary thyroid cancer and hyperparathyroidism is often neglected. A recent review of published studies has reported the coexistence of nonmedullary thyroid cancer in ~3.0% (range 2.4% to 7.0%) of patients operated on for pHPT [13]. Similar to the findings of the current study, the majority of these are papillary thyroid microcarcinoma. Studies are lacking at the present time, however, to define the value of intervention early in the natural history of differentiated thyroid carcinoma.

These data suggest that a critical aspect of the recent transition from the traditional bilateral neck

exploration to minimally invasive parathyroid surgery (MIPS) preventing intraoperative assessment of the thyroid gland, is the awareness that coexistent thyroid pathology may be overlooked. This is a matter of concern in an era of MIPS for hyperparathyroidism, now a favored approach for patients with sporadic pHPT [14,15]. The ability to perform minimally invasive parathyroid resection depends heavily on patient selection, and the ability of  $^{99m}\text{Tc}$ -sestamibi scintigraphy to localize the parathyroid adenoma prior to operation. This minimally invasive approach would not be considered in a patient with a history of head or neck irradiation or family history of thyroid cancer, and certainly not in the absence of a localizable parathyroid abnormality on preoperative imaging studies.

Timely diagnosis and treatment of concurrent thyroid disease is imperative for curative resection of thyroid malignancy as well as avoidance of the increased morbidity and cost associated with neck re-exploration. The inability to exclude coexistent thyroid pathology strictly on the basis of absence of palpable thyroid abnormality on clinical examination makes preoperative imaging of the thyroid gland with or without selective FNA of detected thyroid abnormalities prior to parathyroidectomy justified [11, 14, 16]. However, the addition of preoperative imaging has the attendant risk of unnecessary intervention for low-risk thyroid abnormalities, and necessitates careful decision making, which balances cost- and morbidity avoidance of neck re-exploration, on one hand, and over-treatment on the other.

A number of clinical, cytological, and imaging factors must be considered when surgical treatment of thyroid nodules is contemplated. Indications for thyroidectomy include: a symptomatic thyroid nodule or one in a patient with predisposing family history of thyroid cancer; an enlarging nodule on suppressive therapy; a solitary nodule in a patient with previous radiation to the head and neck region; solid nodules > 1.0–1.5 cm with solid elements or suspicious sonographic findings (microcalcifications, increased vascularity); solitary nodules with indeterminate, suspicious, or malignant cytological findings.

Given the increased risk of malignancy in thyroid incidentalomas detected by  $^{18}\text{F}$ FDG-PET or sestamibi scan, fine needle aspiration cytology is indicated and consideration of thyroidectomy made under these circumstances when diagnostic uncertainty regarding malignancy in a thyroid nodule after completion of diagnostic evaluation persists. As found in the present study, consideration of patient preference (resection over continued follow-up, particularly in a mobile military population where frequent surveillance may not be achieved in remote duty stations), and reliability for adherence to recommended follow-up are important considerations in surgical decision making.

The threshold for operative management of thyroid disease, which is based upon established risk factors (family history, radiation exposure), nodule size, number, FNA cytology results, and suspicious US features in patients without parathyroid disease (as indicated above), may be lowered in patients with pHPT when the parathyroid operation requires a four-gland exploration or the MIPS is planned ipsilateral to a thyroid abnormality. A thyroid gland with a solitary nodule that is <1 cm might be followed with serial ultrasound examinations in a reliable, low-risk patient who is not undergoing neck surgery [17]. However, consideration should be given to obtaining a definitive diagnosis of the thyroid pathology in conjunction with planned parathyroidectomy in a patient undergoing resection of an abnormal parathyroid gland(s) ipsilateral to a recently discovered thyroid nodule. The recommendation for subcentimeter otherwise nonsuspicious contralateral thyroid nodules is surveillance, and should be emphasized during preoperative counseling.

This study highlights some of the many permutations of thyroid disease encountered in patients scheduled for parathyroidectomy, which might have been managed nonoperatively had the clinical dilemma been thyroid disease alone. Because the parathyroid resection, regardless of operation performed, will consist of dissection in proximity to the recurrent laryngeal nerve, a more aggressive surgical approach to the thyroid gland at initial operation may be justified to avoid a reoperation and its associated functionally limiting operative morbidity. This however requires careful consideration of clinical risk factors for malignancy and all preoperative testing results (US, FNA, scintigraphy). What's more, it necessitates surgical judgment as well as patient education and counseling, as the findings of thyroid ultrasound may raise unfounded concerns for malignancy on the part of a patient with pHPT and a thyroid nodule(s) who thereby requests perhaps unnecessary diagnostic thyroidectomy.

Our study reinforces what has already been demonstrated in patients with pHPT; concomitant thyroid disease is not an infrequent occurrence and preoperative thyroid ultrasound is useful for identifying thyroid disease [6, 7, 11, 14, 18]. Others have also shown that the use of ultrasound in conjunction with MIPS is not a cost prohibitive endeavor [19]. With these points in mind, the debate about the nature and extent of treatment for isolated papillary thyroid microcarcinoma takes on a different perspective when discussed in combination with pHPT requiring surgical treatment.

In line with national endocrine disease treatment center practice patterns, our adoption of minimally invasive surgery for pHPT attributable to a localizing adenoma precludes exploration of the entire neck and careful examination of the thyroid gland. As such,

timely diagnosis and treatment of the frequently encountered coexisting thyroid disease may be advantageous, particularly considering the increased morbidity associated with a second neck exploration.

## CONCLUSIONS

The routine use of thyroid ultrasound prior to planned operation in patients with primary hyperparathyroidism may aid in the timely diagnosis and treatment of coexisting thyroid disease. Diagnostic information provided by the thyroid ultrasound may support surgical treatment decisions by avoiding intraoperative dilemmas, as well as preventing the increased morbidity associated with neck re-exploration.

The primary aim of this study was to determine the prevalence of concomitant thyroid disease detected by preoperative thyroid ultrasound in patients undergoing operation for pHPT and to examine the effect of these findings on operative planning. The effect demonstrated in this preliminary study is that thyroid ultrasound may support changes in surgical decision-making. The threshold for addressing the thyroid surgically in the setting of already conducting a neck operation for pHPT is lowered with the intent to avoid future operative morbidity and to avoid overlooking thyroid malignancy. As all the patients in this series had small papillary thyroid cancers of uncertain clinical significance, the findings of this study emphasize the importance of careful judgment to avoid over-treatment. A large scale prospective study is on-going.

## ACKNOWLEDGMENTS

The authors acknowledge support for this work by the United States Military Cancer Institute, Department of Surgery, Uniformed Services, University of the Health Sciences, and the Department of Clinical Investigation at Walter Reed Army Medical Center.

The opinions or assertions contained herein are the private views of the authors and are not to be construed as official or reflecting the views of the Department of the Army, the Department of the Navy, or the Department of Defense.

This work represents original research that has not been submitted elsewhere for publication.

## REFERENCES

1. Silverberg SJ, Bilezikian JP. Hyperparathyroidism. In: Becker KL, Ed. Principles and practice of endocrinology and metabolism. 3rd edition. Philadelphia: JB Lippincott, 2001:564.
2. Bilezikian JP, Potts JT, El-Hajj Fuleihan G. Summary statement from a workshop on asymptomatic primary hyperparathyroidism: A perspective for the 21st century. *J Clin Endocrinol Metab* 2002;87:5353.
3. Silverberg SJ, Bilezikian JP. Asymptomatic primary hyperparathyroidism: A medical perspective. *Surg Clin North Am* 2004; 84:787.
4. Suliburk J, Perrier N. Primary hyperparathyroidism. *Oncologist* 2007;12:644.

5. Kukora J, Zieger M, Clark O, et al. The American Association of Clinical Endocrinologists and the American Association of Endocrine Surgeons Position Statement on the Diagnosis and Management of Primary Hyperparathyroidism. *Endocr Pract* 2005; 11:49.
6. Krause UC, Friedric JH, Olbricht T. Association of primary hyperparathyroidism and non-medullary thyroid cancer. *Eur J Surg* 1996;162:685.
7. Strichartz SD, Giuliano AE. The operative management of coexisting thyroid and parathyroid disease. *Arch Surg* 1990; 125:1327.
8. Kosem M, Algun E, Kotan C. Coexistent thyroid pathologies and high rate of papillary cancer in patients with primary hyperparathyroidism: Controversies about minimal invasive parathyroid surgery. *Acta Chir Belg* 2004;104:568.
9. van der Schaar H, Mulder H. Lesions of the thyroid gland in patients with primary hyperparathyroidism. *Surg Gynecol Obstet* 1985;160:407.
10. Kairaluoma MV. Simultaneous thyroid operation in patients undergoing initial neck exploration for primary hyperparathyroidism. *Ann Chir Gynaecol* 1994;83:30.
11. Regal M, Paramo C, Luna Cano R. Coexistence of primary hyperparathyroidism and thyroid disease. *J Endocrinol Invest* 1999; 22:191.
12. Lever E, Refetoff S, Strauss F, et al. Coexisting thyroid and parathyroid disease—are they related? *Surgery* 1983; 94:893.
13. Leitha T, Staudenherz A. Concomitant hyperparathyroidism and non-medullary thyroid cancer, with a review of the literature. *Clin Nucl Med* 2003;28:113.
14. Bentram DJ, Angelos P, Talamonti MS. Is preoperative investigation of the thyroid justified in patients undergoing parathyroidectomy for hyperparathyroidism? *Thyroid* 2002;12: 1109.
15. Udelsman R, Donovan PI, Sokol LJ. One hundred consecutive minimally invasive parathyroid explorations. *Ann Surg* 2002; 232:331.
16. Sidhu S, Campbell P. Thyroid pathology associated with primary hyperparathyroidism. *Aust N Z J Surg* 2000;70:285.
17. Ito Y, Tomodo C, Uruno T. Papillary metrocarcinoma of the thyroid: How should it be treated? *World J Surg* 2004;28:1115.
18. Masatsugu T, Yamashita H, Noguchi S. Thyroid evaluation in patients with primary hyperparathyroidism. *Endocr J* 2005; 52:177.
19. Hollenbeak CS, Lendel I, Beus KS. The cost of screening for synchronous thyroid disease in patients presenting with primary hyperparathyroidism. *Arch Otolaryngol Head Neck Surg* 2007;133:1013.