

# Familial Immunodeficiency With Cutaneous Vasculitis, Myoclonus, and Cognitive Impairment

Beverly N. Hay,<sup>1</sup> Julie E. Martin,<sup>2</sup> Barbara Karp,<sup>3</sup> Joie Davis,<sup>1</sup> Dirk Darnell,<sup>2</sup> Beth Solomon,<sup>4</sup> Maria Turner,<sup>5</sup> Steven M. Holland,<sup>2</sup> and Jennifer M. Puck<sup>1\*</sup>

<sup>1</sup>National Human Genome Research Institute, National Institutes of Health, Bethesda, Maryland

<sup>2</sup>National Institute of Allergy and Infectious Diseases, National Institutes of Health, Bethesda, Maryland

<sup>3</sup>National Institute of Neurological Disorders and Stroke, National Institutes of Health, Bethesda, Maryland

<sup>4</sup>W.G. Magnuson Center, Rehabilitation Medicine Department, Speech Pathology Section,

National Institutes of Health, Bethesda, Maryland

<sup>5</sup>National Cancer Institute, National Institutes of Health, Bethesda, Maryland

**We report a family with five of six siblings (including identical male twins) with a novel constellation of immunologic and neurologic impairments. Affected subjects experienced severe dermatitis starting around 9 months of age, Stevens–Johnson syndrome in early childhood, and extreme elevations of IgE (9,400–43,000 IU/ml). The oldest sibling died at age 27 of respiratory failure following recurrent, severe pneumonias. All four surviving affected siblings have had chronic sinusitis or otitis, cutaneous vasculitis, and recurrent bacterial pneumonias leading to bronchiectasis. Neurologic features in all five siblings included oral motor deficits, dysarthria, low average IQ (70–80), and essential myoclonus. Four had documented ataxia and/or mild sensory loss with increased patellar but diminished ankle reflexes. The nonconsanguineous parents and one sibling had none of the above findings, consistent with autosomal recessive inheritance. This primary immunodeficiency with distinctive neurological impairments represents a new syndrome.**

Published 2003 Wiley-Liss, Inc.†

**KEY WORDS:** immunodeficiency; myoclonus; vasculitis

## INTRODUCTION

Recurrent infections, defined as >6 upper respiratory infections per year in children [Finocchi et al., 2002; Chatila, 2003], result from unclassified primary immune deficiencies in a small but significant proportion of patients. Even though laboratory abnormalities may be present, patients may not fit into a described clinical disorder. In patients with immune dysfunction, neurologic symptoms may arise secondary to autoimmunity, dysregulated inflammation, or infection of the central nervous system; however, primary neurologic disorders are uncommon. We describe a family whose affected members had recurrent respiratory and skin infections and elevated IgE levels. The presence of extremely elevated IgE levels and recurrent infections initially led to evaluation for hyper IgE syndrome (HIES or Job syndrome). However, affected members of this family had manifestations atypical for HIES: cutaneous vasculitis, hypocholesterolemia, and neurologic abnormalities including cognitive impairment, myoclonus, and dysarthria. This constellation of features represents a syndrome not previously identified.

## FAMILY HISTORY

The pedigree of this family is illustrated in Figure 1. Other than the affected individuals in generation III, no one had frequent infections, dermatitis, respiratory failure, vasculitis, or myoclonus. Patient III-2 and the nonconsanguineous parents of Irish, English, and American–Indian descent were determined to be unaffected by history and examination.

## CLINICAL REPORTS

The relevant immunologic and infectious features, neurologic features, and other abnormalities are summarized in Tables I, II, and III, respectively.

Beverly N. Hay and Julie E. Martin contributed equally to this study.

Beverly N. Hay's present address is Department of Pediatrics, University of Massachusetts Memorial Medical Center, Worcester, MA.

\*Correspondence to: Jennifer M. Puck, NHGRI/NIH, Building 49, Room 4A14, 49 Convent Drive, Bethesda, MD 20892. E-mail: jpuck@mail.nih.gov

Received 14 May 2003; Accepted 7 August 2003

DOI 10.1002/ajmg.a.20595

Published 2003 Wiley-Liss, Inc.

†This article is a US Government work and, as such, is in the public domain in the United States of America.

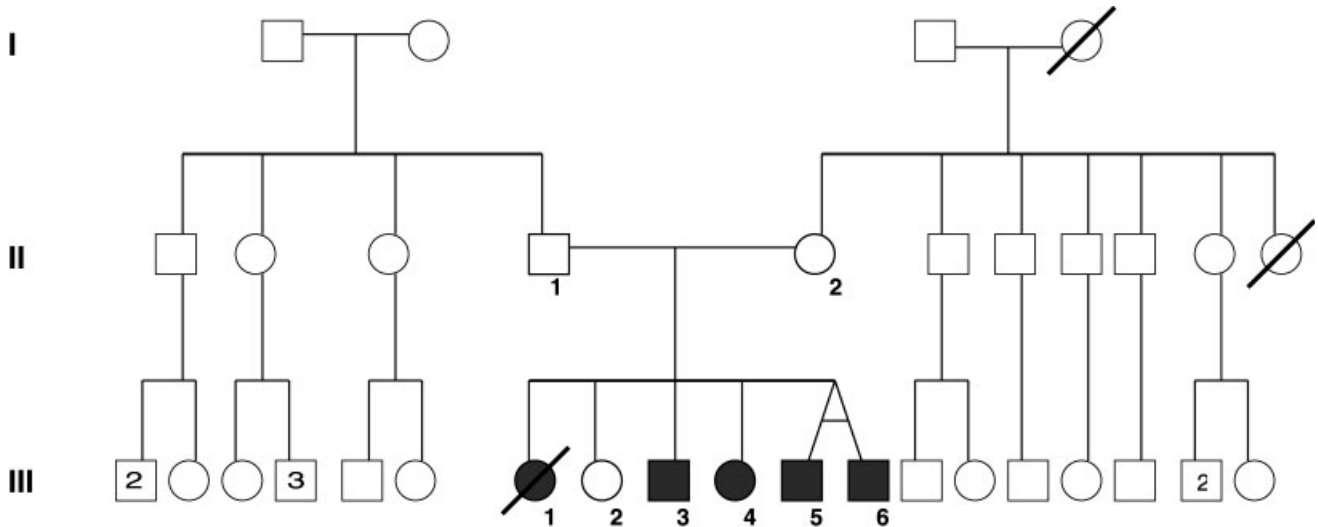


Fig. 1. Pedigree depicting affected members of the reported family (filled symbols).

### Patient III-1

The eldest daughter died at the age of 27, prior to our evaluation of the family. Her parents' report and hospital records indicate that she died of respiratory failure following more than 10 episodes of pneumonia. She had extensive bronchiectasis, pulmonary hypertension, cor pulmonale, and a supplemental oxygen requirement for the last 7 years of her life. Early in childhood she had Stevens–Johnson syndrome (SJS), severe and chronic dermatitis, chronic sinusitis, and otitis. An alpha-1-antitrypsin level was normal, and mutation testing for cystic fibrosis was negative. She had an elevated serum IgA at 597 mg/dl (normal range 51–375 mg/dl), with an increased IgG to 2,340 mg/dl (523–1,482 mg/dl; Table I). Serum IgE levels were not recorded. According to her parents, myoclonic jerks interfered with her ability to walk and could cause her to fall off a chair while seated; further neurologic findings were not documented. An autopsy was not performed.

### Patient III-3

This 26-year-old man had a history of SJS at 3 years of age, severe dermatitis, chronic otitis media and externa, conductive hearing loss, and cutaneous vasculitis of the lower extremities. Physical examination showed a narrowed right palpebral fissure, sagittal midline lingual cleft with prominent circumvallate papillae, high arched palate, and bilateral single palmar creases. He had bilateral thickened tympanic membranes and purulent auditory canal drainage. The skin of his lower extremities was darkened and had a red maculopapular, nonblanching rash with areas of purpura (Fig. 2A). Laboratory evaluation was remarkable for a serum IgE of 10,498 IU/ml (normal <150 IU/ml) with an elevated IgA at 594 mg/dl. Cultures of his auditory canals grew *Pseudomonas aeruginosa* and *Proteus mirabilis*. Computed tomography (CT) scans of his chest showed right middle lobe bronchiectasis, which was stable over

2 years of NIH follow-up. Radiologic examination showed spinal thoracic scoliosis of 30 degrees. Pulmonary function tests showed obstructive lung disease with an FEV-1 of 71% predicted. Echocardiogram showed mild tricuspid and mitral regurgitation. Rheumatologic evaluation for autoimmune causes of vasculitis was negative. Biopsy of his vasculitic skin lesions showed leukocytoclastic vasculitis (Fig. 2B). Neurologic evaluation revealed myoclonus, ataxia, and loss of light touch and temperature sensation in the right upper and lower extremities. Speech and cognitive evaluations showed mildly disarthric speech, generalized tongue weakness, and an IQ of 76. Magnetic resonance imaging (MRI) of the brain was normal. An electroencephalogram (EEG) demonstrated abnormal background slowing in the theta and alpha frequencies without epileptiform features, consistent with generalized cerebral dysfunction. Low total cholesterol (98 mg/dl) and triglycerides (43 mg/dl) were noted.

### Patient III-4

This 23-year-old woman was the most severely affected living sibling. She had suffered over 20 episodes of pneumonia with resulting respiratory compromise and clubbing of the digits. She had experienced SJS at 9 months of age, lower extremity vasculitis, chronic sinusitis, chronic otitis media and externa, and mild dermatitis. On physical examination she had enlarged papillae at the midline of the tongue, high arched palate, bilateral purulent auditory canal drainage, and skin changes consistent with atopic dermatitis. She had diffuse rales and rhonchi, with oxygen saturation levels as low as 88% on room air. Her lower extremities showed scattered purpura and genu valgum. Laboratory evaluation showed serum IgE of 35,544 IU/ml and IgA of 1,790 mg/dl. Cultures of her auditory canals grew *Pseudomonas aeruginosa* and *Proteus mirabilis*. *Pseudomonas aeruginosa* was also present in sputum, and at

TABLE I. Immune System and Sequelae of Infection

	Subject				
	III-1	III-3	III-4	III-5	III-6
<b>Clinical findings</b>					
Age at exam	(Died at 27 years)	24 years	21 years	19 years	19 years
Sex	Female	Male	Female	Male	Male
Dermatitis	Present	Severe	Mild	Severe	Severe
Vasculitis	No	Skin, hematuria	Skin	Skin	Skin, hematuria
Skin abscesses (number)	Yes (unknown)	No	No	No	Yes (5)
Number of X-ray proven pneumonias	>10	1	6	0	0
History of Stevens-Johnson syndrome	Yes	Yes	Yes	Yes	Yes
Parenchymal lung abnormalities	Bronchiectasis, emphysematous bullae, fibrosis	Bronchiectasis	Bronchiectasis, dilated bronchi with air/fluid levels, fibrosis, pleural-based nodular infiltrate	None	Bronchiectasis
Other	Cor pulmonale	Molluscum contagiosum	Clubbing	Chronic duodenitis, epididymal cysts	Parotid infections, esophageal stenosis
<b>Laboratory data</b>					
IgG [mg/dL] (523-1,482)	2,340	2,620	1,780	1,650	1,940
IgA [mg/dL] (51-375)	597	594	1,790	1,040	1,210
IgM [mg/dL] (37-200)	39	65	128	148	214
IgE [IU/ $\mu$ l] (0-90)	Unknown	10,498	35,544	43,047	36,931
Eosinophils/ $\mu$ l (<700/ $\mu$ l)	1,386	307	780	605	1,296
Pneumococcal titers	Unknown	Protective, 1.3-12.5 $\mu$ g/ml	Protective	Protective	Protective
Hepatitis serology (A/B/C)	Unknown	Negative	Anti-HCV+	Negative	

TABLE II. Neurologic Evaluation

	Subject					
	III-1	III-3	III-4	III-5	III-6	
Neurologic examination						
Myoclonus	Present	Present	Present	Present	Present	Present
Oculomotor abnormalities	Unknown	Absent	Present	Absent	Absent	Absent
Sensation	Unknown	Decreased on right side	Decreased	Decreased	Normal	Normal
Ankle reflexes	Unknown	Decreased	Decreased	Decreased	Normal	Normal
Ataxia	Unknown	Gait and limb	Absent	Gait and limb	Gait	Gait
Cognition (IQ)	Unknown	Low (76)	Low	Low (80)	Low (72)	Low (72)
Speech	Dysarthria	Mild dysarthria, weak tongue	Mild dysarthria, weak tongue	Poor articulation, unilateral tongue weakness, lip weakness	Flaccid dysarthria, weak tongue	Flaccid dysarthria, weak tongue
Other	Left arm tremor	Motor overflow posturing	Motor overflow posturing	Motor overflow posturing, unable to wrinkle brow	Normal	Normal
Brain MRI	Unknown	Normal	Left frontal lacunar infarct	Normal	Normal	Normal
EEG	Unknown	Diffuse background slowing	Diffuse background slowing, increased long latency cortical response, increased amplitude of somatosensory evoked potentials	Not done	Not done	Not done
Audiology	Unknown	Conductive loss	Mild conductive high frequency loss	Mild conductive high frequency loss	Right, mild high frequency sensorineural loss; left, moderate conductive loss	Conductive loss

one NIH visit she was treated for Group A *streptococcus* pneumonia. Immunophenotyping showed normal numbers and distribution of lymphocytes with the exception of CD8+ T cells (20.8% or 212 K/ml; normal >25.2% and >344, respectively). Pneumococcal titers assessed >1 year post-immunization were within protective range. Mutation studies for cystic fibrosis were negative, and an alpha-1-antitrypsin was normal. Chest CT showed extensive bronchiectasis with active inflammation and extensive scarring (Fig. 3). Pulmonary function showed a restrictive pattern (FEV-1, 47% of predicted; FVC, 47% of predicted; TLC, 72% of predicted). Electrocardiogram and echocardiogram were normal. Neurologic evaluation found mild conductive hearing loss, myoclonus, diminished vibratory perception in her feet, and decreased ankle tendon reflexes. She had mild dysarthria and generalized tongue weakness. MRI of the brain showed a single small lesion anterior to the left frontal horn consistent with an old infarct. Electrophysiological evaluation found giant somatosensory evoked potentials consistent with cortical myoclonus. Total serum cholesterol was 128 mg/dl, with a serum triglyceride level of 50 mg/dl.

### Patient III-5

At 9 months of age, this 19-year-old-male twin had had SJS. He continued to suffer from cutaneous vasculitis, dermatitis, and chronic otitis media and externa. Additionally, he had a history of chronic duodenitis and epididymal cysts. Physical examination was notable for a narrowed right palpebral fissure, median rhomboid glossitis with a central lingual fissure, high arched palate, bilateral clinodactyly of the 2nd and 5th fingers, and broad thumbs and great toes. His lower extremities showed diffuse purpura, genu valgum, and pes valgus. He had bilateral auditory canal drainage with positive cultures for *Pseudomonas aeruginosa* and *Stenotrophomonas maltophilia*. Multiple IgE measurements were >40,000 IU/ml with IgA elevated to 1,040 mg/dl (Table I). Chest CT and an echocardiogram were normal. He had conductive and sensorineural hearing loss, myoclonus, distal sensory loss, limb and gait ataxia, hypometric saccadic eye movements, poor vocal articulation with unilateral tongue weakness, impaired oral-motor function, and an IQ of 80. An MRI of the brain was normal. Total serum cholesterol was 113 mg/dl, with serum triglycerides of 67 mg/dl. A high-resolution peripheral blood karyotype analysis was normal (46,XY), and fluorescence in situ hybridization (FISH) detected no deletion of chromosome 22q11.

### Patient III-6

The second twin was shown to be genotypically identical to III-5 (AmpF/STR COfiler Kit, Applied Biosystems). He had experienced SJS within a month of his brother; he also had dermatitis, chronic otitis media and externa, lower extremity vasculitis, and chronic severe cervical adenopathy with benign plasmacytoid changes on biopsy. He had repeated episodes

TABLE III. Other Features of IVM

	III-1	III-3	III-4	III-5	III-6
<b>Clinical findings</b>					
Midline tongue anomaly	Unknown	Yes	Yes	Yes	No
Scoliosis (degrees of curvature)	Unknown	Yes (30)	Yes (26)	No	Yes (37)
Anomalies of the extremities	Unknown	Single palmar creases, broad nails	None	Broad thumbs, broad great toes	Broad great toes
<b>Laboratory data</b>					
Serum lipid profile [mg/dL]	Unknown				
Total cholesterol (100–200)		98	128	113	1,112
Triglycerides (10–140)		43	50	62	47
LDL (65–129)		49			63

of bacterial parotitis and esophageal stenosis that required dilatation. Physical examination was significant for a narrowed right palpebral fissure, prominent lips, high arched palate, long fingers with ulnar

deviation, long nail beds, and broad great toes. He had skin changes consistent with atopic dermatitis. At his initial NIH examination he had right parotid tenderness and swelling with cervical adenopathy. He had bilateral purulent auditory canal drainage with positive cultures for *Pseudomonas aeruginosa* and *Proteus mirabilis*. An aspirate culture of his right parotid grew *Staphylococcus aureus*. Serum IgE measurements were over 36,000 IU/ml with an elevated IgA of 1,210 mg/dl. Chest CT showed bronchiectasis of the right middle lobe. An echocardiogram showed normal findings. Neurologic findings included myoclonus, mild gait ataxia, and conductive hearing loss. Speech and cognitive evaluations found flaccid dysarthria with dysarticulation, generalized and severe tongue weakness, and an IQ of 72. Brain MRI was normal. His serum cholesterol was 112 mg/dl and serum triglyceride level was 47 mg/dl.

For all affected patients, growth parameters and craniofacial measurements were within normal ranges, and retained primary teeth and typical facial features of HIES were absent. Determinations of complement, copper and ceruloplasmin, urine organic acids, urine amino acids, and plasma amino acids were all normal. Antinuclear antibodies (ANA), anti-DNA, ENA, anti-neutrophil cytoplasmic antibodies (ANCA), and cryoglobulins were negative in the two affected family members tested. Rheumatoid factor was negative (<20) for Patient III-3 but present at 1:88 in Patient III-5. Alpha-1-antitrypsin results were normal in the two affected siblings tested. Patient serum was tested for antibodies to hepatitis A, B, and C viruses with only anti-HCV positive in Patient III-4. The unaffected parents and sibling were of normal intelligence and did not have frequent infections or any of the neurological, skeletal, lingual, or cutaneous findings seen in the affected siblings.

## DISCUSSION

The consistent juxtaposition of several unusual immunologic and neurologic abnormalities in these siblings represents a previously undescribed syndrome. We propose to name it immunodeficiency–vasculitis–myoclonus syndrome (IVM). Affected subjects have recurrent infections, markedly elevated IgE levels, and mildly elevated levels of IgG and IgA, atopic dermatitis, cutaneous vasculitis, and non-progressive neurologic dysfunction including cortical myoclonus, peripheral neuropathy, ataxia, dysarthria with tongue weakness,

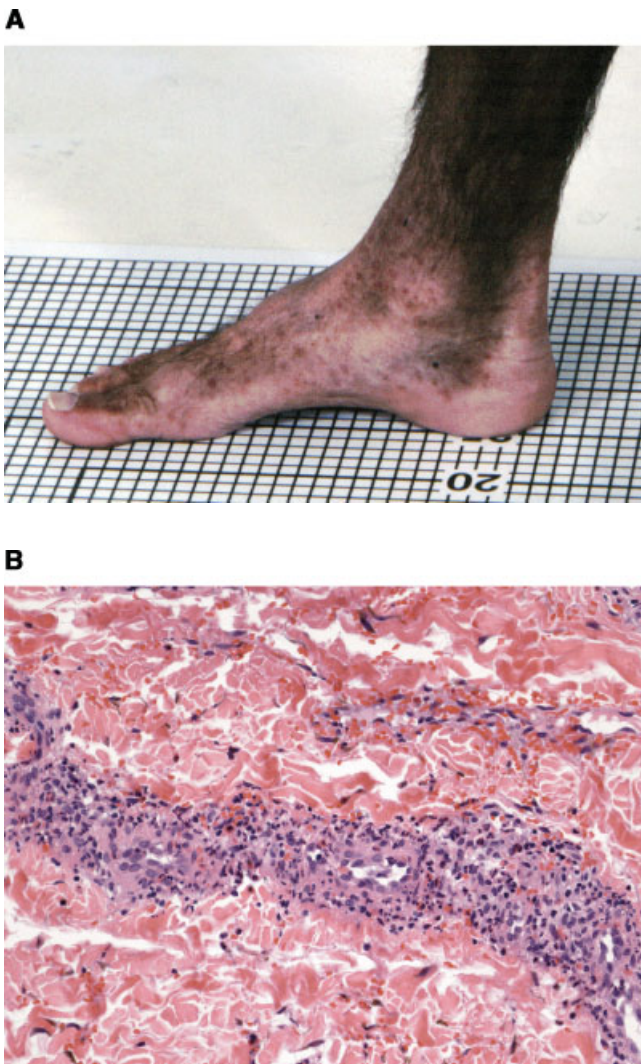

Fig. 2. **A:** Vasculitis on the lower leg of Patient III-3. **B:** Biopsy of the vasculitis from Patient III-3 demonstrating leukocytoclastic vasculitis with destruction of small vessel walls, extravasation of red cells, and infiltration of vessel walls by neutrophils, lymphocytes, eosinophils, nuclear dust and hemosiderin.

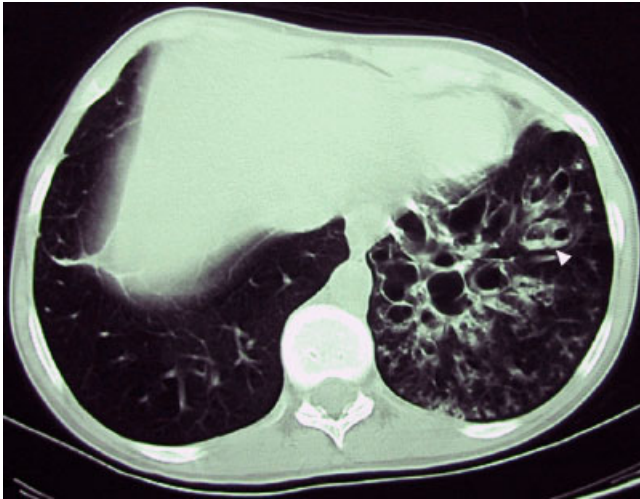


Fig. 3. Computed tomography (CT) of the chest from Patient III-4 demonstrating extensive bronchiectasis and air/fluid levels (arrow).

and cognitive impairment. No described syndromes unite these aspects of immunodeficiency and neurologic dysfunction.

This syndrome has features of several other immune disorders, including HIES, complement deficiency, combined variable immune deficiency (CVID), and autoimmunity. HIES (MIM no. 147060), first described by Davis et al. [1966] and Buckley et al. [1972], is a triad of cutaneous “cold abscesses,” cyst-forming pneumonias and extremely elevated serum IgE. It is now recognized as a multisystem disease with both immune and somatic manifestations that can be inherited as an autosomal dominant disorder with variable expressivity [Davis et al., 1966; Buckley et al., 1972; Borges et al., 1998; Grimbacher et al., 1999a]. Infections in HIES are most often due to *Staphylococcus aureus* and are remarkable for the paucity of signs of inflammation. Somatic manifestations of HIES include frequent fractures, osteopenia, hyperextensible joints, scoliosis, high arched palate, retained primary teeth, and characteristic facial features with increased nasal width. The family described here did not display typical features of HIES with the exception of high IgE levels, pneumonia, and scoliosis. Whether the elevated antibody levels in our patients are due to chronic antigen stimulation or other causes is not clear. An autosomal recessive variant of HIES has also been described without lung cysts or skeletal findings, but with viral infections and CNS vasculitis [Renner et al., 2003].

CVID (MIM no. 240500) typically involves recurrent sinopulmonary infections, bronchiectasis, and familial clustering in up to 20% of cases [Spickett, 2001]. However, the hallmark of CVID, low immunoglobulin levels, was absent in this family. Complement deficiencies may produce recurrent pneumonia and vasculitis, typically of small vessels. C3 deficiency (MIM no. 120700) presents early in life with recurrent, severe infections and vasculitic rashes in 25% of patients

[Sullivan and Winkelstein, 1999]. C4 deficiency (MIM no. 120810, 120820) may present with predominantly cutaneous features or as repeated bacterial infections. However, both C3 and C4 levels were normal in our patients.

Among the immunologic causes for vasculitis are the autoimmune disorders Churg–Strauss disease, an allergic angiitis and granulomatosis, and hypersensitivity vasculitides. Although the eosinophilia of Churg–Strauss disease was present in our patients, the skin biopsies demonstrated leukocytoclastic rather than granulomatous vasculitis. Hypersensitivity vasculitis involves the small vessels and most characteristically affects the skin, with leukocytoclasia. Hypersensitivity vasculitis may also be secondary to other diseases such as chronic active hepatitis, congenital deficiencies of complement components, systemic lupus erythematosus (associated with ANA), deficiency of alpha-1-antitrypsin, cryoglobulinemia, and Wegener’s granulomatosis (associated with ANCA) [Habif, 1996]. These conditions were ruled out in our family.

The neurologic signs shared by all the affected siblings included lifelong cognitive impairment, dysarthria with tongue weakness, and myoclonus. Mild sensory loss, diminished Achilles tendon reflexes, and mild gait ataxia with or without limb ataxia were found in three of the four siblings examined. The myoclonic jerks in all subjects were first noted in childhood and frequent, multifocal, and not stimulus-sensitive. The mild sensory loss and diminished reflexes were consistent with a mild peripheral neuropathy. Individual subjects also had additional isolated signs as shown in Table II. The neurologic disorder does not appear by history or serial examination to be progressive. This particular combination of neurologic signs does not localize to a single area of the nervous system nor resemble a recognized myoclonic syndrome.

Myoclonus is a movement disorder characterized by brief, shock-like muscle jerks. Cortical myoclonus, as found in this family, can arise as an isolated symptom (as in familial essential myoclonus), in conjunction with other neurologic signs (as in the myoclonic epilepsies), or secondary to a wide range of endocrine or metabolic abnormalities, neurologic insults, or brain injury [Goetz, 1999]. None of the siblings had epilepsy, hyperthyroidism, hyponatremia, or hypoglycemia, nor exposure to medications such as valproate, antidepressants, or stimulants. There was no renal or liver failure, brain tumor or history of brain trauma. Although Patient III-4 had a small lacunar stroke on MRI, scans in the other three were normal. Heavy metal screen, copper and ceruloplasmin, and plasma and urine amino acid and organic acid analyses were negative or normal. Enzymopathies (sialidoses, lipidoses, lysosomal storage diseases, Wilson disease), degenerative diseases (Parkinson disease, Huntington disease), and CNS infections (Creutzfeldt–Jacob, Whipple disease) have myoclonus along with other neurologic signs and a progressive course.

Cognitive impairment can be associated with cytogenetic abnormalities alone or in association with recognized syndromes. A patient with HIES plus retardation

and autism had a marker ring chromosome from an interstitial deletion of chromosome 4q [Grimbacher et al., 1999b]. Immune deficiency with cognitive impairment occurs in DiGeorge velocardiofacial syndrome caused by del 22q11 [Jawad et al., 2001]. A karyotypic and FISH analysis of peripheral blood from Patient III-4 showed no deletion of chromosome 22 or any other cytogenetically detectable chromosomal abnormality [Boeck et al., 1999, 2001].

Low cholesterol has been associated with malformation syndromes, cognitive impairment, and immune compromise. Hypocholesterolemia may be present in Smith–Lemli–Opitz syndrome (SLOS, MIM no. 270400) or Zellweger syndrome (MIM no. 214100). SLOS is an autosomal recessive condition with multiple malformations, mental retardation, and growth failure, due to reduced activity of 7-dehydrocholesterol reductase (DHCR7), the final enzyme in the cholesterol biosynthetic pathway. Patients with SLOS have low cholesterol and high concentrations of its direct precursor, 7-dehydrocholesterol, in plasma and tissues. Zellweger or cerebrohepatorenal syndrome is a peroxisome biogenesis disorder with craniofacial malformations, hypotonia and hepatomegaly. Both of these disorders are associated with severe mental retardation, seizures, early mortality, and physical characteristics not present in our family. Low cholesterol has also been reported to be associated with increased mortality in the elderly, some cancers [Song et al., 2000] and intracerebral hemorrhage [Segal et al., 1999]. Muldoon et al. [1997] found low lymphocyte and T cell numbers in men with total cholesterol levels of 151 mg/dl or lower. While the cholesterol levels in our patients were low, their lymphocyte counts were normal.

Early diagnosis and a comprehensive program of antibiotic prophylaxis and aggressive treatment of infections could help those affected with IVM to have a longer and healthier life. Identification of the molecular genetic basis in this novel syndrome would enhance understanding of pathways linking immunity and cognition.

#### ACKNOWLEDGMENTS

The authors thank members of the NIH Clinical Center who have helped evaluate patients and data and the family for their willingness to participate in our studies.

#### REFERENCES

- Boeck A, Gfatter R, Braun F, Fritz B. 1999. Pentasomy X and hyper IgE syndrome: Co-existence of two distinct genetic disorders. *Eur J Pediatr* 158:723–726.
- Boeck A, Kosan C, Ciznar P, Kunz J. 2001. Saethre–Chotzen syndrome and hyper IgE syndrome in a patient with a novel 11 bp deletion of the *TWIST* gene. *Am J Med Genet* 104:53–56.
- Borges WG, Hensley T, Carey JC, Petrak BA, Hill HR. 1998. The face of Job. *J Ped* 133:303–305.
- Buckley RH, Wray BB, Belmaker EZ. 1972. Extreme hyperimmunoglobulinemia E and undue susceptibility to infection. *Pediatrics* 49:59–70.
- Chatila TA. 2003. Undue susceptibility to infection. In: Rudolph CD, Rudolph AM, Hostetter MK, Lister G, Siegel NJ, editors. *Rudolph's pediatrics*, 21st edn. New York: McGraw-Hill. p 791.
- Davis DD, Schaller J, Wedgwood JR. 1966. Job syndrome. *Lancet* 1:1013–1015.
- Finocchi A, Angelini F, Chini L, Di Cesare S, Cancrini C, Rossi P, Mochese V. 2002. Evaluation of the relevance of humoral immunodeficiencies in a pediatric population affected by recurrent infections. *Pediatr Allergy Immunol* 13:443–447.
- Goetz CG, editor. 1999. *Textbook of Clinical Neurology*, 1st edn. Philadelphia: W. B. Saunders Company. pp 283, 673, 675–676, 744.
- Grimbacher B, Holland SM, Gallin JI, Greenberg F, Hill SC, Malech HL, Miller JA, O'Connell AC, Puck JM. 1999a. Hyper-IgE syndrome with recurrent infections—an autosomal dominant multisystem disorder. *NEJM* 340:692–702.
- Grimbacher B, Dutra AS, Holland SM, Fischer RE, Pao M, Gallin JI, Puck JM. 1999b. Analphoid marker chromosome in a patient with hyper-IgE syndrome, autism, and mild mental retardation. *Genet Med* 1:213–218.
- Habif TP. 1996. *Clinical dermatology*, 3rd edn. St. Louis: Mosby-Year Book, Inc. pp 577–582.
- Jawad AF, McDonald-McGinn DM, Zackai E, Sullivan KE. 2001. Immunologic features of chromosome 22q11.2 deletion syndrome (DiGeorge syndrome/velocardiofacial syndrome). *J Pediatr* 139:715–723.
- Muldoon MF, Marsland A, Flory JD, Rabin BS, Whiteside TL, Manuck SB. 1997. Immune system differences in men with hypo- or hypercholesterolemia. *Clin Immunol Immunopathol* 84:145–149.
- Renner ED, Puck JM, Holland SM, Schmitt M, Weiss M, Frosch M, Bergmann M, Davis J, Belohradsky BH, Grimbacher B. 2003. Autosomal recessive hyper-IgE syndrome: A distinct disease entity. *J Pediatr* (in press).
- Segal AZ, Chiu RI, Eggleston-Sexton PM, Beiser A, Greenberg SM. 1999. Low cholesterol as a risk factor for primary intracerebral hemorrhage: A case-control study. *Neuroepidemiology* 18:185–193.
- Song YM, Sung J, Kim JS. 2000. Which cholesterol level is related to the lowest mortality in a population with low mean cholesterol level: A 6.4 year follow-up study of 482,472 Korean men. *Am J Epidemiol* 151:739–747.
- Spickett GP. 2001. Current perspectives on common variable immunodeficiency. *Clin Exp All* 31:536–542.
- Sullivan KE, Winkelstein JA. 1999. Genetically determined deficiencies of the complement system. In: Ochs HD, Smith CIE, Puck JM, editors. *Primary immunodeficiency diseases*. New York: Oxford University Press. p 405.