

Weiss Marcin, Dolata Tomasz, Weiss Waldemar, Maksymiak Martyna, Kaluźny Krystian, Kaluźna Anna, Zukow Walery, Hagner-Derengowska Magdalena. Treatment of intraarticular displaced fractures of the calcaneus bone using nail blocked calcanaïl. *Journal of Education, Health and Sport*. 2018;8(4):338-345. eISSN 2391-8306. DOI <http://dx.doi.org/10.5281/zenodo.1226782>
<http://ojs.ukw.edu.pl/index.php/johs/article/view/5439>
<https://pbn.nauka.gov.pl/sedno-webapp/works/863609>

The journal has had 7 points in Ministry of Science and Higher Education parametric evaluation. Part b item 1223 (26/01/2017).

1223 Journal of Education, Health and Sport eissn 2391-8306 7

© The Authors 2018;

This article is published with open access at Licensee Open Journal Systems of Kazimierz Wielki University in Bydgoszcz, Poland

Open Access. This article is distributed under the terms of the Creative Commons Attribution Noncommercial License which permits any noncommercial use, distribution, and reproduction in any medium, provided the original author (s) and source are credited. This is an open access article licensed under the terms of the Creative Commons Attribution Non commercial license

(<http://creativecommons.org/licenses/by-nc/4.0/>) which permits unrestricted, non commercial use, distribution and reproduction in any medium, provided the work is properly cited.

This is an open access article licensed under the terms of the Creative Commons Attribution Non commercial License (<http://creativecommons.org/licenses/by-nc/4.0/>) which permits unrestricted, non commercial use, distribution and reproduction in any medium, provided the work is properly cited.

The authors declare that there is no conflict of interests regarding the publication of this paper.

Received: 05.03.2018. Revised: 10.03.2018. Accepted: 23.04.2018.

TREATMENT OF INTRAARTICULAR DISPLACED FRACTURES OF THE CALCANEUS BONE USING NAIL BLOCKED CALCANAİL

**Marcin Weiss¹, Tomasz Dolata¹, Waldemar Weiss¹, Martyna Maksymiak²,
Krystian Kaluźny³, Anna Kaluźna³, Walery Zukow⁴, Magdalena Hagner-Derengowska⁵**

- 1) **Ward of Orthopaedic and Traumatology with Center of Complex Treatment of Sports Injuries, Jan Biziel University Hospital No. 2 in Bydgoszcz**
- 2) **Jan Biziel University Hospital No. 2 in Bydgoszcz**
- 3) **Chair and Clinic of Rehabilitation, Faculty of Health Sciences, Nicolaus Copernicus University in Toruń, The Ludwik Rydygier Collegium Medicum in Bydgoszcz**
- 4) **Department of Spatial Management and Tourism, Faculty of Earth Sciences, Nicolaus Copernicus University in Toruń**
- 5) **Chair of Clinical Neuropsychology, Faculty of Health Sciences, Nicolaus Copernicus University in Toruń, The Ludwik Rydygier Collegium Medicum in Bydgoszcz**

Abstract:

The aim of this new technic in our hospital is to describe this method of treatment for displaced articular fractures of the calcaneus, which offered the following advantages: (a) the creation of a working channel that provides also a significant bone autograft, (b) the intrafocal reduction of the displaced articular surface, (c) the insertion of a locking nail that maintains the reduced articular surface at the right height, (d) the possibility to switch from

an ORIF to a reconstruction arthrodesis with the same approach and instrumentation in case of severely damaged posterior facet.

Key words: fractures; calcaneus bone

Introduction

The calcaneus is the most frequently injured tarsal bone, with calcaneal fractures meaning that 60% of the fractures affect the foot and about 1% to 2% of all fractures. 75% of calcaneal fractures have an intra-articular component. Many intra-articular fractures have important long-term consequences for patients. The treatment of displaced intra-articular calcaneal fractures is still a matter of debate. There are a lot of opinions on the management of these fractures, and there have been controversies regarding the methods of treatment. 20 years ago, surgery was considered inappropriate for these fractures, and conservative treatment techniques were preferred. However, patients and surgeons remained dissatisfied with the results, and some authors have promoted surgical intervention during the last 20 years. In the past, conservative treatment was advocated following the complications of surgery and the improved results with non-operative treatment. Starting from about 20 years ago, the unsatisfactory functional results after conservative treatment and routine computed tomography resulted in a reappraisal of the surgical approach. This change reflected the continuous dissatisfaction with the outcome of conservative treatment for these fractures, and the improvements in the surgical technique were accompanied by a reduction in complication rates. The recovery period is frequently prolonged, and a return to the pre-injury level of activity may not be reached due to pain, loss of motion, and the need for specialized footwear. However, clinical evidence supporting operative treatment for selected patient groups is limited, whereas long-term complications and adverse outcomes are still frequently documented. One of the adverse effects of the operative treatment is the damage to the soft tissues, such as flap necrosis with subsequent wound complications and sural nerve injury. To avoid these soft-tissue complications, several minimally invasive procedures have been introduced. The aim of this study was to assess the clinical, radiographic, and functional outcomes of patients, in whom displaced intra-articular calcaneal fractures were treated with a minimally invasive fixation with Calcanail system.

Material and method

The investigations that we were obliged to use for the patients who were included in our study were the following:

X-rays -Represents the most common and widely available diagnostic imaging technique that creates images of dense structures, like bone, so, they are particularly useful in showing fractures.

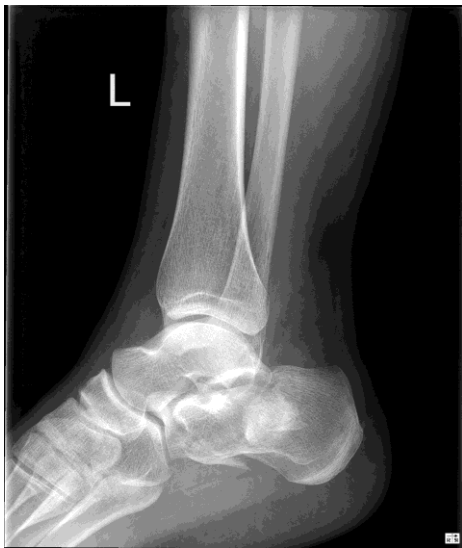

Figure 1: X- Ray lateral position

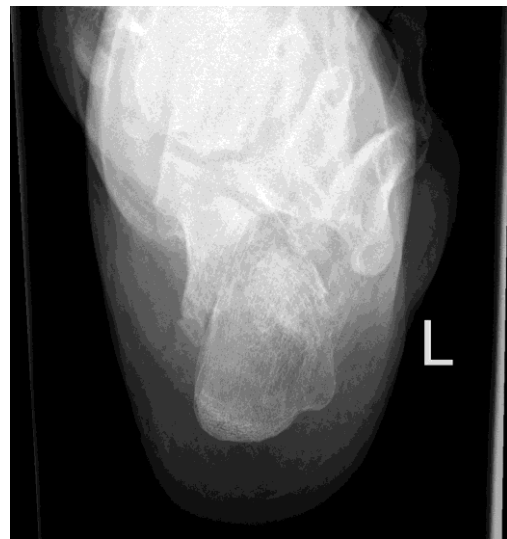

Figure 2: X-ray axial position of the calcaneus fracture

Computed tomography (CT) scan-After reviewing the X-rays, the surgeon should recommend a CT scan of the foot. This imaging tool combines X-rays with computer technology to produce a more detailed, cross-sectional image of the calcaneal body. It can provide the surgeon with valuable information about the severity of the fracture. Studying CT scans helps in planning the treatment.

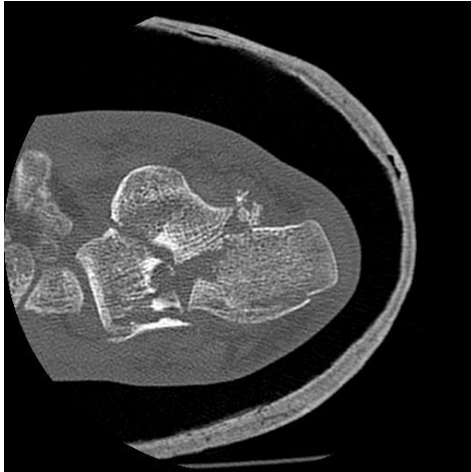

Figure 3: CT Scan

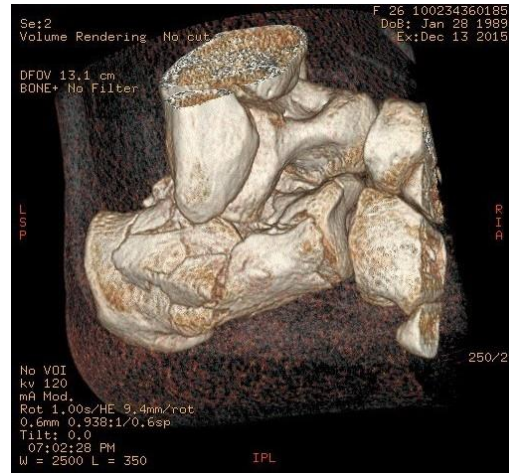


Figure 4: CT 3D Scan

A comprehensive physical examination must be undertaken for each patient. One should exercise care to avoid overlooking additional injuries of the musculoskeletal system. Some patients with a fracture of the calcaneus have a concomitant spinal injury.

A full history, including documentation of preexisting medical conditions such as diabetes or vascular disease, should not be unnecessarily delayed. The poor vascularisation of the back foot is also well known. The knowledge of the relevant anatomy is important, this way having a clear and comprehensive image of the injury. Thorough imaging allows a careful determination of the surgical approach and the planning of a staged procedure, if necessary.

Calcaneus fractures are still a delicate point regarding the indication for osteosynthesis. Knowing the skin's poor vascularisation of the back foot, the purpose of this study is to present the benefits of proper surgical options between an open and invasive osteosynthesis with anatomical reduction and internal fixation or minimally invasive approach with Calcanail system preserving the quality of the soft parts.

Calcanail system (Minimally -invasive technique: closed reconstruction of foot anatomy using a nail and cannulated screws;)

Through-the-heel approach should be used, using a hollow reamer to tunnel into the calcaneus. When used with a subtalar distractor, this method provides direct intrafocal access to the articular fragments.

This technique makes it possible to correct calcaneal tuberosity displacements and obtain good reduction of the joint for intra-articular fractures that are composed of large fragments, or to perform arthrodesis right away in cases of more complex intra-articular fractures.

This system have advantages like:

- Innovative reduction technique that reduces surgical trauma and the risk of complications;
- Large bone plug removed when work chamber is created which is available for use as autograft;
- Intrafocal reduction of displaced intra-articular fragments is easier when using a Caspar-type subtalar dis- tractor;
- Placement of locking nail under joint surface that is held at the correct height;
- Placement of bone graft into implant windows helps with bone union.

Cases

After soft tissue swelling had decreased, surgery was performed. Patients were usually placed in a lateral position, but a prone position was also used, especially in cases of bilateral fractures. The surgical technique was detailed in a previous publication [14]. Briefly, the technique is based on reduction of the depressed articular surface via a channel created through the tuberosity. By lowering the tuberosity, the talocalcaneal distractor facilitates reduction of the depressed articular surface and automatically corrects tuberosity varus. Once reduction is achieved, an intramedullary nail is introduced through the same channel and locked with two screws. The fracture nail is available in three lengths: 45, 50 and 55 mm; and one diameter: 10 mm. The fusion nail is available in three lengths: 75, 80 and 85 mm; and one diameter: 12 mm.

Our patients were: 3 females and 2 males with age 27-46 years.

Trauma resulted from a simple fall from a variable height , a fall on the stairs , fall from a scaffold or ladder. Among the fractures were type IA, 11 type IB, 27 type IIA and 19 type IIB; Mean preoperative Böhler angle was 6.7° (range -20° to $+40^\circ$) when mean contralateral was 31° . Most patients were operated in a lateral position. A tourniquet was routinely used; procedure time was <1 h in all cases. Most fractures were treated with reduction and fixation with a locking fracture nail. (Fig. 5, Fig. 6, Fig. 7)

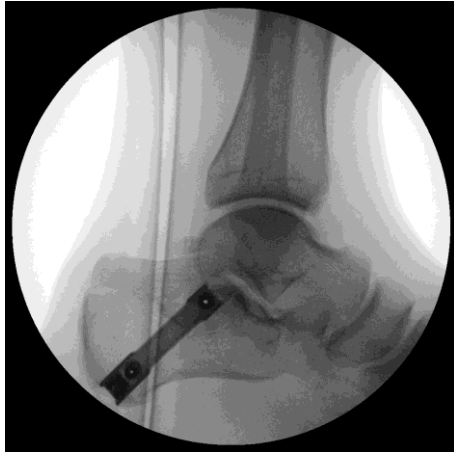

Figure 5

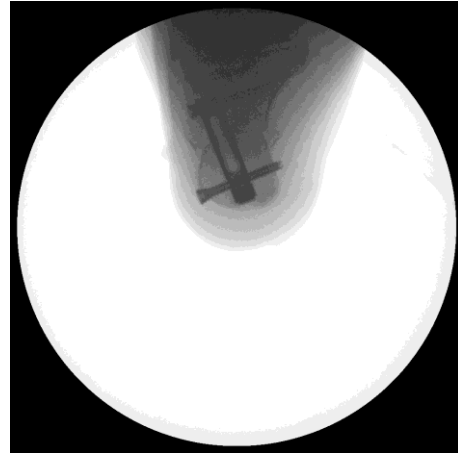

Figure 6

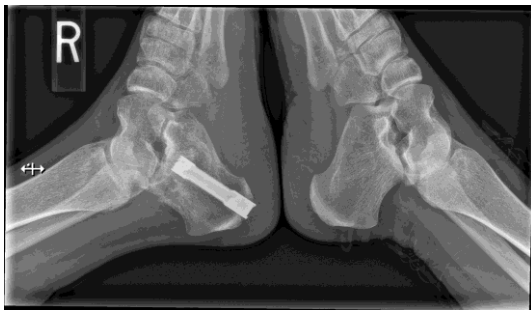

Figure 7

Summation

The use of Calcanail intramedullary nailing in the treatment of displaced intra-articular fractures is a minimally invasive procedure associated with a low risk of complications.

The innovative posterior approach allows for the intrafocal reduction of an articular surface fracture through the prepared intramedullary canal.

References

- 1) Buckley R, Tough S, McCormack R, Pate G, Leighton R, Petrie D, Galpin R: Operative compared with nonoperative treatment of displaced intra-articular calcaneal fractures: a prospective, randomized, controlled multicenter trial. *J Bone Joint Surg Am*, 2002, 84-A(10):1733-44.
- 2) Howard JL, Buckley R, McCormack R, Pate G, Leighton R, Petrie D, Galpin R: Complications following management of displaced intra-articular calcaneal fractures: a prospective randomized trial comparing open reduction internal fixation with

- nonoperative management. *J Orthop Trauma*, 2003, 17:241-249.
- 3) Griffin D, Parsons N, Shaw E, Kulikov Y, Hutchinson C, Thorogood M, Lamb SE: Operative versus non-operative treatment for closed, displaced, intra-articular fractures of the calcaneus: randomised controlled trial. *BMJ*, 2014, 349:g4483.
 - 4) Abidi NA, Dhawan S, Gruen GS, Vogt MT, Conti SF: Wound-healing risk factors after open reduction and internal fixation of calcaneal fractures. *Foot Ankle Int*, 1998, 19(12):856-861.
 - 5) Baumgaertel FR, Gotzen L: Two-stage treatment of comminuted os calcis fractures: primary indirect reduction with medial external fixation and delayed lateral plate fixation. *Clin Orthop Relat Res*, 1993, (290):132-41.
 - 6) Bégué T, Mebtouche N, Auregan JC, Saintyves G, Levante S, Cottin P: External fixation of the thalamic portion of a fractured calcaneus: a new surgical technique. *Orthop Trauma Surg Res*, 2014, 100:429-432.
 - 7) Schepers T, Vogels LM, Schipper IB, Patka P: Percutaneous reduction and fixation of intra-articular calcaneal fractures. *Oper Orthop Traumatol*, 2008, 20:168-175.
 - 8) Walde TA, Sauer B, Degreif J, Walde HJ: Closed reduction and percutaneous Kirschner wire fixation for the treatment of dislocated calcaneal fractures: surgical technique, complications, clinical and radiological results after 2-10 years. *Arch Orthop Trauma Surg*, 2008, 128:585-591.
 - 9) Arastu M, Sheehan B, Buckley R: Minimally invasive reduction and fixation of displaced calcaneal fractures: surgical technique and radiographic analysis. *Int Orthop*, 2014, 38(3):539-545.
 - 10) Abdelazeem A, Khedr A, Abousayed M, Seifeldin A, Khaled S: Management of displaced intra-articular calcaneal fractures using the limited open sinus tarsi approach and fixation by screws only technique. *Int Orthop*, 2014, 38(3):601-606.
 - 11) Jacquot F, Atchabahian A: Balloon reduction and cement fixation in intra-articular calcaneal fractures: a percutaneous approach to intra-articular calcaneal fractures. *Int Orthop*, 2011, 35:1007-1014.
 - 12) Vittore D, Vicenti G, Caizzi G, Abate A, Moretti B: Balloon-assisted reduction, pin fixation and tricalcium phosphate augmentation for calcaneal fracture. *Injury*, 2014, Suppl.6:S72-S79.
 - 13) Schepers T: Towards uniformity in communication and a tailor-made treatment for displaced intra-articular calcaneal fractures. *Int Orthop*, 2014, 38(3):663-665.
 - 14) Goldzak M, Mittlmeier T, Simon P: Locked nailing for the treatment of displaced

articular fractures of the calcaneus: description of a new procedure with calcanail®.
Eur J Orthop Surg Traumatol, 2012, 22:345-349.

- 15) Simon P, Goldzak M, Mittlmeier T: Internal fixation or primary fusion in displaced articular fractures of the calcaneus: a new procedure with calcanail. Med Chir Pied, 2013, 29:100-104.