

The lateralizing and localizing value of peri-ictal cough in epileptic seizures

Bektaş Korkmaz, Gülsün Erşen, Şakir Delil, Çiğdem Özkara, S. Naz Yeni

Istanbul University Cerrahpasa Faculty of Medicine
Neurology and Clinical Neurophysiology Department

Received September 09, 2013
Accepted for publication on-line December 17, 2013
Published on-line December 19, 2013

Correspondence

Dr. Bektaş Korkmaz
Clinic Neurophysiology Assistant
Cerrahpasa Faculty of Medicine
Fatih, İstanbul, Turkey
e-mail: bektaskorkmaz@hotmail.com
Phone: +90 505 726 77 16

SUMMARY

Introduction. Coughing may be observed as an epiphenomenon during or after epileptic seizures.

Aim. In this paper we discuss the lateralization and localization value of cough as an epileptic peri/post ictal semiological phenomenon.

Material and Methods. Seven patients presenting cough as a part of their symptomatology are presented. We will discuss cough in the context of these seven patients.

Results. Six out of these seven patients were multidrug resistant temporal lobe epilepsy patients, all were right handed. They were all examined for possible epilepsy surgery and four underwent surgery with complete seizure freedom. We do not have certain evidence for lateralization in one patient with hot water epilepsy though déjà vu as an initial symptom in this patient implies a temporal lobe onset. The seven other patients had temporal lobe epilepsy. Among the patients who had surgery, three had left sided and one had right sided temporal lobe surgery with consequent seizure freedom.

Conclusion. Referring to the argument in the literature, with our small patient sample, we might conclude that cough has significant value in localizing seizures to the temporal lobe but overall these limited data do not suggest a lateralizing value.

Key words: cough • seizure localization • temporal lobe epilepsy • video-EEG • epilepsy surgery

INTRODUCTION

Cough is one of the most common symptoms for which people see the doctor. It is a reflex reaction to vagal afferent inputs, however higher cortical levels may also play a part in the generation of cough and may be observed as a sign/symptom during or after epileptic seizures (Mazzone et al., 2013).

Symptoms such as blinking, nose wiping, upper limb automatisms, vomiting, etc have been discussed within the context of lateralization and localization of epileptic seizures in epilepsy surgery candidates though cough has not been evaluated to any significant extent and there is controversy as to its value.

AIM

To report 7 cases of epilepsy patients referred to our epilepsy outpatient clinic presenting cough as a peri-ictal manifestation. We will discuss cough and its lateralizing and localizing value in epilepsy surgery in the context of these seven patients and the literature.

MATERIAL AND METHODS

Four of the 7 patients were referred to the epilepsy outpatient clinic between January–June 2013. During this period, a total of 703 patients were examined in the epileptic outpatient clinic. Three additional cases already registered to have peri-ictal coughing among patients

Table 1. Patient demographics

Patient	Age/ gender	Seizure onset	Febrile convulsion	Neuropsychological tests	Neuroimaging	Follow-up
1	38/male	20	Yes	Verbal memory deficit	MRI: Left HS* PET: Left MTH**	Under consideration for ATL***
2	33/male	infancy	No	NA*****	MRI: Normal	Responsive to monotherapy
3	35/female	25	Yes	Verbal memory deficit	MRI: Normal PET: Left MTH**	Seizure free since ATL*** in April 2013
4	39/female	32	No	Verbal memory deficit	MRI: Left HS*	Seizure free since ATL*** in 2002
5	37/female	7	Yes	Nonverbal memory deficit	MRI: Right HS*	Seizure free since ATL*** in 2003
6	37/female	12	No	Verbal memory deficit	MRI: Left HS*	Seizure free since ATL in 2001
7	37/female	10 months old	No	NA*****	MRI: Left HS*	Under consideration for ES****

*HS – hippocampal sclerosis; **MTH – mesial temporal hypometabolism; *** ATL – anterior temporal lobectomy; ****ES – epilepsy surgery; *****NA – not available

who underwent epilepsy surgery were also included. We will summarize these patients.

All seven patients (2 male, 5 female) are described below and summarized in table 1. All patients were right handed. All patients but one were multidrug resistant. Neurological examinations were in the normal range apart from neuropsychological tests. Four out of 6 multidrug resistant epilepsy patients underwent epilepsy surgery and have become seizure free.

RESULTS

Patient 1. 38 years old male attended to our outpatient clinic with a history of multi-drug resistant epilepsy starting at the age of 20 years. His medical history revealed multiple febrile convulsions at the age of 3 years. He had video-EEG recording. Seizure semiology was as follows: aura (described as nice fruit odours and taste), oral automatisms and coughing followed by right hand automatisms, wiping nose with left hand and as the seizures was about to end he coughed again. EEG recording revealed rare spike and wave activity on F7 electrode and an ictal pattern lateralized to the left hemisphere (figure 1). Neuropsychological tests detected verbal memory impairment. Cranial MRI was consistent with left hippocampal sclerosis. PET analysis showed left mesial temporal hypometabolism. Epilepsy surgery is planned for his treatment.

Patient 2. 33 years old male attended our outpatient clinic after having a generalized convulsion immediately after falling asleep following application of a hot water package to his neck for relief of muscle pain. His history revealed recurrent attacks triggered by shower with hot water and presenting by déjà vu like feelings

and sometimes loss of consciousness accompanied by bilateral upper limb automatisms. Some seizures were prolonged and he started coughing and vomiting at the end of such a seizure. He could not remember the exact timing of his first episode but they went back to infancy. For the last 5 to 6 years seizures began to occur spontaneously and he had two generalized convulsions, since the beginning of his 20's. Routine and sleep EEG recording was normal. Cranial MRI was normal. He was offered lamotrigine b.i.d. 100 mg and he is now seizure free.

Patient 3. 35 years old female attended to our outpatient clinic for multi-drug resistant epilepsy starting at the age of 25 years. Her medical history revealed a febrile convulsion when she was 6 months old. Video-EEG recording revealed (she defined a hump as an aura) oral automatisms, dystonic posture at her right hand and automatisms on her left hand. Following these symptoms she started coughing. Ictal and interictal EEG recordings suggested left temporal region as a focus. Cranial MRI was normal. PET analysis showed left mesial temporal hypometabolism (figure 2). She underwent anterior temporal lobectomy six months ago. She has no epileptic seizures since then. The pathological specimen was consistent with hippocampal sclerosis.

Patient 4. 39 years old female attended to our outpatient clinic with a history of multi-drug resistant epilepsy for 7 years. Video-EEG monitoring revealed aura (described as a feeling as if her hands were cold), loss of consciousness accompanied by oroalimentary automatisms, automatisms on her left hand and coughing. Cranial MRI was consistent with left hippocampal sclerosis. Interictal and ictal EEG suggested a left temporal

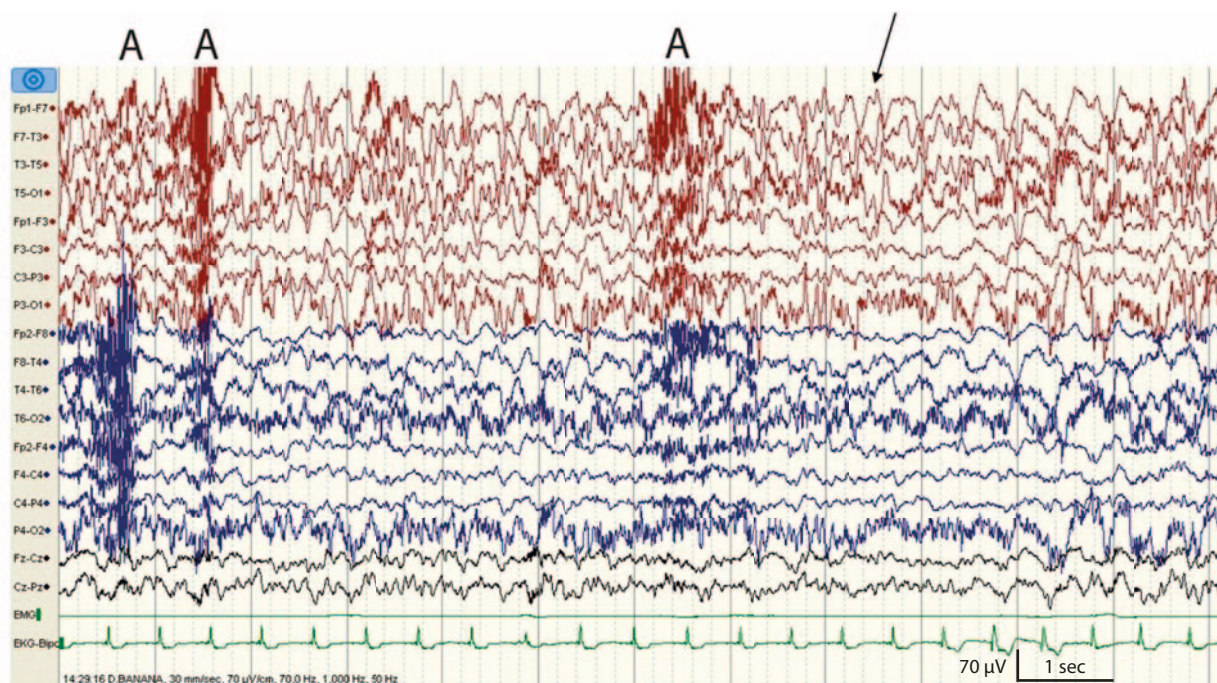


Figure 1. Scalp video EEG and EKG recording during a seizure by patient no 1. There are action muscle potentials (artefacts) during oral automatisms (marked by A). The arrow points to the moment when the cough started. Vertical solid lines mark 1s intervals. The vertical bar shows amplification (right lower corner).

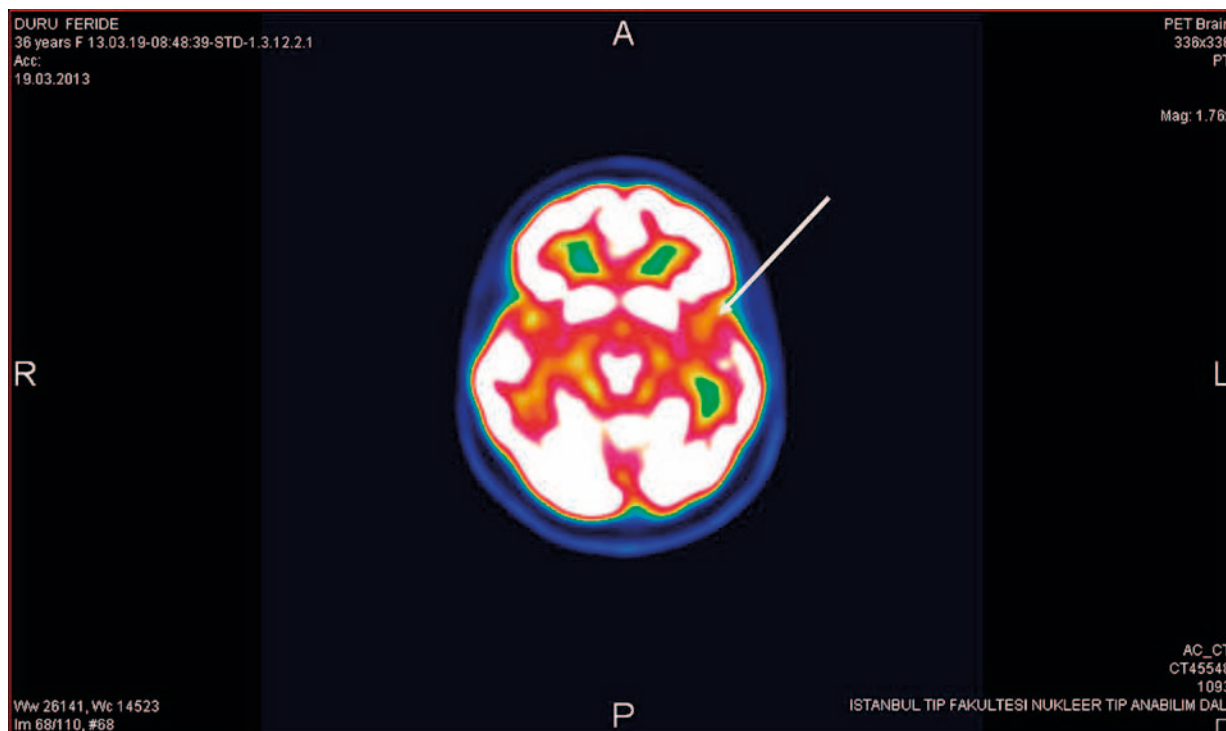


Figure 2. Patients no 3. PET reveals left temporal hypometabolism (marked by arrow).

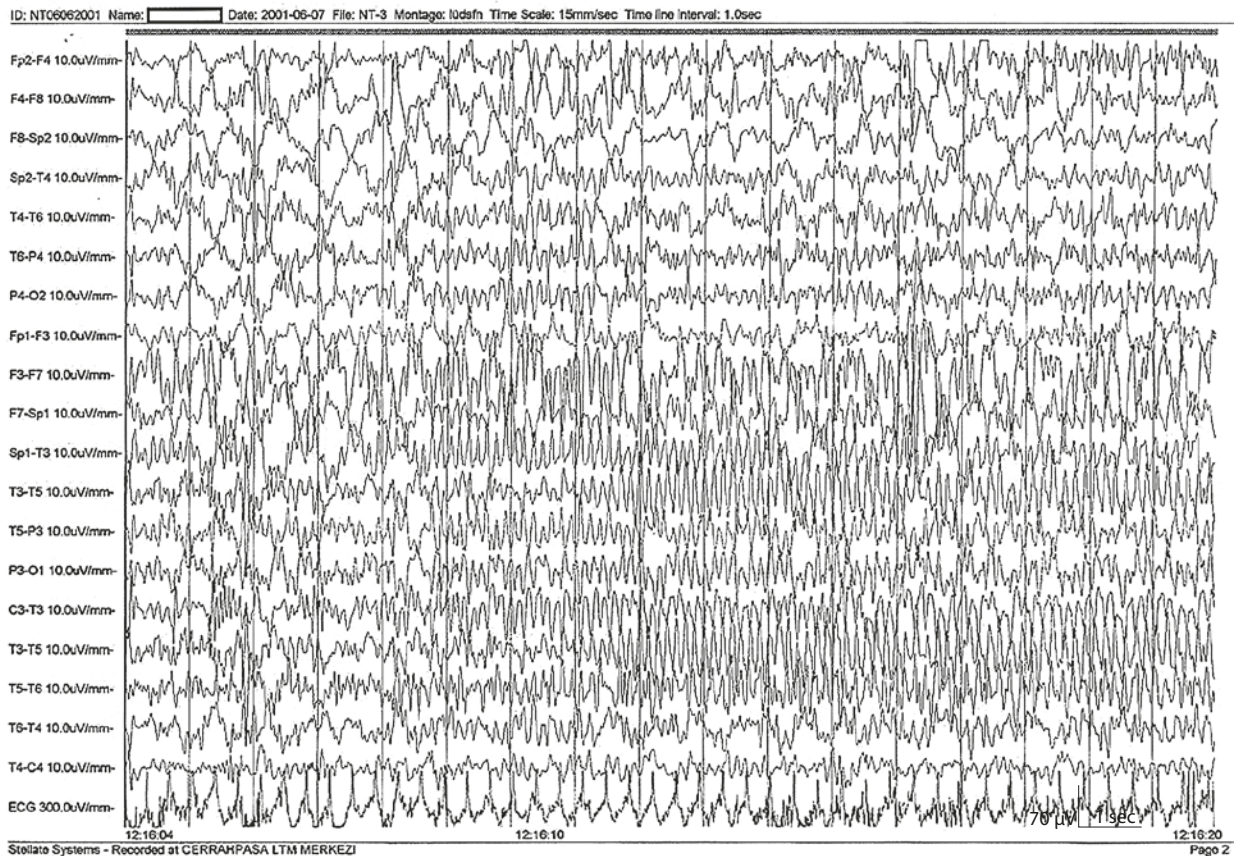


Figure 3. Patient no 6. An ictal EEG recording of the patient with left temporal lobe epilepsy showing focal rhythmic seizure pattern localized to the left temporal region. Calibrations – right lower corner.

focus. Neuropsychological tests detected verbal memory impairment. She underwent epilepsy surgery (anterior temporal lobectomy) in 2002 and she is now seizure free. Report of surgical pathology is not available.

Patient 5. 37 years old female attended to our outpatient clinic with multi-drug resistant epilepsy starting at the age of 7 years. History revealed that she had febrile convulsions between 6–12 months. Video-EEG recordings revealed loss of consciousness, staring followed by nose wiping with right hand and if the seizure was prolonged, coughing occurred as the final semiological feature. Some seizures evolved into generalized bilateral convulsions. Ictal and interictal EEG recordings were consistent with right temporal region as the origin. Cranial MRI was consistent with right hippocampal sclerosis. Neuropsychological tests detected non-verbal memory impairment. She underwent epilepsy surgery (anterior temporal lobectomy) and she has been seizure free for 10 years. The pathological specimen was consistent with moderate-to-severe level hippocampal sclerosis.

Patient 6. 37 years old female patient was referred to our clinic with multi-drug resistant epilepsy beginning at the age of 12 years. Video-EEG monitoring showed aura (described as epigastric rising sensations), loss of consciousness, oroalimentary automatisms, nose wiping with left hand and coughing. Ictal and interictal EEG recordings were consistent with left temporal region as the focus (figure 3). Cranial MRI was consistent with left hippocampal sclerosis. Neuropsychological tests detected verbal memory impairment. She underwent epilepsy surgery (anterior temporal lobectomy) in 2001 and she has been seizure free ever since. Report of surgical pathology is not available.

Patient 7. 37 years old female attended our outpatient clinic with a history of multi-drug resistant epilepsy. She had her first seizure when she was 10 months old but resistant seizures started at the age of 13. Aura was defined as a sensation of hotness over her head turning into coldness. Following this aura her eyes deviated upwards and oral automatisms began. Perioral cyanosis

occurred. A stiffening began from her right arm and leg and then spread. Seizures stopped with her coughing followed by running. Cranial MRI revealed left hippocampal sclerosis. Awake and sleep EEG revealed active, bilateral independent spikes on F7/8, T3/4 electrodes. While having another routine EEG, the patient experienced an aura which was accompanied by repetitive spikes on the left temporal electrodes. Her video-EEG recording and neuropsychological tests are planned for epilepsy surgery.

DISCUSSION

We summarized 7 epilepsy patients presenting with cough as a peri-ictal phenomenon. In this small sample, six out of 7 patients were intractable to treatment and therefore candidates to surgery and four had temporal lobe epilepsy surgery with excellent outcome. The major concern in this paper is to discuss the localizing and lateralizing value of this rare sign in this sample and with reference to the literature.

This phenomenon may be observed as an ictal or postictal sign but we could not classify it in this regard for two major reasons; firstly the definition of an ictal or postictal cough is not clear in the literature and secondly, we do not have video-EEG recordings in all patients. Therefore we include all patients presenting with cough during and/or after seizures under the umbrella of peri-ictal cough (e.g. figure 1).

From the pathophysiological point of view, coughing occurs through the stimulation of a complex reflex arc. Cough receptors are widely placed within airway and places such as eardrum and paranasal sinuses. When these receptors are stimulated the stimulus is carried to coughing center in the medulla oblongata via vagal nerve. Stimulation of this center – also being controlled by higher cortical regions – sends efferent stimuli via vagal nerve, nervus phrenicus and spinal motor nerves and coughing occurs (Baekey et al., 2001; Peiffer et al., 2001; Mazzone et al., 2009; Mazzone et al., 2011; Polverino et al., 2012). Coughing as a reflex to acute respiratory distress serves as a basic defense mechanism to clear airways. Voluntary cough and suppressing coughing are controlled by higher cortical networks (Simonyan et al., 2007; Mazzone et al., 2011). It has been shown that many cortical brain areas, including posterior insula and posterior cingulate cortex, are activated during evoked cough (Mazzone et al., 2013). Another similar study suggested that suppression of cough triggered by airway irritation is associated with

cortical areas such as anterior insula, supplementary motor area, motor cingulate cortex and right inferior frontal gyrus (Mazzone et al., 2011; Farrell et al., 2012). On the other hand, voluntary cough is associated with various different cortical areas such as the sensorimotor cortex, the supplementary motor area and the cerebellum (Mazzone et al., 2013).

The underlying mechanisms debated lately about nose wiping is that it occurs as a result of increased secretion throughout the nasotracheal branch (Wennberg, 2001). Similar to this mechanism, increased secretion induced by the autonomic nervous system might also be responsible for postictal cough (Baumgartner et al., 2001). Hail et al. (2011) proposes that ictal discharges from amygdala cause ictal wiping and rubbing of nose but the mechanism of postictal nose wiping is not known (Hail et al., 2011). However the networks in the generation of cough include insular areas as highlighted by the functional studies described above. These data may imply the importance of insular areas in the network of temporal lobe epilepsy with coughing. In our patients, five had a video recording and three were observed to have nose wiping as an additional feature to coughing. This co-occurrence may be a support to this hypothesis.

Peri-ictal cough is not a frequently cited sign and its prevalence has not been established. In our sample, four of 7 patients attended an outpatient clinic and we can therefore give an estimate of 0.56% in a period of 6 months. The other patients were identified from the surgical cases. However, we can't give a prevalence rate depending on these numbers, as this is neither a prospective study with a predefined purpose nor a retrospective analysis of all video recordings of seizures. A search of the literature using peri-ictal/postictal cough as the key word, we were unable to identify much data regarding the prevalence. In a study comparing hippocampal versus extrahippocampal temporal lobe epilepsies, postictal cough was observed in 18.8% of patients with hippocampal temporal lobe epilepsy (Gil-Nagel and Risinger, 1997). In a retrospective study, 380 seizures of 97 temporal lobe epilepsy patients who underwent epilepsy surgery during at least 2 years before the study was conducted, has reported on rare peri-ictal vegetative symptoms such as, cough, water drinking, vomiting and spitting. Sixty of these patients were classified as having mesial temporal sclerosis and 37 patients were classified as non-mesial temporal sclerosis. Peri-ictal cough was found to be the most

Table 2. Summary of findings of the three studies reporting on peri-ictal cough

Article*	N of peri-ictal cough to total patients	N of cough/MTS	N of cough/lesion-TLE	N of cough/NTLE	N of cough/EXTLE	Dominant/nondominant**** (TLE)
Fauser et al., 2012	16/197	6/42	4/42	1/20	5/62	8/2
Janszky et al., 2007	22/141**	NA/127	NA/15	NA	NA	9/8***
Musilova et al., 2010	24/97	14/60	10/37	NA	NA	7/17

N – number; MTS – mesial temporal sclerosis; TLE – temporal lobe epilepsy; NTLE – neocortical temporal lobe epilepsy; EXTLE – extra temporal lobe epilepsy; NA – not available

* Patients who had bilateral or diffuse onset were not included and the data with regard to the side of epilepsy was limited to TLE in this table

** All patients had medial temporal lobe epilepsy; but frequency of cough was not reported according to lesion type

*** Patients who have been evaluated in terms of language dominance were included

**** Number of patients with TLE presenting periictal cough, according to language dominant or nondominant side

frequent symptom in 24.7% of patients and 10% of seizures (Musilova et al., 2010).

Regarding its localizing value in epilepsy surgery candidates, postictal cough is more frequently associated with temporal lobe epilepsy rather than extratemporal lobe epilepsy and is not observed in non-epileptic seizures (Wennberg, 2001). Fauser et al. (2004) also proposed that ictal/postictal cough may be associated with both temporal and extratemporal lobe epilepsies but it is more common in temporal lobe epilepsies. Wennberg (2001) also pointed out that it is usually a sign in mesial temporal lobe epilepsy. So this sign has been accepted to have a localizing value for temporal lobe epilepsy. In our small sample, five patients had mesial temporal sclerosis on cranial MR. Three of these patients had surgery with seizure freedom more than 10 years of follow up. Two patients are under investigation for epilepsy surgery but data indicate mostly temporal lobe origin (patient no 1 and 7). One patient (no 3) with normal cranial MR had temporal hypometabolism on PET scan and is seizure free for six months in the post operative period. Although, we do not have clear evidence for lateralization and also localization of one patient with hot water epilepsy (patient no 2), déjà vu as an aura in this patient implies a temporal lobe onset (Weinand et al., 1994; Gil-Nagel and Risinger, 1997; Chris et al., 2012).

The other issue in this study was to answer the lateralizing value of peri-ictal cough. It has been proposed that postictal cough has clinical value for lateralizing seizure onset zone to the right (verbally non-dominant) hemisphere (Wennberg, 2001; Musilova et al., 2010). However some studies suggest that peri-ictal cough has no lateralizing value (Janszky et al., 2007) and also some investigators have observed an association with the dominant side (Fauser et al., 2004) (ta-

ble 2). Our small sample contributes to this controversy because three of four patients had left sided and one had right sided temporal lobe surgery with complete seizure freedom in three of these patients for more than 10 years.

CONCLUSION

According to a review by Stoyke et al. (2011) lateralizing value of postictal coughing has not been established. Therefore, referring to the argument in literature, with our small sample we might contribute that cough has significant value in localizing seizures to temporal lobe but taking together our sample and the patients described in the literature, cough does not appear to have a lateralizing value.

CONFLICT OF INTEREST DISCLOSURE

There are no conflicting financial interests or commercial considerations to declare.

REFERENCES

- Baekey D.M., Morris K.F., Gestreau C., Li Z., Lindsey B.G., Shannon R.: *Medullary respiratory neurones and control of laryngeal motoneurons during fictive eupnoea and cough in the cat*. J. Physiol., 2001, 534: 565–581.
- Baumgartner C., Lurger S., Leutmezer F.: *Autonomic symptoms during epileptic seizures*. Epileptic Disord., 2001, 3: 103–116.
- Farrell M.J., Cole L.J., Chiapoco D., Egan G.F., Mazzone S.B.: *Neural correlates coding stimulus level and perception of capsaicin-evoked urge-to-cough in humans*. Neuroimage, 2012, 61: 1324–1335.
- Fauser S., Wuwer Y., Gierschner C., Schulze-Bonhage A.: *The localizing and lateralizing value of ictal/postictal coughing in patients with focal epilepsies*. Seizure 2004, 3: 403–410.
- Gil-Nagel A. and Risinger M.W.: *Ictal semiology in hip-*

pocampal versus extrahippocampal temporal lobe epipepsy. Brain, 1997, 120: 183–192.

Hail H.J.A., Wieser H.G., Boulenour Mesraoua B.: *Ictal wiping or rubbing movements of the nose and lower eye lid by hand ipsilateral to the hemispheric lesion: symptoms of the “insular ocular movements area”?* Epileptologia, 2011, 19: 51–57.

Janszky J., Fogarasi A., Toth V., Magalova V., Gyimesi C., Kovacs N. et al.: *Peri-ictal vegetative symptoms in temporal lobe epilepsy*. Epilepsy & Behav., 2007, 11: 125–129.

Martin C.B., Mirsattari S.M., Pruessner J.C., Pietrantonio S., Burneo J.G., Hayman-Albello B. et al.: *Déjà vu in unilateral temporal-lobe epilepsy is associated with selective familiarity impairments on experimental task of recognition memory*. Neuropsychologia, 2012, 50: 2981–2991.

Mazzone S.B., Cole L.J., Ando A., Egan G.F., Farrell M.J.: *Investigation of the neural control of cough and cough suppression in humans using functional brain imaging*. J. Neurosci., 2011, 31: 2948–2958.

Mazzone S.B., McGovern A.E., Koo K., Farrell M.J.: *Mapping supramedullary pathways involved in cough using functional brain imaging: comparison with pain*. Pulm. Pharmacol., Ther., 2009, 22: 90–96.

Mazzone S.B., McGovern A.E., Yang S.K., Woo A., Phipps S., Ando A. et al.: *Sensorimotor circuitry involved in the higher brain control of coughing*. Cough, 2013, 9:7. doi: 10.1186/1745-9974-9-7. Available from www.coughjournal.com/content/9/1/7

Musilova K., Kuba R., Brazdil M., Tyrlikova I., Rektor I.: *Occurrence and lateralizing value of “rare” peri-ictal vegetative symptoms in temporal lobe epilepsy*. Epilepsy & Behav., 2010, 19: 372–375.

Peiffer C., Poline J.B., Thivard L., Aubier M., Samson Y.: *Neural substrates for the perception of acutely induced dyspnea*. Am. J. Respir. Crit. Care Med., 2001, 163: 951–957.

Polverino M., Poverino F., Fasolino M., Andò F., Alfieri A., De Blasio F.: *Anatomy and neuro-pathophysiology of the cough reflex arc*. Multidisciplinary Respiratory Medicine, 2012, 7: 5. doi: 10.1186/2049-6958-7-5. Available from www.mrmjournal.com/content/7/1/5

Simonyan K., Saad Z.S., Loucks T.M., Poletto C.J., Ludlow C.L.: *Functional neuroanatomy of human voluntary cough and sniff production*. Neuroimage, 2007, 37: 401–409.

Stoyke C., Bilgin Ö., Noachtar S.: *Video atlas of lateralising and localising seizure phenomena*. Epileptic Disord., 2011, 13: 113–124.

Wennberg R.: *Postictal coughing and noserubbing coexist in temporal lobe epilepsy*. Neurology, 2001, 56: 133–134.

Weinand M.E., Hermann B., Wyler A.R., Carter L.P., Oomen K.J., Labiner D. et al.: *Long Term subdural strip electrocorocographic monitoring of ictal déjà vu*. Epilepsia, 1994, 35: 1054–1059.

