



CODEN [USA]: IAJPBB

ISSN: 2349-7750

**INDO AMERICAN JOURNAL OF  
PHARMACEUTICAL SCIENCES**Available online at: <http://www.iajps.com>

Research Article

**CHONDROPROTECTIVE ACTIVITY OF BEE-VENOM  
MELITTIN AND CRAB SHELL CHITIN ON PAPAINE INDUCED  
OSTEOARTHRITIS IN RABBITS**Ravindra Babu Sajja<sup>1,3\*</sup>, Prasad K<sup>2</sup>, Eswar Kumar K<sup>1</sup> and G.Phani C Reddy<sup>3</sup><sup>1</sup>College of Pharmaceutical Sciences, Andhra University, Visakhapatnam.<sup>2</sup>Department of Pharmacology, Shri Vishnu College of Pharmacy, Bhimavaram.<sup>3</sup>Department of Pharmacology, Malla Reddy Institute of Pharmaceutical Sciences, Secunderabad.**Abstract:**

*In the present study the chondroprotective effect of melittin and chitin from bee venom and crab shell was examined against papain induced osteoarthritis in rabbits. The leukocyte count in synovial fluid, X-ray radiography of ankle joints and histopathology of joint cartilage were performed to assess chondroprotective activity. There is a significant fall in leukocyte count of bee venom (1.2mg/kg, s.c) treated group when compared with osteoarthritic control and the standard groups. Histopathological studies exhibit that the chitin (80mg/kg, i.a) treated group shows no degradation in joint cartilage when compared to bee venom and combination (bee venom+chitin) groups which shown little deviations to that of prednisolone (10mg/kg, s.c) group. X-ray graphs revealed that bee venom, chitin and combination of both shows good chondroprotective activity.*

**Keywords:** Leukocytes, Chondroprotective, Bee venom, Melittin, Chitin,**Corresponding author:****S. Ravindra Babu,**Malla Reddy Institute of Pharmaceutical Sciences,  
Maisammaguda, Secunderabad-500100

Telangana state, India

Email: [ravicology@gmail.com](mailto:ravicology@gmail.com)

Mobile NO:9949407244

QR code



Please cite this article in press as S. Ravindra Babu et al., *Chondroprotective Activity of Bee-Venom Melittin and Crab Shell Chitin on Papain Induced Osteoarthritis in Rabbits*, Indo Am. J. P. Sci, 2018; 05(02).

## 1. INTRODUCTION:

Osteoarthritis (OA) is a degenerative joint disease affecting 80–90% of men and women after age 65, and is characterized by progressive loss of articular cartilage, integrity and other joint changes. The poor regenerative capacity of the avascular and aneural articular cartilage prevents the recovery of full function after initial injury. The disease pathogenesis leading to the cartilage degradation remains an important research field [1].

Articular cartilage is a typical hyaline cartilage that covers the ends of bones making up the joints in the body. It maintains smooth and frictionless movement, and dissipates stress in the joint. Articular cartilage is an avascular and aneural tissue; it consists primarily of chondrocytes and extracellular matrix including collagen type 2 and proteoglycans, which transmit loads, stabilize the matrix, and maintain a healthy cartilage microenvironment. Due to its load-bearing function, cartilage is highly susceptible to damage during sports activities, and wear and tear over time. First proposed by Hunter in 1742, it has long been recognized that cartilage defects cannot heal spontaneously. Researchers believe that the poor self-healing capacity is probably due to the poor blood supply and low metabolic activity in cartilage. If injured cartilage is not treated, it gets worse and affects surrounding tissue, and ultimately degenerates into OA<sup>2</sup>.

In addition to cartilage degeneration, OA usually affects all structures in the synovial joint. Aberrant hypertrophy and calcification are reported in several OA cases. Subchondral bone sclerosis, meniscal tear and extrusion, and synovial membrane inflammation (synovitis) may also occur due to the mechanical changes in OA cartilage, and make OA disease more debilitating<sup>2</sup>.

Bee venom (BV) is a poison which is secreted from stings of *Apis mellifera L.* Bee venom has been used since ancient times in traditional medicine to treat various diseases which is known as “APITHERAPY”, the origin of Apitherapy can be traced back to ancient Egypt, Greece and has been practiced in China for 3-5000 years. BV contains a variety of peptides including melittin, apamin, Adolapin. It also contains enzymes (e.g., PLA2), biologically active amines (e.g., histamine and epinephrine) and non-peptide components (including lipids, carbohydrates and free amino acids. Bee

venom has a wide pharmacological activities like Anti-inflammatory, Anti-arthritis, Anti-Nociceptive/Analgesic, Anti cancer, Anti oxidant activity, anti bacterial, Multiple sclerosis, Lupus, Sciatica, Low back pain and tennis elbow.<sup>[3,4]</sup>

The Mud crab *Scylla Serrata* contains more than 60% of chitin in their shells which can be easily extracted by utilizing micro-organisms and enzymes. chitin is translucent, pliable, resilient, and quite tough. It is slightly soluble in water and hygroscopic and forms a soft and gel like slimy texture when placed in long contact with water. The medicinal properties and uses of chitin include Anti-microbial activity, Anti-Oxidant activity, Anti-cancer activity, Anti-Inflammatory activity, Anti-fungal activity, Immuno-Stimulating activity.<sup>[5,6]</sup>

The objective of this study is to evaluate the chondroprotective effect of bee venom melittin and crab shell chitin in the treatment of osteoarthritis induced rabbits.

## 2. MATERIALS AND METHODS:

### 2.1. Animals

New Zealand white, rabbits weighing 2 to 3 kg purchased from Acharya N.G.Ranga Veterinary university rabbit research division, Rajendranagar, Hyderabad. The animals were brought in the transport cages and were housed in quarantine conditions for seven days to be monitored for normalcy and to allow time for acclimation to the new environment and handling. The rabbits were placed individually into 4 square foot stainless iron cages and all housed in the same area with an ambient temperature of 21-22°C and a relative humidity of 50-70%. A 12:12h light: dark (photoperiod) was maintained. All the precautions were taken to avoid the contamination due to materials and humans. The rabbits are fed on standard 14% protein Diet obtained from National center for laboratory animal sciences NIN, Hyderabad. All the Experimental procedures and protocols used in the study were reviewed by institutional Animals Ethics Committee (Regd No: 1662/PO/Re/S/12/CPCSEA) and were in accordance with the guidelines of CPCSEA.

### 2.2. Experimental methodology

#### 2.2.1. Grouping of animals

The rabbits were divided into 6 groups in equal number randomly (n=6) with both sexes.

**Table-1: Grouping of animals**

S.No	Group number	Treatment received
1.	Group I	Normal control received Normal saline(0.3 ml/joint i.a)
2.	Group II	Papain induced osteoarthritic control.
3.	Group III	Papain induced osteoarthritis animals received Standard drug prednisolone (10mg/kg, s.c).
4.	Group IV	Papain induced osteoarthritis animals received Bee venom (1.2mg/kg s.c) and chitin (80mg/kg, i.a).
5.	Group V	Papain induced osteoarthritis animals received Bee venom 1.2mg/kg s.c)
6.	Group VI	Papain induced osteoarthritis animals received Chitin (80mg/kg, i.a)

**2.2.2. Osteoarthritis induction by Papain [7-10]**

Osteoarthritis was induced in both ankles in all groups except the normal control group by injecting 0.2 ml of 4% papain solution with 0.1 ml of 0.03 M cystein as activator intra-Articularly. Same amount of saline was injected into the ankles of the first group. To facilitate easy intra articular injection the rabbits are to be anaesthetized with Ketamine and Xylazine (10/3.0mg/kg IM). The induction of osteoarthritis starts on day 8<sup>th</sup> after the acclimatization of seven days and injection (i.a) was repeated on the day 11, 14 and 15<sup>th</sup> day of study for perfect cartilage degradation. The treatment was started on 16<sup>th</sup> day and the synovial fluid was collected from tibio-calcaneal or ankle joint on 20,28 and 35<sup>th</sup> day.

**2.2.3. Synovial fluid Aspiration [11-16]**

Synovial fluid was collected from Tibio-calcaneal or ankle joint. The rabbits were anesthetized by combination of Ketamine hydrochloride and Xylazine Hydrochloride (10/3.0mg/kg IM). Before anaesthetizing as a preanaesthetic medication the rabbits were Atropinized with Atropine sulphate (0.05mg/kg IM). Both stifles were shaved, aseptically prepared, and the ankle joints were lavaged with sterile saline. A 22 gauge, 1 inch needle was inserted adjacent to the lateral aspect of the tibia into the ankle joint. A 1 ml syringe was used to inject 200µl of sterile saline that was immediately aspirated back.

**2.2.4. Leukocyte cell count**

The synovial fluids aspirated on 8, 14, 20,28 and 35<sup>th</sup> day were subjected to total leukocyte count in a Neubauer's chamber by diluting the synovial fluid

with 0.1ml of WBC diluting fluid and spreaded over the Neubauer's chamber [17] and focused under the microscope at 100X Magnification and counted.

**2.2.5. Radiological X-Ray observation**

Before euthanizing on 35<sup>th</sup> day the rabbits are anaesthetized with Ketamine and Xylazine (10/3.0mg/kg IM) and X-Ray graphs were taken at the anteroposterior positions and lateral positions of ankle joints. The radiology graphs were observed for the joint space for assessment of Osteoarthritis.

**2.2.6. Histopathological Evaluation [18-13]**

Three animals from each group are euthanized with Thiopental sodium 80mg/kg IM. The Ankle joints were harvested and cartilage samples are collected and were washed in saline and fixed in 10% neutral buffered formalin and decalcified with 10% aqueous formic acid for 7 days and embedded in paraffin to allow for 4 µm sections. They were then stained with haematoxylin and eosin for microscopic examination. All examinations were done under light microscope<sup>72</sup>. The structures of the cartilage, cell appearance, staining of the cartilage, tidemark and pannus formation are observed. This are compared with that of Normal control and standard groups.

**2.3. STATISTICAL ANALYSIS:**

Statistical analyses were performed by using Student's t-tests and one-way analysis of variance (one way ANOVA). A value of P<0.05 was considered significant. Data are presented as means ± S.D.

### 3. RESULTS:

#### 3.1. Leukocyte count in Synovial fluids

**Table-2: Effect of Bee venom and Chitin on Leukocyte cell count in Synovial fluid.**

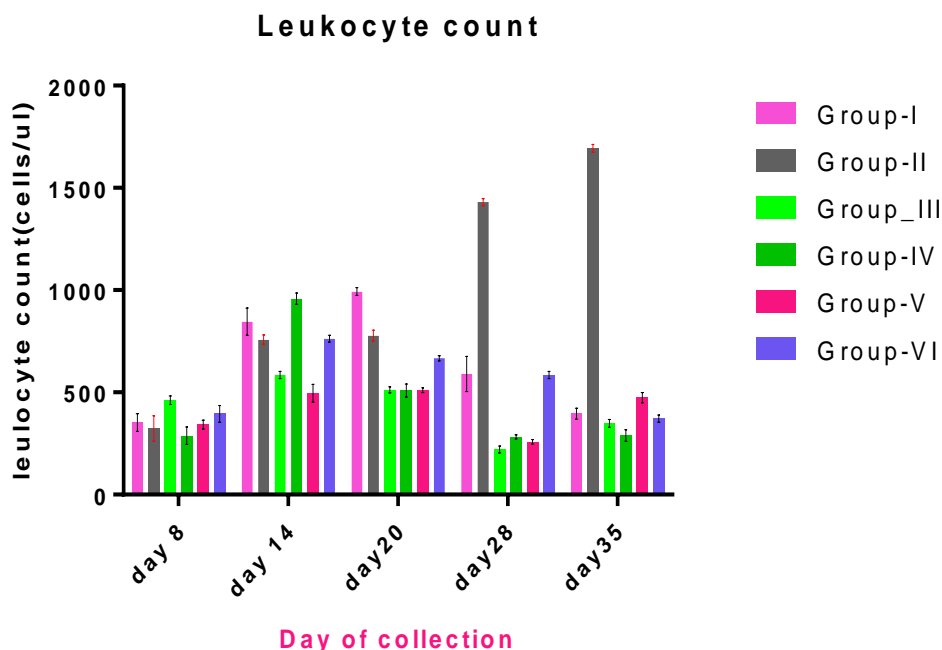
Groups	Treatment	Leukocyte Count (Cell/ $\mu$ l) in Synovial fluid				
		Day 8	Day 14	Day 20	Day 28	Day 35
Group-I	Normal saline (0.3 ml/joint i.a)	353 $\pm$ 43.37	846 $\pm$ 66.4	993 $\pm$ 19.1	590 $\pm$ 86.4	396 $\pm$ 27.3
Group-II	0.2 ml of 4% papain + 0.1 ml of 0.03 M cystein, i.a.	323 $\pm$ 62.52	758 $\pm$ 23.0	777 $\pm$ 27.5	1430 $\pm$ 17.3	1693 $\pm$ 19.7
Group-III	Prednisolone (10mg/kg, s.c)	461 $\pm$ 21.94	585 $\pm$ 17.5	513 $\pm$ 15.6 <sup>a</sup>	221 $\pm$ 17.4 <sup>a</sup>	348 $\pm$ 19.5 <sup>a</sup>
Group-IV	Beevenom + Chitin 1.2mg/kg +80mg/kg	288 $\pm$ 43.63	958 $\pm$ 27.7	509 $\pm$ 32.4 <sup>a</sup>	282 $\pm$ 10.9 <sup>a</sup>	289 $\pm$ 29.6 <sup>a</sup>
Group-V	Beevenom 1.2mg/kg s.c	550 $\pm$ 14.6	496 $\pm$ 43.7	511 $\pm$ 11.8 <sup>a</sup>	258 $\pm$ 10.4 <sup>a</sup>	474 $\pm$ 84.4 <sup>a</sup>
Group-VI	Chitin(80mg/kg, i.a)	395 $\pm$ 40.6	762 $\pm$ 16.7	667 $\pm$ 34.1 <sup>b</sup>	585 $\pm$ 16.9 <sup>a</sup>	371 $\pm$ 17.0 <sup>a</sup>

Values shown are the mean $\pm$ S.D, n=6. Group I is compared with Groups II.

Group III, IV, V and VI compared with Group II. a = p<0.001, b= p<0.01, c=p<0.05

ns = Not significant.

**Graph-1: Effect of Bee venom and Chitin on Leukocyte cell count in Synovial Fluid**



All the results are expressed as Mean $\pm$ S.D, n=6. Group I is compared with Groups II.

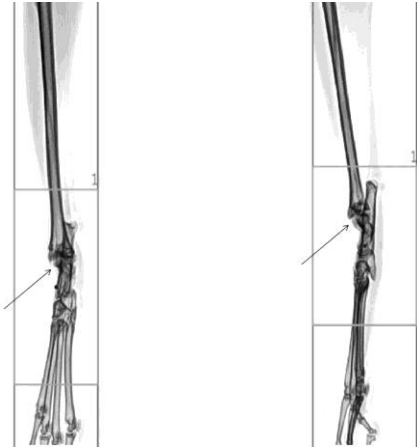
Group III, IV, V and VI compared with Group II. a = p<0.001, b= p<0.01, c=p<0.05

ns = Not significant.

**3.2. Radiological X-Ray observation**

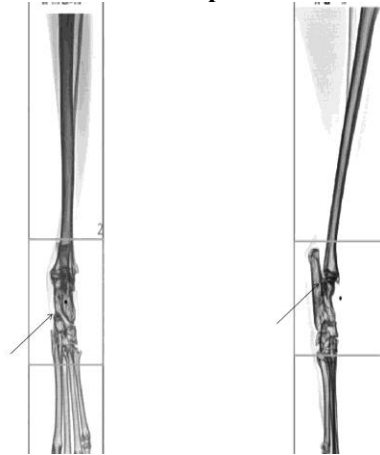
The X-rays of ankle joints were observed for joint capsule space as shown in **Fig 1-6** for the Groups I, II, III, IV, V and VI respectively.

**Group I**



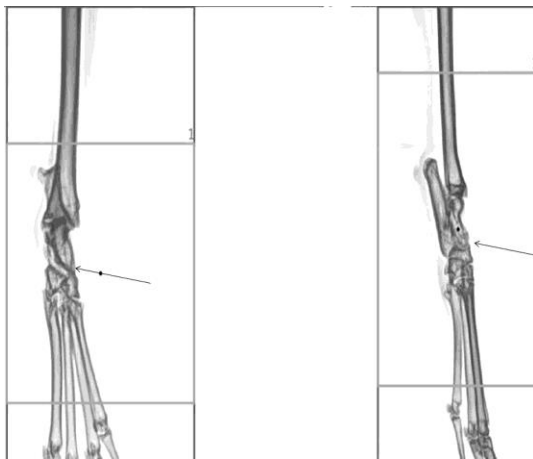
**Fig 1**

**Group II**



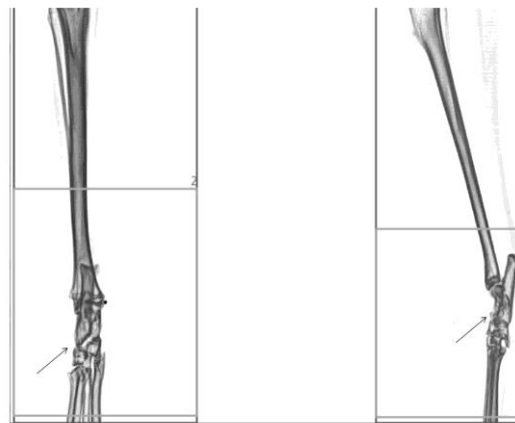
**Fig 2**

**Group III**



**Fig 3**

**Group IV**



**Fig 4**

**Group V**

**Group VI**

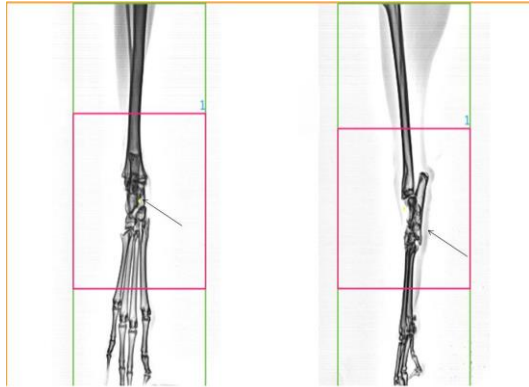


Fig 5

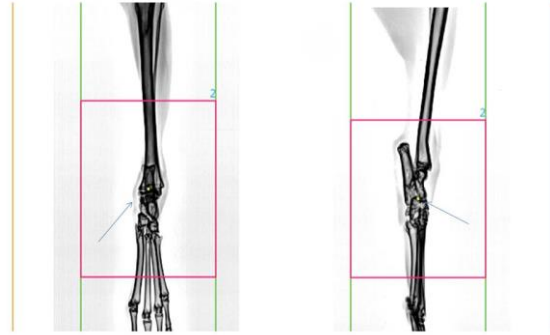


Fig 6

### 3.3. Histopathological Observation

Histopathological observations are made by comparing the different visual observations like structure of the cartilage, cell appearance, staining of the cartilage. The Histopathological images are shown in Fig 7– 12 for the Groups I, II, III, IV, V, VI respectively.

Group I



Fig-7

Group II

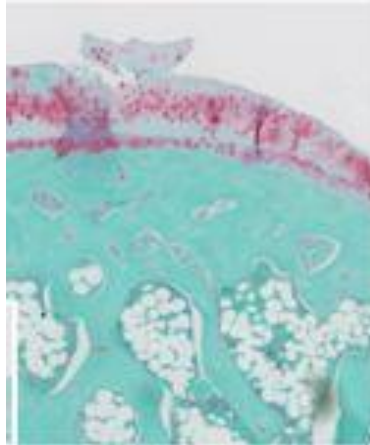


Fig-8

Group III

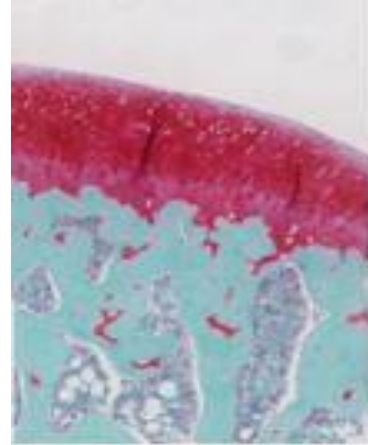


Fig-9

Group IV

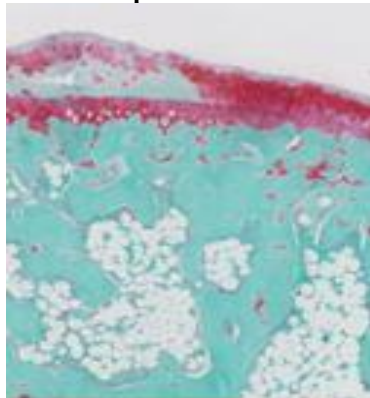


Fig-10

Group V

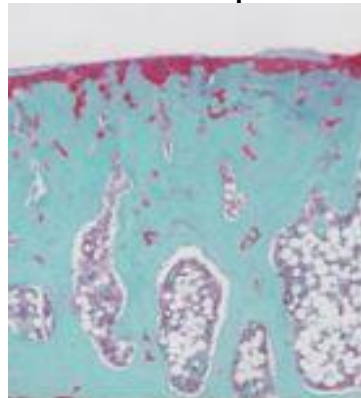


Fig-11

Group VI

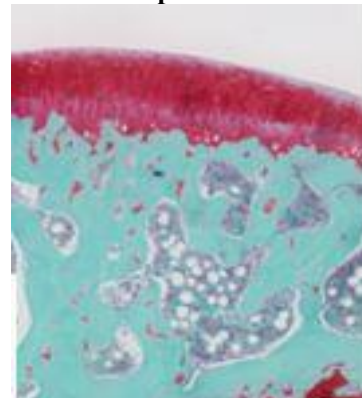


Fig-12

#### 4. DISCUSSION:

##### Leukocyte count in synovial fluid

There is a significant fall in leukocyte count of bee venom treated group when compared with the normal control group and the standard group. In case of chitin treated group the leukocyte count was not that improved but when compared with the osteoarthritic control group the count was little significant. So from the results shown in **Graph-1** it can be said that Bee venom has the potential to reduce the leukocyte count which is a major Biomarker in Osteoarthritis.

##### Radiological X-ray observation

The radiological observations are performed to assess the joint space as it is a visual confirmation that the osteoarthritic joint space will be larger than the normal joint. The **Fig 1-6** shown the X-ray reports of ankle joints of **Groups I-VI**, it was observed that the osteoarthritic control group has larger joint space than the normal control group. The Bee venom and Chitin group shown lesser joint space than the Osteoarthritic Group, and comparably more or less equal to standard and normal control groups. But in cases of individual treatment groups of Bee venom and Chitin the X-ray reports are not that better when compared to combination treatment group.

##### Histopathological observation

The results of histopathological observations were shown in **Fig 7-12** which shown the extend of degradation of cartilage. The chondroprotective activity was clear with this histopathological observation as it shown a clear demarcated difference in patterns of cartilage. The **Fig 7** is the normal control group reports no degradation in cartilage, then the next one is of osteoarthritic induced control group (**Fig 8**) which shown the degradation in cartilage and the next **Fig 9** is of standard treatment group which is clear and nearly equal to normal control group but with narrow striations in cartilage region. Next **Fig 10** is the combination treatment of Bee venom and chitin which shown little deviations to that of standard group. The **Fig 11** is the Bee venom treatment group in which the result is not prominent. Then the final one i.e **Fig 12** is the chitin group which shown a good treatment pattern of cartilage. So from the results it was clear that the Chondroprotective activity is more for chitin than Bee venom which was also confirmed from combination treated groups.

#### CONCLUSION:

The results of this study clearly indicate that Bee venom melittin and crab shell Chitin has the ability to inhibit leukocyte count and also confirm the Anti-

arthritic activity in the study. It is clear from the Radiological observations and histopathological observations that Bee venom and Chitin has Chondroprotective activity with little or negligible deviations from the normal and standard treatment groups.

#### ACKNOWLEDGEMENT:

This research was supported by the management and principal of Malla Reddy Institute of Pharmaceutical sciences, Secunderabad, India.

#### Conflict of interest

We declare that we have no conflict of interest

#### REFERENCES:

1. Fareed Alfaya Asiri, Mohamed Samir Ahmed Zaki, Eman Mohamed Al-Nashar, Adnan Waris and Mohamed Ragab Abdulsamad. Possible prevention of cartilage damage in rat knee osteoarthritis by howthorn (aronia) treatment: Histological and immunohistochemical studies. *Journal of Biochemical and Pharmacological Research*, 2014; 2 (2): 57-63.
2. Wei Zhang, Hongwei Ouyang, Crispin R Dass and Jiake Xu. Current research on pharmacologic and regenerative therapies for osteoarthritis. *Bone Research*, 2016; 4:15040.
3. Value added products from beekeeping "venom", *Journal of Value-added products from beekeeping*, 2005; 7:1-13.
4. Dong Ju Son et al., Therapeutic application of anti-arthritis, pain-releasing, and anti-cancer effects of bee venom and its constituent compounds. *Journal of Pharmacology & therapeutics*, 2007; 115: 246-270.
5. Zouhour Limam et al., Extraction and characterization of chitin and chitosan from crustacean by-products: biological and physicochemical properties. *African Journal of Biotechnology*, 2011; 10(4): 640-647.
6. Dalmer S et al., Metabolism and biochemical/physiological roles of chondroitin sulfates: analysis of endogenous and supplemental chondroitin sulfates in blood circulation. *Standard journal of osteoarthritis*, 2007; 2: 21-29.
7. Kyle D Allen et al., Kinematic and dynamic gait compensations resulting from knee instability in a rat model of osteoarthritis. *Journal of arthritis research and therapy*, 2012; 14(78): 1-14.
8. A R Shikhman et al., Chondroprotective activity of N-acetylglucosamine in rabbits with experimental osteoarthritis. *Journal of ann rheum dis*, 2005, 64: 89-94.
9. Ravindra Babu S et al., Anti-Arthritic And Anti-Oxidant Activity Of Crab Shell Chitin And Bee Venom Melittin by Papain Induced Osteoarthritis in

Rabbits. *European Journal of Biomedical and Pharmaceutical Sciences*, 2017; 5(1): 421-428.

10. Nick J Willet *et al.*, Intra-articular injection of micronized dehydrated human amnion/chorion membrane attenuates osteoarthritis development. *Journal of arthritis therapy&research*, 2014; 16(47): 1-22.

11. Ravindra Babu S *et al.*, Anti-Arthritic And Anti-Oxidant Activity Of Crab Shell Chitin And Bee Venom Melittin by Papain Induced Osteoarthritis in Rabbits. *European Journal of Biomedical and Pharmaceutical Sciences*, 2017; 5(1): 421-428.

12. Patricia A.M. *et al.*, Zymographic techniques for the analysis of matrix metalloproteinases and their inhibitors. *Journal of Bio techniques*, 2005, 38: 78-83.

13. Carlos Fernandez-Patron *et al.*, Methods for analysis of matrix metalloproteinase regulation of neutrophil-endothelial cell adhesion. *Journal of biol.proced*, 2012; 4(1): 38-48.

14. R.P. Verma *et al.*, Biological, physiochemical and structural parameters used to derive QSAR equations 1 and 32 for the inhibition of MMP-I and MMP-9. *Journal of bio org.med.chem*, 2007; 15: 2223-2268.

15. Molecular weight guide of MMP's: textbook of zymography: pp:26.

16. Carole Bougault *et al.*, Protective role of frizzled-related protein B on matrix metalloproteinase induction in mouse chondrocytes. *Journal of arthritis research & therapy*, 2014; 16(137): 1-8.

17. Izabella cordeiro freire saad rached *et al.*, Anti-inflammatory effect of bee venom on antigen-induced arthritis in rabbits: influence of endogenous glucocorticoids. *Journal of ethnopharmacology*, 2010; 130: 175-178.

18. Amit Rastogi *et al.*, Role of autologous chondrocyte transplantation in articular cartilage defects: an experimental study. *Indian journal of orthopaedics*, 2013; 47(2): 129-134.

19. C. Boulocher *et al.* "Non-invasive in vivo quantification of the medial tibial cartilage thickness progression in an osteoarthritis rabbit model with quantitative 3d high resolution micro-MRI. *Journal of Osteoarthritis and cartilage*, 2007; 15: 1378-1387.

20. H A Alhadlaq *et al.*, Detecting structural changes in early experimental osteoarthritis of tibial cartilage by microscopic magnetic resonance imaging and polarised light Microscopy. *Journal of ann rheum dis*, 2004; 63: 709-717.

21. J. Mary Murphy *et al.*, Stem cell therapy in a caprine model of osteoarthritis. *Journal of arthritis & rheumatism*, 2003; 48(12): 3464-3474.