

Case Report

Isolated Acrania in the Presence of Amniotic Band Syndrome

Lei Li, MD, PhD; Sandra Cerda, MD; David Kindelberger, MD;
Jing Yang, MD, PhD; Carmen Sarita-Reyes, MD*

Department of Pathology and Laboratory Medicine, Boston Medical Center, Boston, MA

Acrania is an extremely rare congenital developmental anomaly. It is often confused with another disease entity, anencephaly. Even though these two developmental defects often occur simultaneously, they are believed to have different pathogenic mechanisms. We report the case of a 22-year-old woman with an unremarkable first trimester pregnancy who delivered a demised male fetus at 16 weeks gestation. External and microscopic examination of the fetus revealed normal development in all internal organs. The brain was covered by leptomeninges only, with an absence of skull and overlying skin. Additionally, both the fetus and placenta showed evidence of amniotic band syndrome. A diagnosis of isolated acrania in the presence of amniotic band syndrome was made.

The exact etiology of acrania is not well understood. Two popular theories suggest that amniotic bands or a migration failure of the ectodermal mesenchyme may play a role in the pathogenesis. We believe that isolated acrania may represent a group of developmental anomalies which share a common ultimate outcome: absence of the neurocranium with relatively minor effects on brain development.

[N A J Med Sci. 2017;10(3):100-102. DOI: 10.7156/najms.2017.1003100]

Key Words: *acrانيا, anencephaly, acalvaria, amniotic band syndrome*

INTRODUCTION

Acrania is an extremely rare lethal embryonic developmental anomaly. It is characterized by partial or complete absence of the neurocranium, while the brain parenchyma development is less affected.¹ The pathogenesis of acrania is unknown. Genetic counseling is often challenging, because there is no evidence for a specific genetic contribution due to the extreme rarity and sporadic nature of the entity. Acrania is often confused with another congenital developmental disorder, anencephaly, which is defined as the congenital absence of the cranial vault, with the cerebral hemispheres completely missing or reduced to small masses.² These similar-sounding conditions differ significantly in terms of their pathogenesis, clinical presentations and risks for recurrence in subsequent pregnancies. In most cases, acrania coexists with anencephaly (approximately 1: 10,000 births), while the incidence of isolated acrania without anencephaly is exceedingly rare (the true incidence is unknown) with only a few cases reported worldwide in the English literature.³⁻⁸

CASE PRESENTATION

A 22-year old primigravida woman at 16 weeks gestation presented to the emergency department (ED) with abdominal pain and vaginal bleeding. Her past medical history is significant for polycystic ovarian syndrome and she is a

current smoker. There was no family history of congenital anomalies known to the patient. All prenatal test results (including genetic testing) were unremarkable and her last prenatal visit, four weeks prior, was notable for good fetal movement and fetal heart rate. Her pregnancy was uneventful until one week before her ED presentation, when she was physically assaulted. A bedside ultrasound examination revealed no fetal activity, and she subsequently delivered a deceased male fetus with minimal maceration. External examination of the fetus revealed complete absence of the cranial bones (**Figure 1**). The exposed brain tissue was covered by a thin layer of leptomeninges, appeared normally formed, and weighed 25.4 grams, consistent with a gestational age of 16-17 weeks. The brain was poorly preserved which precluded an optimal evaluation of the microscopic developmental parameters by the neuropathologist. The left hand of the fetus showed four digits and five metacarpal bones (confirmed by X-ray). The right forefoot was absent with only a portion of the right calcaneum (0.5 cm) present. The remaining bones and facial structures were within normal limits. A suspected amniotic band was noted arising from the umbilical cord with the proximal end inserted in the placental disc. Gross examination of internal structures, along with microscopic examination of all organs including brain and spinal cord were within normal limits. Cytogenetic studies revealed a normal male karyotype (46, XY). A diagnosis of isolated acrania with amniotic bands was made based on the above findings.

Received: 06/15/2017; Revised: 07/14/2017; Accepted: 07/19/2017

*Corresponding Author: 670 Albany Street, Department of Pathology and Laboratory Medicine, Boston Medical Center, Boston, MA 02118.
(Email: Carmen.Sarita-Reyes@bmc.org)

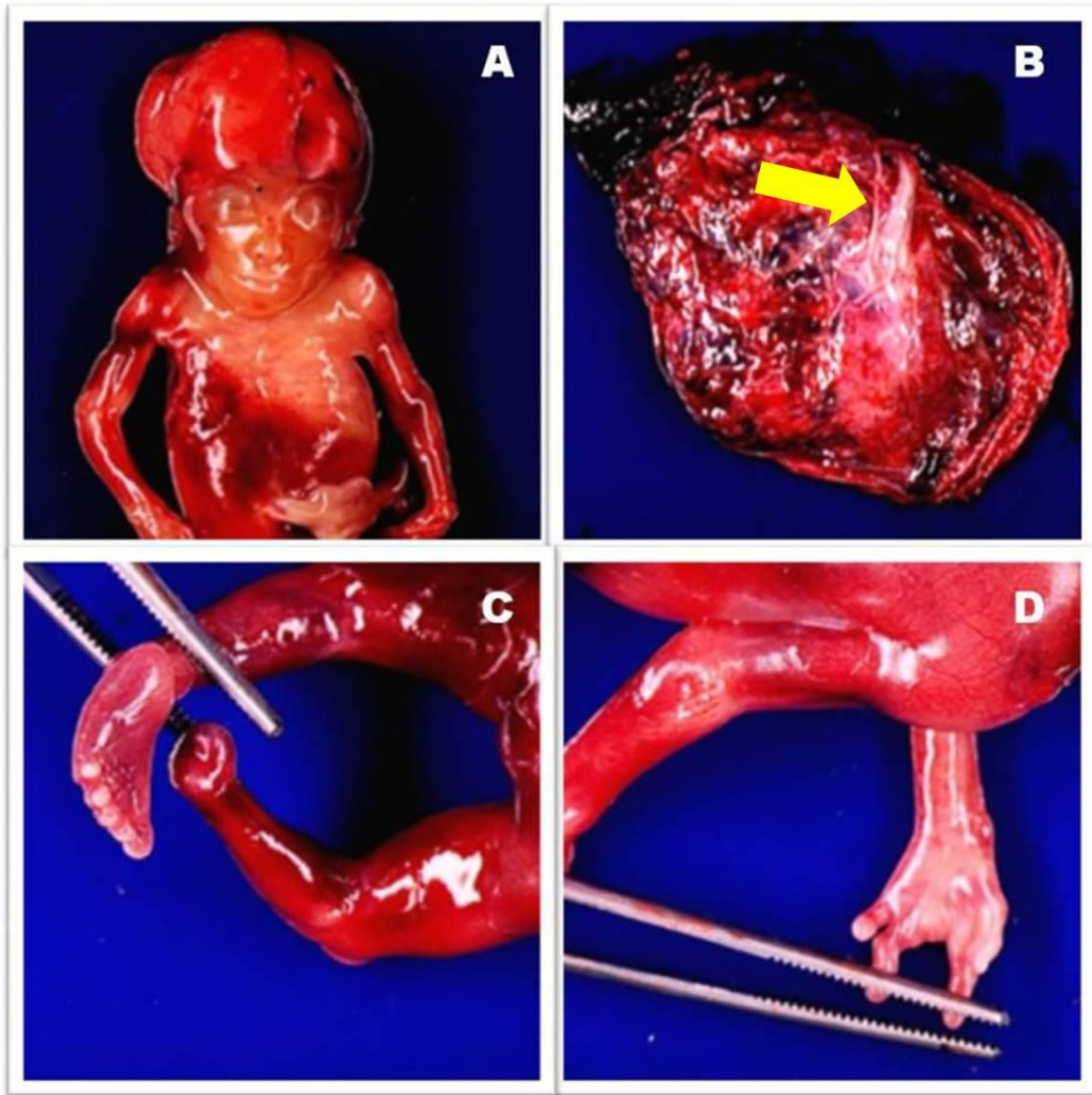


Figure 1. Gross examination of a 16w3d old intrauterine demised male fetus and placenta. **A.** Normal appearing fetus externally with the exception of the brain, which has complete absence of the neurocranium. **B:** A possible amniotic band, indicated by a yellow arrow, is present in the placenta arising from the umbilical cord. **C.** The right forefoot is completely absent **D.** The left hand shows only 4 digits.

DISCUSSION

The etiology of isolated acrania is not well understood, largely due to its low incidence. The two most popular hypotheses suggest that mechanical disruption by amniotic bands or migration failure of the ectodermal mesenchyme may play important roles in the disease process.⁹⁻¹¹ The differential diagnosis of acrania is quite broad, especially if the diagnosis is made antenatally by fetal ultrasonography. The leading differential diagnoses include anencephaly, acalvaria, cephalocele, hydrocephaly and skeletal dysplasia (e.g. osteogenesis imperfecta). The latter three disease processes have more pronounced differences from acrania and are not discussed in this case report. It is critical to reach the appropriate diagnosis for proper obstetrical management and

counseling, since some of the conditions are compatible with life, while others like acrania are universally lethal. Some of these conditions also have a genetic component as part of their pathogenetic mechanisms, potentially impacting future pregnancies.

Anencephaly is a type of neural tube defect (NTD). It occurs when the cranial portion of the neural tube fails to close during early embryogenesis. The affected fetus usually lacks cerebral hemispheres and the remaining neuro-vascular structure is covered by a thin layer of membrane without the presence of overlying skin, bone, or meninges. The majority of affected fetuses do not survive more than a few hours after birth.

Acalvaria, by definition, is the absence of the flat bones and dura matter of the cranial vault. Brain parenchyma is directly covered by skin. Because of the lack of protection by the overlying bone structures, most affected fetuses do not survive past birth. However, there are rare cases of survival after birth reported without long term follow up studies.¹²⁻¹³ The pathogenesis of acalvaria is proposed to be a migration defect of mesenchymal tissue underlying the ectoderm. Therefore it is considered to be a post-neurulation anomaly, a later-occurring stage of developmental defect than anencephaly. Acrania, on the other hand, is not only a lack of the flat bones, but also absence of the overlying skin layer, necessitating defects in both mesenchymal migration and ectodermal differentiation. One can argue that without proper mesenchymal tissue migration, ectodermal differentiation can be affected, causing the phenotypic appearance of acrania. That is certainly plausible. More research is needed to address these issues.

In the few published case reports of isolated acrania, the majority of the affected mothers presented with elevated serum α -fetoprotein (AFP) levels and the diagnosis of acrania was subsequently made via fetal ultrasonography followed by external examination of the fetus after delivery. Some affected fetuses showed concurrent spina bifida along with the absence of cranial bones with or without defects in brain development.^{3,10} Spina bifida is a well-known developmental anomaly within the spectrum of NTDs, as is anencephaly. Therefore, we suspect some of the reported acrania cases might actually represent anencephaly. However, there is no consensus as to how much brain tissue must be present when making the diagnosis of acrania.

It is worth mentioning that in several of the case reports, as with our patient, acrania is observed in the presence of amniotic band syndrome.^{9,14-16} Amniotic bands are proposed to be caused by maternal trauma, which leads to rupture of the amniotic membrane and then strand formation. These strands may encircle fetal parts and compromise vascular supply. If the encircling strands form sufficiently early in gestation, spontaneous abortion may happen. If strand formation occurs later in fetal development, amputation or other structural defects may be seen. In our patient as well as in other acrania cases with amniotic band syndrome, defects in both early (acrania) as well as in later developmental stages (amputation of digits and cleft palate/lips) are seen together. We propose an alternative explanation for these cases such that amniotic bands constrict around the head when the development is near completion, and cause the already formed bone and skin to degenerate, while leaving the brain parenchyma relatively unaffected. Acrania has also been associated with Adams-Oliver syndrome, which is characterized by both abnormalities in scalp skin development (aplasia cutis congenita) and malformations of the limbs.^{4,17} Some affected fetuses also followed the acrania to anencephaly sequence.^{18,19} These findings together underscore both the complexity of this process and the need for greater understanding of its mechanisms.

In our opinion, isolated acrania without anencephaly may represent a collection of several congenital developmental defects which share a common phenotype: absence of the flat bones of the cranial vault, while brain development is less affected. It has been reported that there is no increased risk of congenital anomalies in subsequent pregnancies. Additional studies are needed to provide a better understanding of the pathogenesis of this rare anomaly, and consensus needs to be reached regarding the diagnostic criteria for isolated acrania.

CONFLICT OF INTEREST

The authors declare that there is no conflict of interest.

ACKNOWLEDGEMENTS

The authors thank Dr. Reine Gedeon for helping the external examination and photograph the demised fetus.

FUNDING ACKNOWLEDGEMENTS

No external or internal funding for this study.

REFERENCES

- Mannes EJ, Crelin ES, Hobbins JS, Viscomi GN, Alcebo L. Sonographic demonstration of fetal acrania. *AJR Am J Roentgenol.* 1982;139:181-182.
- Lemire RJ, Siebert JR. Anencephaly: its spectrum and relationship to neural tube defects. *J Craniofac Genet Dev Biol.* 1990;10:163-174.
- Bianca S, Ingegnosi C, Auditore S, et al. Prenatal and postnatal findings of acrania. *Arch Gynecol Obstet.* 2005;27:256-258.
- Chitayat D, Meunier C, Hodgkinson KA, Robb L, Azouz M. Acrania: a manifestation of the Adams-Oliver syndrome. *Am J Med Genet.* 1992;44:562-566.
- Gorgal R, Ramalho C, Brandao O, Matias A, Montenegro N. Revisiting acrania: same phenotype, different aetiologies. *Fetal Diagn Ther.* 2011;29:166-170.
- Vergani P, Ghidini A, Sirtori M, Roncaglia N. Antenatal diagnosis of fetal acrania. *J Ultrasound Med.* 1987;6:715-717.
- Weissman A, Diukman R, Auslender R. Fetal acrania: five new cases and review of the literature. *J Clin Ultrasound.* 1997;25:511-514.
- Sabat S, Kulkarni S, Sangneria M. Acrania Without Anencephaly. *The Internet Journal of Gynecology and Obstetrics.* 2008;11.
- Chen CP, Chang TY, Lin YH, Wang W. Prenatal sonographic diagnosis of acrania associated with amniotic bands. *J Clin Ultrasound.* 2004;32:256-260.
- Kwon THK, Jim; Jeanty, Philippe. Acrania: Review of 13 Cases. *The Fetus.* 1991;1.
- Kaya H, Sezik, M., Özkaya, O., Aydin, A.R. Fetal acrania at term. *Perinatal Journal.* 2004;12:96-98.
- Kurata H, Tamaki N, Sawa H, et al. Acrania: report of the first surviving case. *Pediatr Neurosurg.* 1996;24:52-54.
- Khadiilkar VV, Khadiilkar AV, Nimbalkar AA, Kinnare AS. Acalvaria. *Indian Pediatr.* 2004;41:618-620.
- Chen CP, Tzen CY, Chang TY, Yeh LF, Wang W. Prenatal diagnosis of acrania associated with facial defects, amniotic bands and limb-body wall complex. *Ultrasound Obstet Gynecol.* 2002;20:94-95.
- Cincore V, Ninios AP, Pavlik J, Hsu CD. Prenatal diagnosis of acrania associated with amniotic band syndrome. *Obstet Gynecol.* 2003;10:1176-1178.
- He P, Yang Y, Li DZ. Acrania associated with amniotic bands in a fetus. *J Obstet Gynaecol.* 2012;32:397-398.
- Caksen H, Kurtoglu S. A case of Adams-Oliver syndrome associated with acrania, microcephaly, hemiplegia, epilepsy, and mental retardation. *Acta Neurol Belg.* 2000;100:252-255.
- Bronshtein M, Ornoy A. Acrania: anencephaly resulting from secondary degeneration of a closed neural tube: two cases in the same family. *J Clin Ultrasound.* 1991;19:230-234.
- Cafici D, Sepulveda W. First-trimester echogenic amniotic fluid in the acrania-anencephaly sequence. *J Ultrasound Med.* 2003;22:1075-1079; quiz 80-81.