

Osica Piotr, Osica Karolina, Janas Naze Anna. Surgical treatment of the patient with compound odontoma located in the mandible - a case report. *Journal of Education, Health and Sport*. 2017;7(12):545-552. eISSN 2391-8306. DOI <http://dx.doi.org/10.5281/zenodo.1133860>
<http://ojs.ukw.edu.pl/index.php/johs/article/view/5175>
<https://pbn.nauka.gov.pl/sedno-webapp/works/843182>

The journal has had 7 points in Ministry of Science and Higher Education parametric evaluation. Part B item 1223 (26.01.2017).
1223 Journal of Education, Health and Sport eISSN 2391-8306 7

© The Authors 2017;

This article is published with open access at Licensee Open Journal Systems of Kazimierz Wielki University in Bydgoszcz, Poland

Open Access. This article is distributed under the terms of the Creative Commons Attribution Noncommercial License which permits any noncommercial use, distribution, and reproduction in any medium, provided the original author(s) and source are credited. This is an open access article licensed under the terms of the Creative Commons Attribution Non Commercial License

(<http://creativecommons.org/licenses/by-nc/4.0/>) which permits unrestricted, non commercial use, distribution and reproduction in any medium, provided the work is properly cited.
This is an open access article licensed under the terms of the Creative Commons Attribution Non Commercial License (<http://creativecommons.org/licenses/by-nc/4.0/>) which permits unrestricted, non commercial use, distribution and reproduction in any medium, provided the work is properly cited.
The authors declare that there is no conflict of interests regarding the publication of this paper.
Received: 01.12.2017. Revised: 15.12.2017. Accepted: 29.12.2017.

SURGICAL TREATMENT OF THE PATIENT WITH COMPOUND ODONTOMA LOCATED IN THE MANDIBLE - A CASE REPORT

Piotr Osica PhD¹, Karolina Osica PhD Stud.², Anna Janas-Naze PhD Assoc. Prof.¹

Piotr Osica ORCID: 0000-0002-6436-5442

Karolina Osica ORCID: 0000-0003-3983-8516

Anna Janas-Naze ORCID: 0000-0001-6885-4457

¹Department of the Oral Surgery, Central Clinical Hospital, Medical University of Lodz

Head of the Department: Anna Janas- Naze, PhD, Assoc. Prof.

²Department of the General Dentistry, Central Hospital, Medical University of Lodz

Head of the Department: Jerzy Sokolowski, PhD, Prof.

Corresponding author: Piotr Osica

Department of Oral Surgery, Medical University of Lodz

92-213 Łódź, ul. Pomorska 251, tel. 42 675 75 29

The article is financed by Medical University of Lodz as a part of statutory activity nr 503/2-163-01/503-01

Abstract

The article describes case of a 20-year-old patient who had been treated surgically due to compound odontoma of the mandible in the area of teeth 32- 34.

Key words: tumor-like lesions, complex odontoma, compound odontoma

Introduction

Pathological lesions of jaws in most cases can lead to disorders in teeth eruption in children. One of the dento-occlusal disturbances, leading to eruption complications can be odontomas.

Odontomas represent more than 70% of all odontogenic tumours [1] and belong to the group of benign lesions, comprising of odontogenic tissues. Most such lesions are asymptomatic and their discovery is usually based on routinely performed radiographs, ordered to children in the period of mixed dentition in case of absence of a tooth in the arch, after its physiological time of eruption [2].

Possible causes of odontomas in jaws are infections, genetic factors and traumas [3]. Odontomas belong to the tumour-like lesions group of hamartomas. WHO divides odontomas into 2 types: complex – when the dental tissues form a simple irregular mass occurring in a disorderly pattern and compound - built out of many small tooth like structures called the denticles. The majority of odontomas which are located in the anterior region of the maxilla are compound, while the great majority of odontomas located in the posterior areas, especially in the mandible, are complex odontomas [4].

Full knowledge of the eruption dates is essential for early detection of disturbances and assessing their possible causes. Very often, the causes of dislodgement and over-retention of primary teeth can be odontomas.

Case report

The 25 y.o. patient was referred by an orthodontist to the Department of Oral Surgery for a consultation and treatment of a tumour, accidentally found on an OPG, in the region of teeth 32-34. The OPG showed a highly visible area in mandible, of irregular shape with slight peripheral radiolucency. For correct planning of the treatment, the patient was ordered to

perform a maxillary CT, which showed precisely the location of the tumour and allowed initial diagnosis of compound odontoma (fig. 1).

Medical history showed no additional pain, allergies to medications and no recent surgeries. No known family history of odontogenic anomalies. However, she has been presented with the diagnosis and treatment plan 2 years before at a private practice, but did not proceed with treatment.

Extra-oral examination showed no anomalies, however the intra-oral examination revealed a slight protuberance by palpation in the alveolar part of the mandible from the lingual side in the area of teeth 32 and 34. The location of the tumour determined the difficulty of the surgery and the risk of damaging the roots of premolars was very high.

After insightful analysis of the medical history, clinical examination and assessment of the OPG and CT, the surgery, consisting of enucleation of the tumour with sparing the 32, 33 and 34 teeth was planned.

The patient and legal guardian were presented with the treatment plan and possible complications. The patient has been informed of precise post-operation indications and the necessity of follow up visits the next day and 14 days after the surgery.

In local anesthesia, the periosteal flap has been cut and prepared from the lingual side in the area of teeth 36-32. The cortical plate of the bone has been removed between the roots of teeth 33 and 32 with a diamond bur, which allowed the access to the tumour (fig. 2, 3). The pathological lesion has been enucleated as a whole, double-checking radiologically and macroscopically (fig. 4). The wound has been provided with haemostatic sponge and sutured. The excised material has been sent for histopathological verification.

The appearance of pathological lesion, consisting of high number of small denticles in various state of development, characteristic radiological picture and location in lateral part of mandible allowed the initial diagnosis of compound odontoma. The intra and post-operative course was uneventful. The patient has been discharged in general good condition.

The patient reported for the follow-up visit the next day after the surgery, which showed small oedema of the operated area and confirmed the vitality of teeth 32-34. The wound healing was also uneventful. 2 weeks after the surgery the sutures have been removed and the vitality of premolars confirmed (fig. 5).

The result of histopathological examination confirmed the initial diagnosis of compound odontoma. The patient is still under the care of Department of Oral Surgery, with orthodontic treatment recommendation.

Discussion

Odontomas are benign lesions and usually painless. One of the most common disturbances related to them are the disorders in teeth eruption. Odontomas may be diagnosed at any age but they are usually detected during the first two decades of life. In the described case, the fact of finding the lesion so late does not surprise, however the lack of disturbance in eruption of teeth does [5].

Despite the benign character of odontomas, they should be removed even in the cases of no pain and visible odontogenic disturbances, due to the possibility of septic complications [6]. That is why the treatment of choice is surgical removal. After earlier imaging such as OPG or CBCT, basing on which the surgeon plans the treatment, the tumour is enucleated as a whole [7]. If the odontomas cause disturbances in eruption of permanent teeth, then before the surgery, the course of action regarding such teeth, such as surgical extraction, surgical extrusion and bringing the tooth into the arch, orthodontic extrusion with ligated spring, or observation and waiting for spontaneous eruption [8].

In described above case, the option of leaving the permanent teeth in the arch with preservation of the vitality, was our goal, but the risk of failure was very high. Intra-operational assessment of teeth 32-34 motility was very important key to the selection of treatment method. Whereas, according to us, the vitality check was reliable 2 weeks after the surgery. In case of its lack, the patient would have been referred to the Department of Endodontics for further treatment. In our case, the damage of bone surrounding the permanent teeth did not cause their motility, and there was no need for root canal treatment. Despite the difficulties, which are common in the preparation technique, the complete separation of the tumour from surrounding tissues was obtained, which in turn allowed for indisputable possibility of leaving the permanent teeth.

In most cases, in spite of characteristic macroscopic image of the odontoma and almost pathognomonic radiological image [2], the lesions should always be histopathologically verified [9]. Despite very rare reports of odontomas' relapse after primary enucleation, in case of possible lack of total excision, the decision of leaving or extracting the permanent teeth should be analysed in collaboration with an orthodontist. Lack of total excision can also be a cause of inflammation in the operated area.

References:

- [1] O. Erdogan, O. Keceli, H. Oztunc, B. Evlice, H. A. Altug, and O. Günhan, "Compound odontoma involving the four quadrants of the jaws: A case report and review of the literature.," *Quintessence Int.*, vol. 45, no. 4, pp. 341–4, 2014.
- [2] M. Abdul, K. Pragati, and C. Yusuf, "Compound composite odontoma and its management.," *Case Rep. Dent.*, vol. 2014, p. 107089, 2014.
- [3] V. Vasudevan, V. Manjunath, and R. M. Bavle, "Large erupted complex odontoma Introduction.," *J. Indian Acad. Oral Med. Radiol.*, vol. 21, no. 2, pp. 92–97, 2009.
- [4] T. Kaczmarzyk, J. Stypułkowska, R. Tomaszewska, J. Czopek, "Nowotwory zębopochodne i guzy nowotworopodobne kości szczękowych". I. Koziół (red.), Warszawa: Kwintesencja, pp. 107-115, 2009
- [5] A. Mathew, P. Shenai, L. Chatra, K. Veena, P. Rao, and R. Prabhu, "Compound odontoma in deciduous dentition.," *Ann Med Heal. Sci Res*, vol. 3, no. 2, pp. 285–287, 2013.
- [6] G. Conti, L. Franchi, M. Camporesi, and E. Defraia, "Treatment protocol for the impaction of deciduous maxillary anterior teeth due to compound odontoma," *Eur. J. Paediatr. Dent.*, vol. 13, no. 4, pp. 337–341, 2012.
- [7] C. T. Da Costa, D. D. Torriani, M. A. Torriani, and R. B. Da Silva, "Central incisor impacted by an odontoma," *J. Contemp. Dent. Pract.*, vol. 9, no. 6, pp. 122–128, 2008.
- [8] P. Trisi, U. Preite, D. Tripodi, and D. Tartaro, "[Considerations on composite odontoma].," *Minerva Stomatol.*, vol. 38, no. 9, pp. 1003–1008, 1989.
- [9] D. J. Burden, J. G. McGimpsey, and A. Richardson, *Surgical and orthodontic management of compound odontoma.*, vol. 16, no. 7. 1989, pp. 311–312.

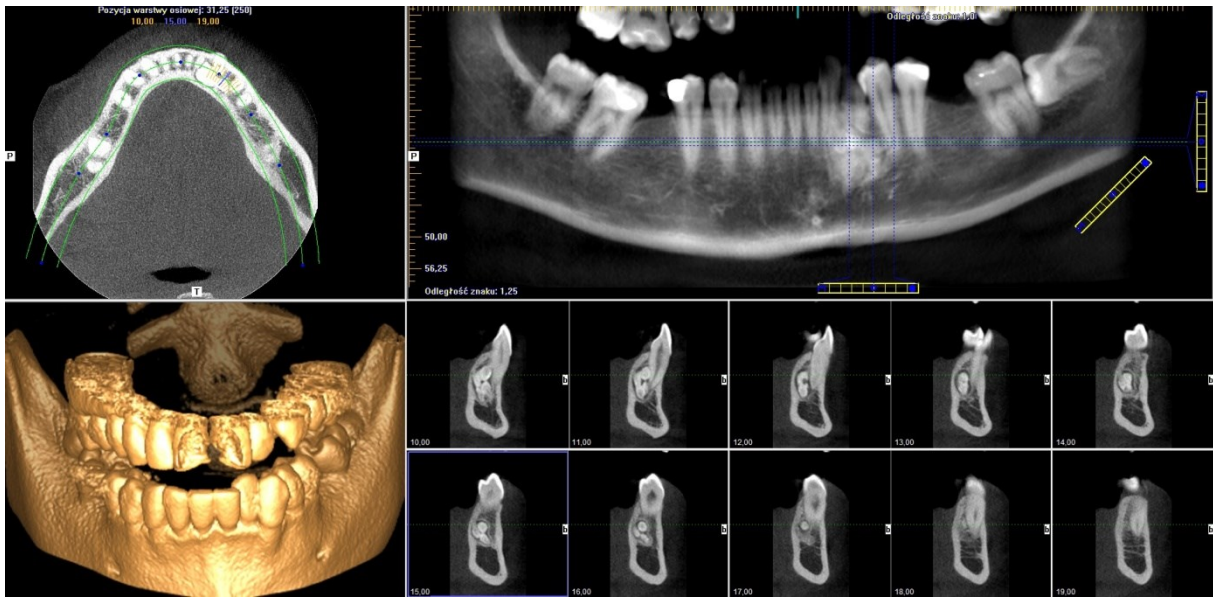


Fig. 1. Radiological imaging of the tumour.

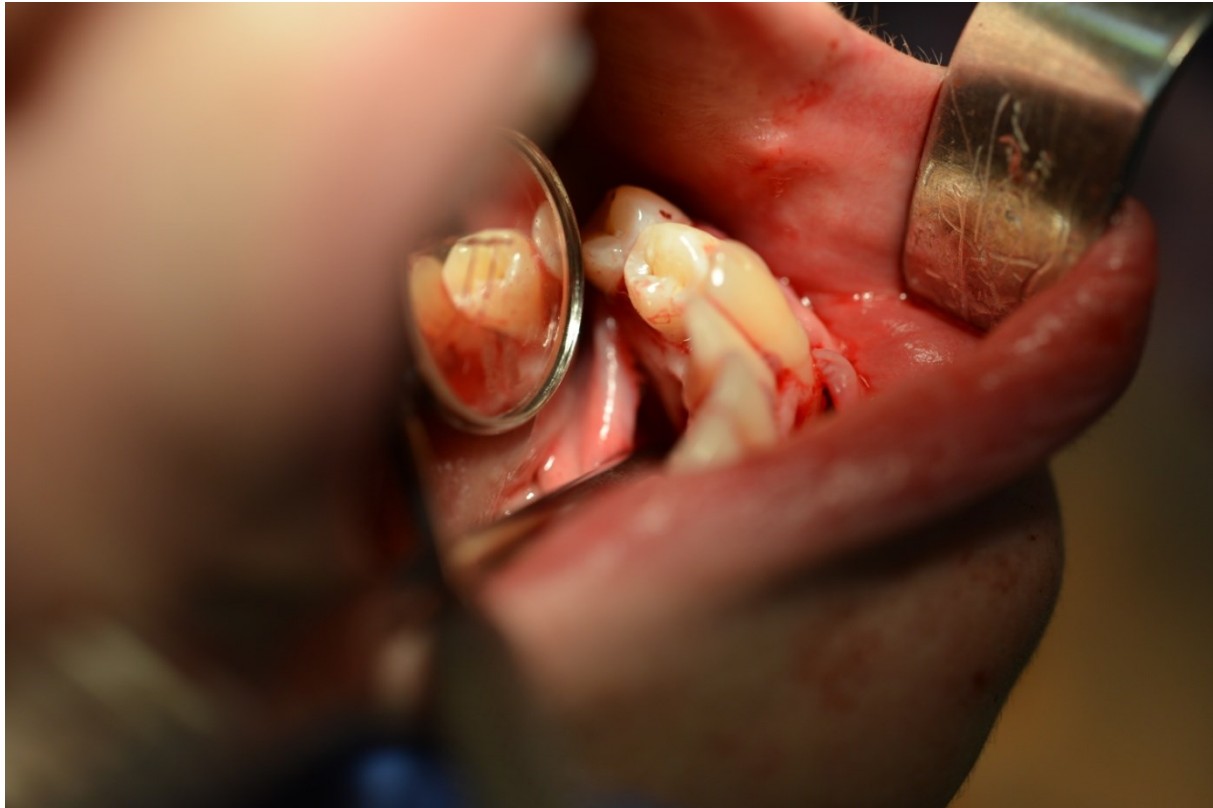

Fig.2. Mucoperiosteal flap, palatal view.

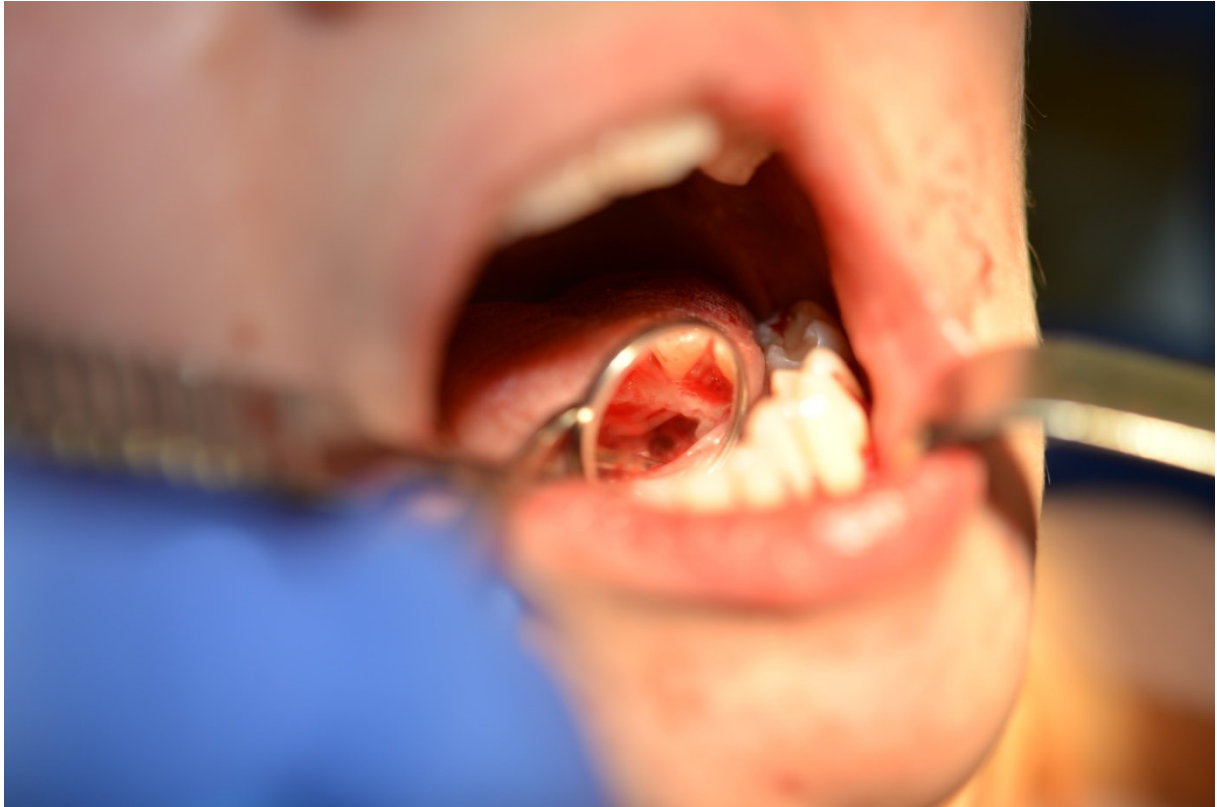

Fig. 3. Tumour bed.

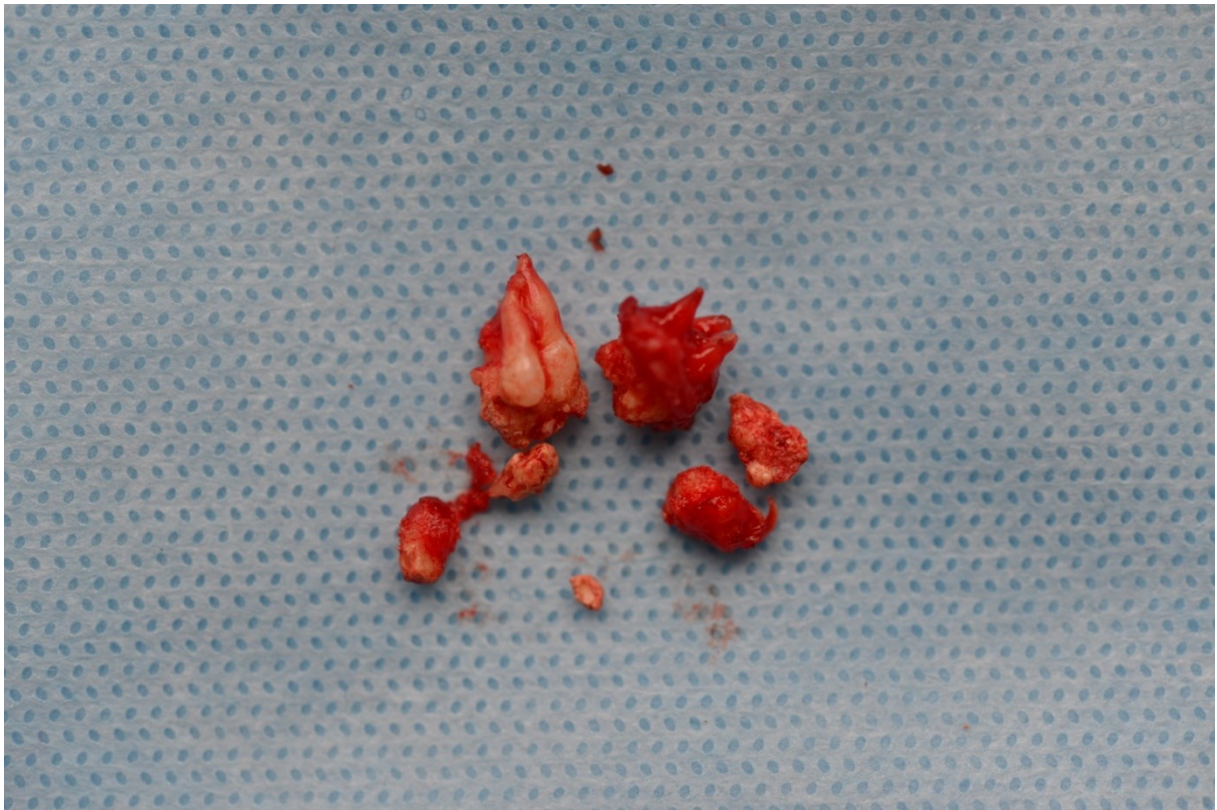

Fig.4. Odontomas.

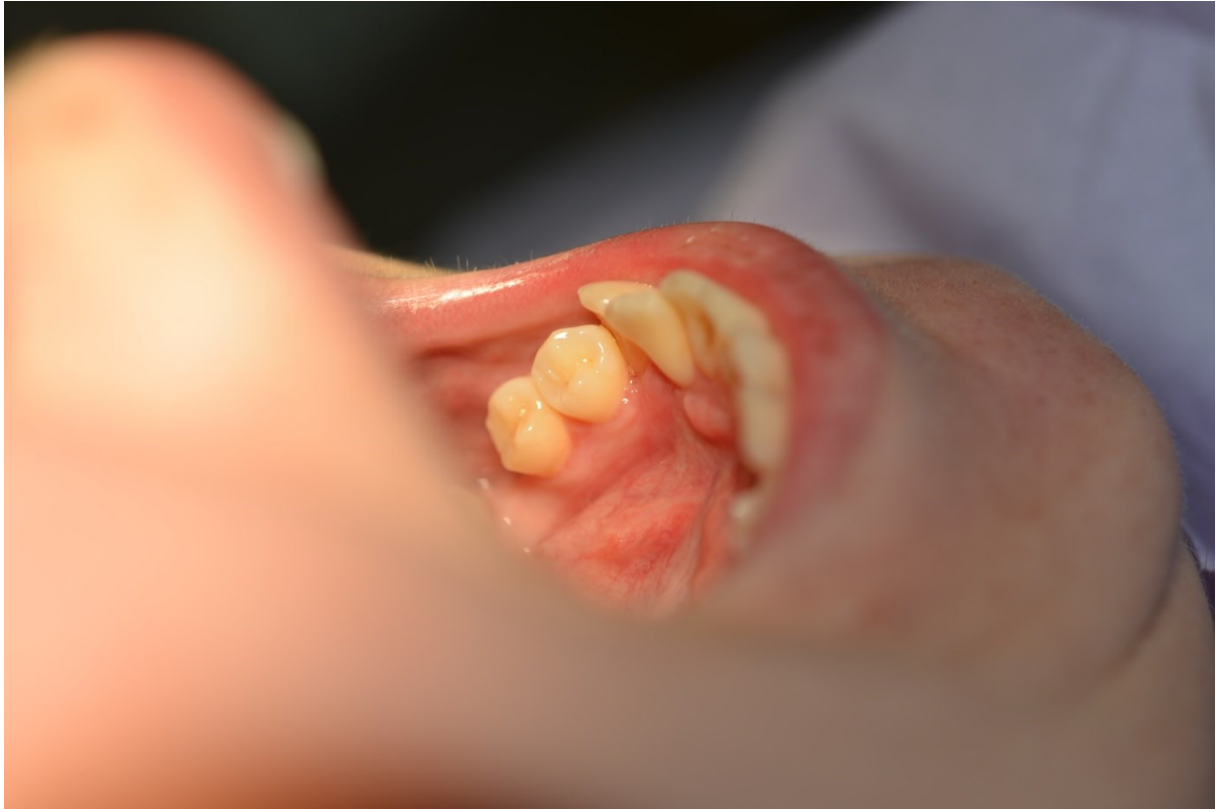

Fig. 5. Completely healed wound.