



Journal Homepage: - [www.journalijar.com](http://www.journalijar.com)

## INTERNATIONAL JOURNAL OF ADVANCED RESEARCH (IJAR)

Article DOI: 10.21474/IJAR01/18563

DOI URL: <http://dx.doi.org/10.21474/IJAR01/18563>



### RESEARCH ARTICLE

#### A SYSTEMATIC REVIEW OF PREOPERATIVE LOCALIZATION TECHNIQUES FOR PRIMARY HYPERPARATHYROIDISM SURGERY

Aqueel Waris

#### Manuscript Info

##### Manuscript History

Received: 20 February 2024

Final Accepted: 23 March 2024

Published: April 2024

#### Abstract

**Background:** Hyperactivity of the parathyroid gland is a major abnormality that can lead to bone loss and other serious disorders. For effective treatment, some preoperative approaches such as computed tomography, positron emission tomography, and nuclear medicine imaging tests exist.

**Methodology:** The methodology followed PRISMA guidelines, encompassing a thorough search of key databases (2008-2020) using specific keywords. Inclusion criteria emphasized diagnostic test design, primary hyperparathyroidism population, noninvasive imaging methods, comparative analyses, and histopathologic validation. Quality assessment utilized the QUADAS-2 tool, and data extraction was comprehensive, covering the study, participant characteristics, imaging techniques, and diagnostic metrics.

**Results:** Of the 14 selected papers, CT Scan, ultrasound, MRI, and nuclear medicine imaging test/ sestamibi scanning are highly cited and better preoperative localization techniques than others. The success rate of CT scans in preoperative localization in surgery for primary hyperparathyroidism had a wide range of 58 – 93%.

**Conclusion:** All the localization techniques have different success rates when used for preoperative localization in surgery for primary hyperparathyroidism. CT scan and MRI showed the highest success rate among all. Education in terms of effectiveness causes the least to no harm to the human body, must keep the cost affordable for the patients, how this therapeutic approach increases patient satisfaction, and how this approach assists in surgical planning should be considered.

Copy Right, IJAR, 2024,. All rights reserved.

#### Introduction:-

##### Background

Primary hyperthyroidism disease is very common in adult and elderly females. In 2018, 7 out of 1,000 adult females were affected by primary hyperthyroidism. The Scandinavian countries, the USA, followed by Europe, have a higher prevalence[1]. Compared to Asian countries, 0.4 to 8.4 per 100,000 individuals are affected. Patients are usually identified with co-morbidities like renal disease, osteoporosis, etc. According to WHO (World Health Organization), 0.4 million individuals die yearly due to primary hyperthyroidism as a secondary disease[2]. Primary hyperthyroidism is an endocrine disease in which a tumour is formed in the thyroid gland[3]. Secondary hyperparathyroidism nephritic diseases are the main cause. Tertiary parathyroidism is a chronic condition that

eventually causes a lack of responsiveness to blood calcium. In this state of disease, excessive production in terms of 100 to 1000 folds higher than the upper range of normal levels of parathyroid hormone is present in the blood[4]. These conditions can be treated and completely cured if diagnosed on time[5].

The hyperparathyroidism is a common disease and is increasing. Lack of minerals or other medication also influences the parathyroid mechanisms, leading to disease development. Symptoms may appear early or late[6]. This disease is primarily analyzed by blood screening for calcium, parathyroid hormones, renal function test, bone mineral density test, serum phosphate level, medical imaging of thyroid gland or another radiological test like scans are performed to confirm the presence of tumour [7]. To avoid postoperative complications, the localization of the disease or focal point of operation is identified and planned by the surgeon before the operation[8]. This systematic review aims to explore the role of preoperative imaging modality for the localization of primary hyperparathyroidism.

### **Research Questions**

1. Which localization techniques are generally used in surgery for primary hyperparathyroidism
2. What is the success rate of Computed Tomography (CT), Nuclear Medicine Imaging Test, Ultrasonography, and Magnetic Resonance imaging (MRI ) in preoperative localization in surgery for primary hyperparathyroidism
3. Which preoperative imaging modality for localization of primary hyperparathyroidism has high performance
4. Which localization techniques give better results when used for preoperative localization in surgery for primary hyperparathyroidism

### **Hypothesis:**

A better and more frequently cited preoperative localization technique in surgery regarding Primary Hyperparathyroidism gives better results in terms of accuracy and precision.

### **Literature Review:-**

Preoperative localization is very advantageous; the image guidance leads to reducing the long or improper incision and also assists in having accurate equipment like hand-held retractors, etc. 3D-guided images are usually developed in two modes, low and high frequency, which assists in making better decisions for the medical committee[9]. If diagnosed at an early stage, though, depending on the nature of growth and types of tumour, a series of medications can completely reverse the condition. However, the condition also needs surgical therapy to avoid the postoperative complications of the parathyroid gland. The preoperative localization approach is effective in reducing suffering and other damages[10]. The successful rate of operation rate is nearly 95% by the preoperative localization approaches such as CT scan, imaging ultrasound, etc. [11].

The 4D CT scan is widely used to determine the over-functioning of the quadrant of the parathyroid gland. This scan provides a detailed image of the neck with multiple sites. The result revealed that computed tomography, preferable to a 4D scan, is more effective or superior than ultrasound, Tc-99sestamibi scintigraphy[12].

Nuclear medicine imaging is a highly used technique to determine the primary hyperparathyroidism, mostly used in developed countries. Radioactive Substance inside the body is migrated into the parathyroid gland and absorbed. After 10 to 15 minutes, the picture of the neck, throat and chest region is taken from the gamma camera. The absorbed radioactive substances are generally shown brightly in pictures. [13].

The ultrasonography is an image produced by ultrasound waves to determine the internal structure of the body. The pathology of either tissue, bone or any other infection causing tissue injury is easily predicted by this approach. In thyroid and parathyroid gland study, the ultrasound helps to view the anatomical relationship of the parathyroid gland and other nearby structures in the neck[14].

Ultrasound elastography was one of the dynamic techniques during the 1990s and was frequently applied to determine the location of tumours in the parathyroid gland. The principle of this technique is to evaluate the degree of hardness of tissue through elasticity. Through tissue elasticity, the stage of disease is also determined. This approach is also effective in determining the per-operative localization of the parathyroid disease[15].

With the aim of minimally invasive parathyroidectomy, the positron emission tomography is used. It plays a significant role in adenoma-focusing exploration to assist surgeons in preoperative planning. This technique provides images revealing important information about anatomy. Positron emission tomography is also considered a nuclear medicine imaging technique that caused the development of a three-dimensional image of the internal part of the body[16].

Magnetic Resonance Imaging is one of the common techniques of imaging which is least recommended or recommended for severe conditions. This imaging technology develops pictures revealing the anatomy and physiology of the body parts in a detailed manner. This technology uses the magnetic field, magnetic field gradient, and radio waves at a string or high level to develop an accurate organ image[17].

## Methodology:-

### Search Strategy

To conduct a systematic review of preoperative localization techniques for primary hyperparathyroidism surgery, a comprehensive search strategy was employed, published between 2008 and 2020 in PubMed, Embase, and the Cochrane Library, to ensure a thorough review of the literature. The search strategy was based on a combination of specific keywords as (1) "primary hyperparathyroidism" OR "parathyroid adenoma," (2) "positron emission tomography" OR "PET" OR "single photon emission computed tomography" OR "SPECT" OR "scintigraphy" OR "scan" OR "ultrasonography" OR "ultrasound" OR "US" OR "computed tomography" OR "CT" OR "magnetic resonance imaging" OR "MRI," and (3) "detection" OR "localization" OR "diagnosis."

### Inclusion and Exclusion Criteria

Studies were included in this systematic review if they met the following criteria: (a) published between 2008 and 2020, (b) written in English, (c) focused on preoperative localization techniques for primary hyperparathyroidism surgery, and (d) provided sufficient information for quality assessment. Exclusion criteria included studies not meeting these criteria, review articles, case reports, and studies with inadequate data or methodology descriptions.

### Study Selection Process

The systematic selection process, in accordance with PRISMA guidelines, employed a comprehensive approach utilizing multiple databases, including PUBMED (n=2395), EMBASE (n=2235) and Cochrane Library (n=25). Initially, duplicate studies were removed through software and manual comparison. Subsequently, titles and abstracts were screened for relevance, and a meticulous evaluation of full-text articles followed, considering methodology, objectives, sampling type, data collection methods, and alignment with the research question.

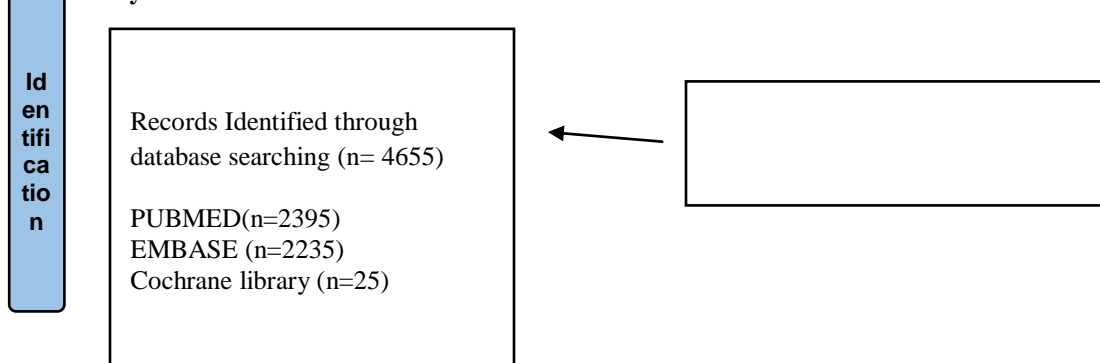
### Quality Assessment

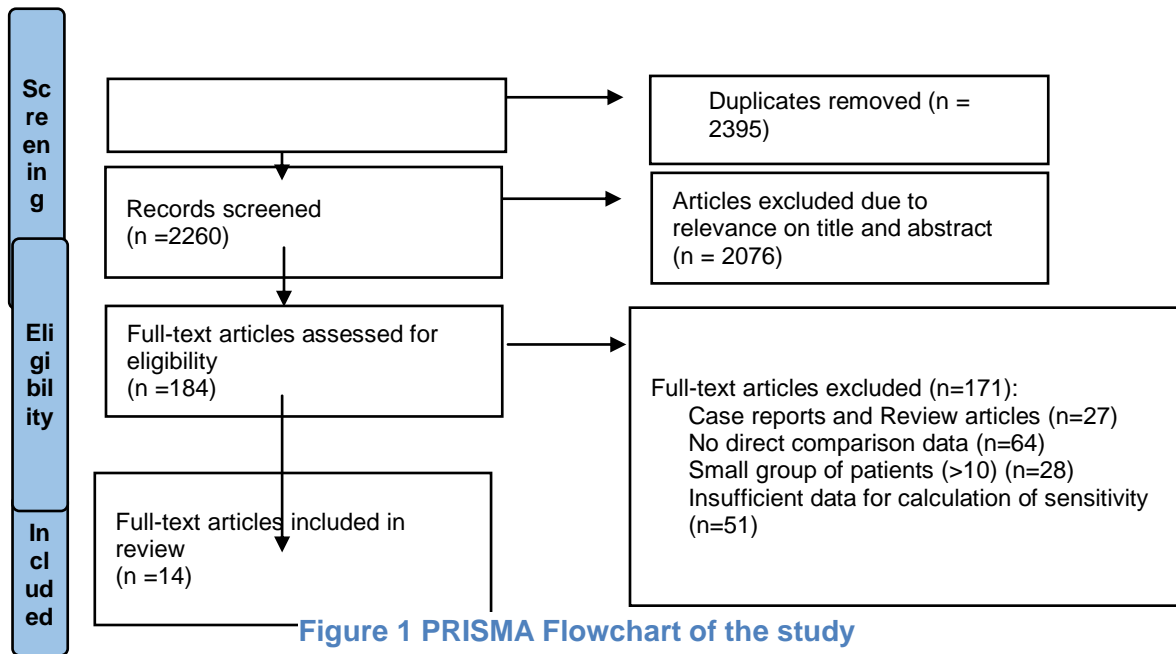
The quality assessment of the included studies was performed using the Quality Assessment of Diagnostic Accuracy Studies (QUADAS-2) tool. This tool evaluates the risk of bias and the applicability of primary diagnostic accuracy studies. QUADAS-2 assesses four key domains: patient selection, index test, reference standard, and flow and timing.

### Data Extraction

Our approach was marked by meticulous attention to detail, objectivity, and precision during the data extraction phase. Participant characteristics, including demographic data such as age and gender, were carefully documented to establish the profile of the patient population under investigation. Specific details pertaining to the preoperative localization techniques assessed in each study were meticulously recorded, encompassing the types of imaging modalities utilized and any variations or innovations in their application.

### Prisma Study





**Results:-**

**Chapter 4: Results**

**Table 1:-** Sample size and success rate for preoperative localization technique by using PET/CT Scan test.

**Table 1:-** Pet/Ct Scan Test.

S. NO	AUTHOR	SAMPLE SIZE	SUCCESS RATE		P VAL / SIG VAL	CONF. INTERVAL %
			No	%		
		No	No	%	<0.05	95
1	Lundstroem et al (2016)	43	40	93	<0.05	95
2	Becker et al (2020)	54	50	92	<0.05	95
3	Acar et al., (2020)	17	9	53	<0.05	95
4	Jia et al., (2020)	98	78	80	<0.05	95
5	Ramírez et al (2019)	29	23	78	<0.05	95
6	Memeh et al., (2019)	26	23	69	<0.05	95
7	Pretet et al., (2020)	50	47	94	<0.05	95
8	Boccalatte et al., 2019	619	495-619	80-100	<0.05	95
9	Christakis et al (2019)	12	7	58	<0.05	95

Table 1 shows the sample size of nine studies and the success rate of CT scans in these studies.

**Table 2:-** Sample size and success rate for preoperative localization technique by using Ultrasound test.

TABLE 2: TEST: ULTRASOUND						
S. NO	AUTHOR	SAMPLE SIZE	SUCCESS RATE %		P VALUE / SIG VALUE	CONFIDENCE INTERVAL %
			No	%		
1	de Maissin et al., (2020)	273	262	96	<0.05	95
2	Broome et al. (2020)	1485	1396	94	<0.05	95
3	Stern et al (2018)	365	277	76%	<0.05	95
4	Al-Kurd et al (2018)	398	318	80%	<0.05	95
6	Coelho et al. (2016)	55	48	87%	<0.05	95

7	Munk Roni et al (2008)	53	37	70	<0.05	95
8	Ramírez et al (2019)	29	19	67	<0.05	95

Table 2 shows the sample size of eight studies and the success rate of ultrasound in these studies.

**Table 3:-** Sample size and success rate for preoperative localization technique by using MRI test.

**Table 3:-** Tests: MRI.

S. NO	AUTHOR	SAMPLE SIZE (NO)	SUCCESS RATE %		P VALUE / SIG VALUE	CONF. INTERVAL
			No	%		
1	Munk Roni et al (2008)	16	16	100	<0.05	95
2	Becker et al (2020)	54	50	92	<0.05	95
3	Jia et al. (2020)	98	77	79	<0.05	95
4	Acar et al. (2020)	25	20	84	<0.05	95
5	Memeh et al. (2019)	26	17	85	<0.05	95

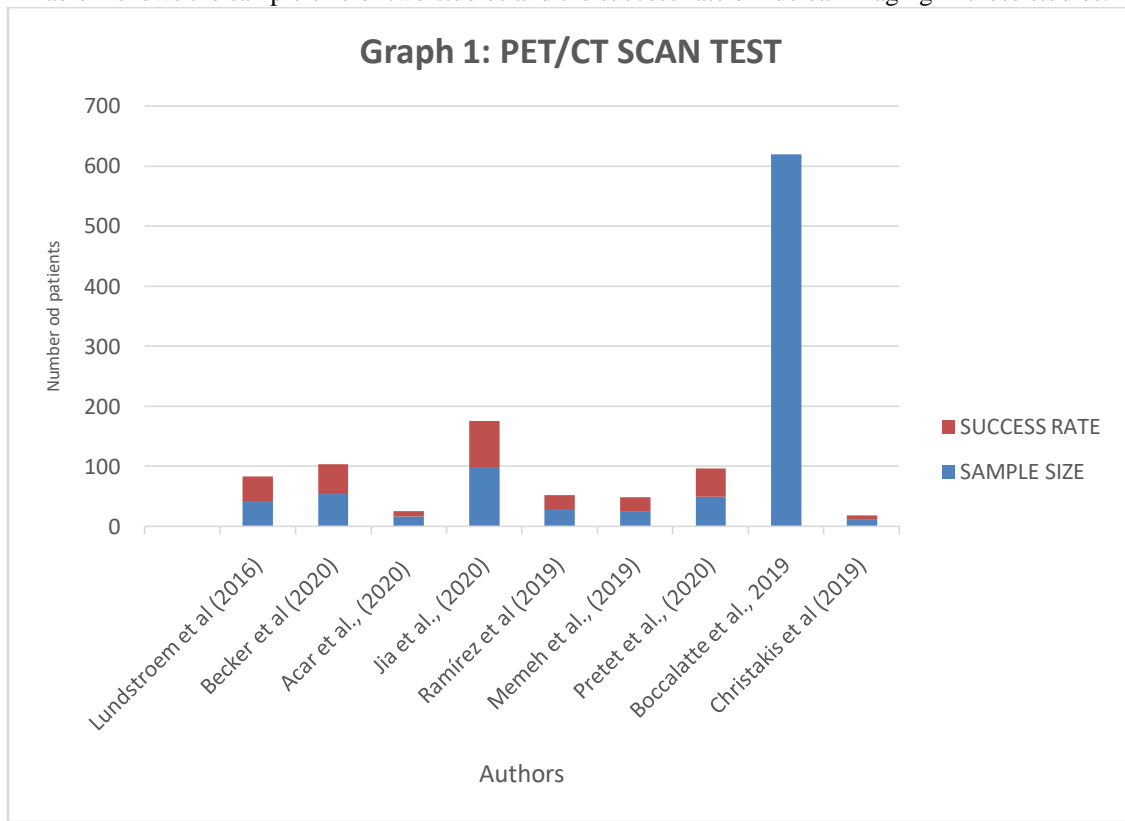
Table 3 shows the sample size of five studies and the success rate of MRI in these studies.

**Table 4:-** Sample size and success rate for preoperative localization technique by using Nuclear Medicine Imaging Test/Sestamibi Scanning.

**Table 4:-** Test: Nuclear Medicine Imaging Test/ Sestamibi Scanning.

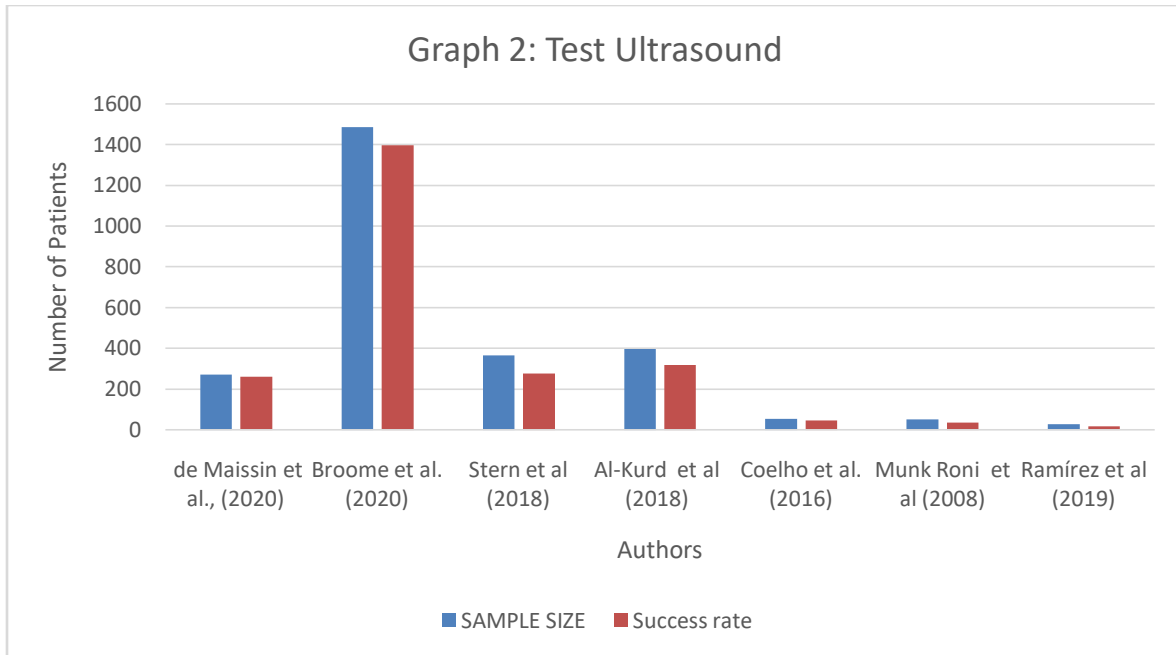
S. NO	AUTHOR	SAMPLE SIZE	SUCCESS RATE		P VALUE / SIG VALUE	CONF. INTERVAL
			No	%		
1	Al-Kurd et al (2018)	398	318	80	<0.05	95
2	Munk Roni et al (2008)	53	37	70	<0.05	95

Table 1 shows the sample size of two studies and the success rate of nuclear imaging in these studies.



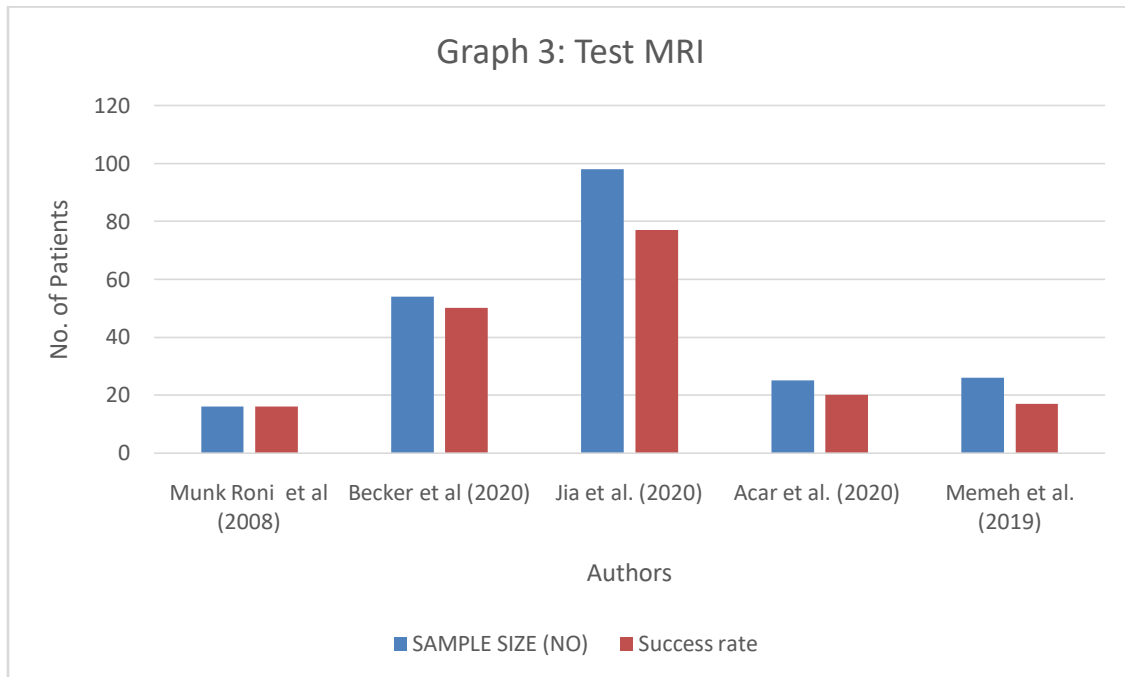
**Graph 1:-** Sample size and success rate PEC/CT scan.

Graph 1 shows the visual results of CT scan performance success rate in the cited studies with their sample size.



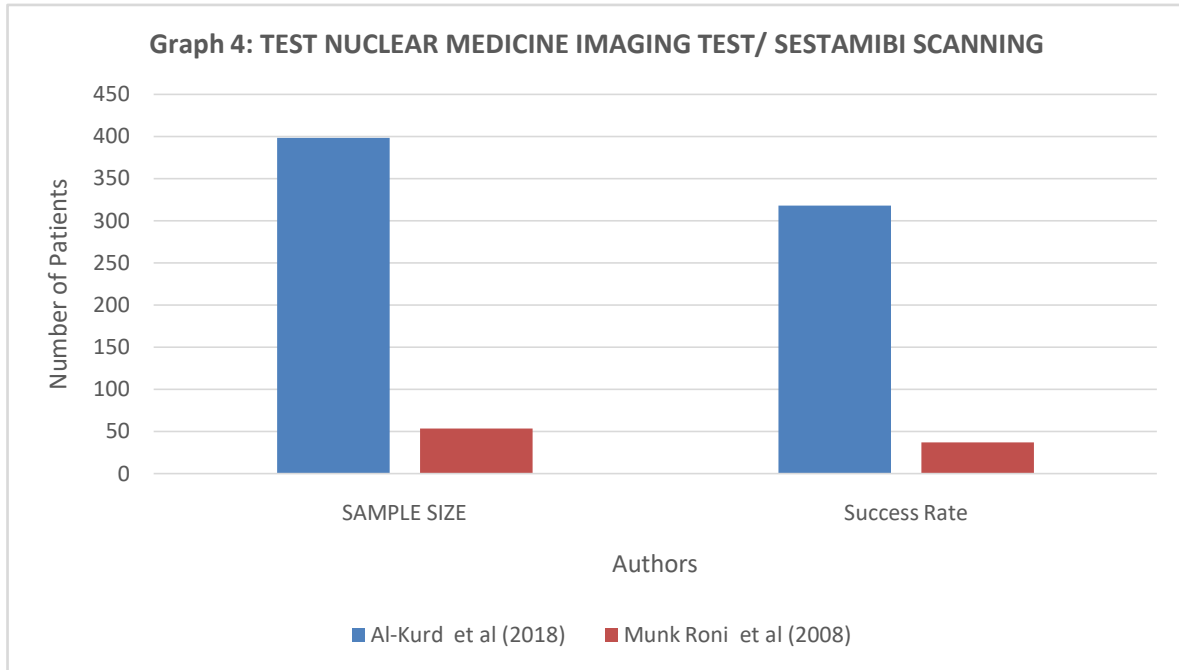
**Graph 2:-** Sample size and success rate for ultrasound

Graph 2 shows the visual results of ultrasound performance, and success rate in the cited studies with their sample size.



**Graph 3:-** Sample size and success rate for MRI.

Graph 3 shows the visual results of MRI performance success rate in the cited studies with their sample size.



**Graph 4:-** Sample size and success rate for nuclear medicine imaging test.

Graph 4 shows the visual results of nuclear medicine imaging performance success rate in the cited studies with their sample size.

### Discussion:-

Our PET/CT scan result demonstrates a 53% to 100% success rate. Similarly, Treglia et al. investigated the diagnostic effectiveness of FCH PET/CT in a meta-analysis involving 14 studies and 517 patients. In a per-patient study, the overall sensitivity and positive predictive value (PPV) were 95% and 97%, respectively, while in a per-lesion analysis, they were 92% and 92%, respectively[18]. In a different study by Guerin et al. [19], Kluijfhout et al. [3] and Berner et al. [20] compared dual-tracer SPECT with the US in 127 patients and found that SPECT was more accurate (83%) and sensitive (80-93%) than the US (sensitivity 60%, specificity 72%) in situations of uniglandular illness. Butt et al. discussed their experience using the US alone and reported that the parathyroid adenoma was correctly diagnosed in 98% of patients suited for targeted parathyroidectomy [21].

According to current review findings, ultrasound has a success rate for localizing adenoma that ranges from 67% to 96%. In a study evaluating the performance of ultrasound, Tay et al. [22] in 2016 and Solorzano et al. [23] in 2006 reported that the pooled sensitivity or detection rate was 76.1% and the positive predictive value (PPV) was 93.2% on a per-patient analysis. In a different investigation, Stern et al. [24] used ultrasonography to locate and estimate the location of 410 patients' parathyroid glands. According to the 2019 study by Treglia et al., US and MIBI performed similarly concerning sensitivity, specificity, and negative predictive value (NPV) on a patient-based analysis, as well as positive predictive value (PPV) and overall diagnostic accuracy (ADA) of 90% and 92% for US and MIBI, respectively[18]. This is in contrast to the results of the current study, which indicated that the US had a better success rate than MIBI (nuclear imaging).

According to the results of our study, MRI has the highest success rate for preoperative imaging of hyperthyroidism (79% to 100%). This outcome is comparable to Argiró et al.'s s83 comparison of 3T MR, scintigraphy, and MIBI. With sensitivity, specificity, positive predictive value (PPV), and negative predictive value (NPV) values of 97.8%, 97.5%, 93.7%, and 99.2%, MR localized 45/46 parathyroid glands and was able to identify six adenomas that MIBI was unable to see and two adenomas that were missed by ultrasonography. Michel et al.[25] also found that MRI is generally thought to have similar accuracy to other modalities in the detection of parathyroid lesions with a reported sensitivity of 63%-91[26].

According to the findings of our study, nuclear imaging test success rates range from 70% to 80%. In the meta-analysis by Wong et al., the cumulative sensitivity of nuclear imaging for the diagnosis of parathyroid glands was 86%, with a confidence interval of 81–90% [27]. Another Aygun et al. [70] study found that Sestamibi is often used in parathyroid scintigraphy, and many procedures can be used. Regarding the identification of the diseased gland by scintigraphy, the PPV rate is 74–100%, and the sensitivity rate is 44–89% [28] [29] [30].

The strength of this systematic review found that over the last 30 years, there has been a significant change in the profile of the patients being referred for parathyroidectomy. A systematic review of the current study compared the four most used techniques by patients for their localization and found their respective success rates, which can easily be investigated. The limitation of the systematic review is that most studies were excluded due to the non-availability of full-text articles, small group patients and mainly due to language limitations.

### Conclusion:-

Analyzing the four preoperative localization techniques for primary Hyperparathyroidism, CT scan, and MRI showed the highest success rate among all and are the most effective per-operative primary hyperthyroidism localizing approach. The previous articles researches demonstrate that the low dose of radiation, convenience and cost-effectiveness are human body friendly and give a clear image and detailed information of the anatomy and physiology of the parathyroid gland and closed zones. More research should be assessed for nuclear imaging tests as it has a comparable low success rate with respect to other techniques. The development of hybrid imaging methods like PET/MRI combines these two modalities to offer great anatomical resolution and physiologic data.

### References:-

- [1] S. D. Rao, "Epidemiology of parathyroid disorders," *Best Pract. Res. Clin. Endocrinol. Metab.*, vol. 32, no. 6, pp. 773–780, 2018.
- [2] S. K. Yadav, G. Johri, R. A. Bichoo, C. K. Jha, R. Kintu-Luwaga, and S. K. Mishra, "Primary hyperparathyroidism in developing world: a systematic review on the changing clinical profile of the disease," *Arch. Endocrinol. Metab.*, vol. 64, pp. 105–110, 2020.
- [3] K. L. Insogna, "Primary hyperparathyroidism," *N. Engl. J. Med.*, vol. 379, no. 11, pp. 1050–1059, 2018.
- [4] A. Srivastava, N. Verma, A. K. Singh, and G. C. Shivakumar, "Oral manifestation of hyperparathyroidism: A report of two cases," *J. Indian Acad. Oral Med. Radiol.*, vol. 30, no. 2, pp. 181–184, 2018.
- [5] A. L. M. Casarim, "Parathyroid Glands and Hyperparathyroidism: A General Overview," *Miner. Defic.-Electrolyte Disturb. Genes Diet Dis. Interface*, 2020.
- [6] F. K. I. Al-Mahdawi, A. S. Hassan, and W. A. W. Alsiadi, "PARATHYROID GLAND, ANATOMY, HISTOLOGY, AND PHYSIOLOGY (A SHORT REVIEW)," *Basrah J. Vet. Res.*, vol. 19, no. 1, 2020.
- [7] A. Palermo et al., "Clinical, biochemical, and radiological profile of normocalcemic primary hyperparathyroidism," *J. Clin. Endocrinol. Metab.*, vol. 105, no. 7, pp. e2609–e2616, 2020.
- [8] S. Stern, S. Tzelnick, A. Mizrachi, M. Cohen, T. Shpitzer, and G. Bachar, "Accuracy of neck ultrasonography in predicting the size and location of parathyroid adenomas," *Otolaryngol. Neck Surg.*, vol. 159, no. 6, pp. 968–972, 2018.
- [9] Y. Wang and D. E. Ladie, "Parathyroidectomy," 2020.
- [10] J. Chow, J. Rahman, J. C. Achermann, M. T. Dattani, and S. Rahman, "Mitochondrial disease and endocrine dysfunction," *Nat. Rev. Endocrinol.*, vol. 13, no. 2, pp. 92–104, 2017.
- [11] A. M. Laird and S. K. Libutti, "Minimally invasive parathyroidectomy versus bilateral neck exploration for primary hyperparathyroidism," *Surg. Oncol. Clin.*, vol. 25, no. 1, pp. 103–118, 2016.
- [12] A. K. Lundstroem, W. Trolle, C. H. Soerensen, and P. S. Myschetzky, "Preoperative localization of hyperfunctioning parathyroid glands with 4D-CT," *Eur. Arch. Otorhinolaryngol.*, vol. 273, pp. 1253–1259, 2016.
- [13] P. G.-T. San Miguel, F. G.-C. López, J. V. Curto, M. T. Alonso, and M. M. Gómez, "Update of the role of Nuclear Medicine techniques in the pre-surgical localization of primary hyperparathyroidism," *Rev. Esp. Med. Nucl. E Imagen Mol. Engl. Ed.*, vol. 38, no. 2, pp. 123–135, 2019.
- [14] R. N. Moghadam et al., "Comparative diagnostic performance of ultrasonography and 99mTc-sestamibi scintigraphy for parathyroid adenoma in primary hyperparathyroidism; systematic review and meta-analysis," *Asian Pac. J. Cancer Prev. APJCP*, vol. 18, no. 12, p. 3195, 2017.
- [15] I. Christakis, S. Khan, G. P. Sadler, F. V. Gleeson, K. M. Bradley, and R. Mihai, "18Fluorocholine PET/CT scanning with arterial phase-enhanced CT is useful for persistent/recurrent primary hyperparathyroidism: first UK case series results," *Ann. R. Coll. Surg. Engl.*, vol. 101, no. 7, pp. 501–507, 2019.



- [16] L. A. Boccalatte et al., "Usefulness of 18F-fluorocholine positron emission tomography-computed tomography in locating lesions in hyperparathyroidism: a systematic review," *JAMA Otolaryngol. Neck Surg.*, vol. 145, no. 8, pp. 743–750, 2019.
- [17] J. L. Becker et al., "4D-dynamic contrast-enhanced MRI for preoperative localization in patients with primary hyperparathyroidism," *Am. J. Neuroradiol.*, vol. 41, no. 3, pp. 522–528, 2020.
- [18] G. Treglia et al., "Diagnostic performance of choline PET for detection of hyperfunctioning parathyroid glands in hyperparathyroidism: a systematic review and meta-analysis," *Eur. J. Nucl. Med. Mol. Imaging*, vol. 46, pp. 751–765, 2019.
- [19] C. Guerin et al., "Preoperative imaging for focused parathyroidectomy: making a good strategy even better," *Eur. J. Endocrinol.*, vol. 172, no. 5, pp. 519–526, 2015.
- [20] A. M. Berner et al., "Localization of parathyroid disease with 'sequential multiphase and dual-tracer' technique and comparison with neck ultrasound," *Nucl. Med. Commun.*, vol. 36, no. 1, pp. 45–52, 2015.
- [21] H. Z. Butt, M. A. Husainy, A. Bolia, and N. J. M. London, "Ultrasonography alone can reliably locate parathyroid tumours and facilitates minimally invasive parathyroidectomy," *Ann. R. Coll. Surg. Engl.*, vol. 97, no. 6, pp. 420–424, 2015.
- [22] D. Tay, J. P. Das, and R. Yeh, "Preoperative localization for primary hyperparathyroidism: a clinical review," *Biomedicines*, vol. 9, no. 4, p. 390, 2021.
- [23] C. C. Solorzano, D. M. Carneiro-Pla, and G. L. Irvin III, "Surgeon-performed ultrasonography as the initial and only localizing study in sporadic primary hyperparathyroidism," *J. Am. Coll. Surg.*, vol. 202, no. 1, pp. 18–24, 2006.
- [24] S. Stern, S. Tzelnick, A. Mizrachi, M. Cohen, T. Shpitzer, and G. Bachar, "Accuracy of neck ultrasonography in predicting the size and location of parathyroid adenomas," *Otolaryngol. Neck Surg.*, vol. 159, no. 6, pp. 968–972, 2018.
- [25] L. Michel, M. Dupont, A. Rosière, V. Merlan, M. Lacrosse, and J. E. Donckier, "The rationale for performing MR imaging before surgery for primary hyperparathyroidism," *Acta Chir. Belg.*, vol. 113, no. 2, pp. 112–122, 2013.
- [26] K. Nael et al., "Dynamic 4D MRI for characterization of parathyroid adenomas: multiparametric analysis," *Am. J. Neuroradiol.*, vol. 36, no. 11, pp. 2147–2152, 2015.
- [27] K. K. Wong, L. M. Fig, M. D. Gross, and B. A. Dwamena, "Parathyroid adenoma localization with 99mTc-sestamibi SPECT/CT: a meta-analysis," *Nucl. Med. Commun.*, vol. 36, no. 4, pp. 363–375, 2015.
- [28] N. Aygün, A. İşgör, and M. Uludağ, "The effectiveness of preoperative ultrasonography and scintigraphy in the pathological gland localization in primary hyperparathyroidism patients," *Şişli Etfal Hastan. Tıp Bül.*, vol. 53, no. 4, p. 379, 2019.
- [29] F. Tunca, M. Akici, Y. Işcan, C. Sormaz, and T. Terzioğlu, "The impact of combined interpretation of localization studies on image-guided surgical approaches for primary hyperparathyroidism.," *Minerva Endocrinol.*, vol. 42, no. 3, pp. 213–222, 2016.
- [30] W. P. Kluijfhout, W. M. Vorselaars, M. R. Vriens, I. H. B. Rinkes, G. D. Valk, and B. de Keizer, "Enabling minimal invasive parathyroidectomy for patients with primary hyperparathyroidism using Tc-99m-sestamibi SPECT-CT, ultrasound and first results of 18F-fluorocholine PET-CT," *Eur. J. Radiol.*, vol. 84, no. 9, pp. 1745–1751, 2015.