

# Canine sexual dimorphism in crown and root dimensions: A cone-beam computed tomographic study

Copyright © 2024 International Organization  
for Forensic Odonto-Stomatology - IOFOS

Mohammad Tajik<sup>1</sup>, Najmeh  
Movahhedian<sup>1</sup>

<sup>1</sup> Department of Oral and  
Maxillofacial Radiology, School of  
Dentistry, Shiraz University of Medical  
Sciences, Shiraz, Iran.

**Corresponding author:**  
**movahhedian@sums.ac.ir**

The authors declare that they  
have no conflict of interest.

## KEYWORDS

Sexual Dimorphism,  
Forensic Dentistry,  
Canine tooth,  
Tooth length,  
Cone-beam Computed  
Tomography

J Forensic Odontostomatol  
2024. Apr;(42): 1-2:XX  
ISSN :2219-6749

## ABSTRACT

The primary step in forensic odontological analysis is sex determination. The present study is one of the few studies that evaluated the accuracy of the combination of canine tooth root length and crown measurements for sex determination. The study sample comprised 196 cone-beam computed tomographic scans of individuals aged 20-80 years distributed in five age categories: 20-29, 30-39, 40-49, 50-59, and 60+ years old. Different parameters, such as width, length, and ratio measurements for the crown and root of each maxillary and mandibular canine tooth, were examined and recorded. The findings indicated that maxillary canines had greater sex dimorphism ability (87.3%) than mandibular canines (80.6%). Total tooth length and root length of maxillary canine were the most pronounced variables in the differentiation of sex groups. When the combination of the mandibular and maxillary measurements was considered, the accuracy for sex dimorphism was 85.7%. By using ratio variables, the accuracy was reduced to 68.9%. According to the findings of this study, total tooth length and root length are the most discriminant variables of canine teeth. These variables are more reliable sex indicators than crown measurements.

## INTRODUCTION

Forensic odontology is a subspecialty of forensic medicine that assists in establishing a post-mortem biologic profile, [1] which primarily includes verifying age, sex, stature, and ancestry. [2-4] The primary step in this context is sex determination. Although sex can be most accurately assessed by DNA analysis [5] or examination of skeletal remains such as the pelvis, [6] craniofacial bones, [7] and mandible, [8] their applicability is restricted due to a variety of factors, including the need for expensive equipment and time-consuming procedures or suboptimal condition of the bones, especially those severely mutilated. [9] In such situations, teeth are considered a practical adjacent in sex determination because of their structural durability to pre- and post-mortem insults [10, 11] and their ability to predict sex with an accuracy of 51.13% to 100%. [12-15] Moreover, since the complete development of dentition precedes skeletal maturation, teeth play an essential role in sex determination for younger individuals. [1] The application of dentition in sex determination is primarily based on the distinctions between the dimensions or

morphology of the teeth in males and females. [3, 16, 17] Among different types of teeth, the canine tooth has been consistently used for forensic purposes and is regarded as a "key tooth" in sex determination [1, 18] primarily because they show the most significant sex dimorphism in their dimensions. Moreover, they are the least frequently extracted teeth, [3] highly resistant to dental/periodontal diseases, and are more likely to survive post-mortem trauma.

Many studies on the effectiveness of canine teeth in sex determination used the canine index, which considers the mesiodistal width of the canine teeth and inter-canine arch width. [1-3, 15] However, some studies showed that the canine index has poor sex dimorphism ability, and its application in forensic works should be confined, and absolute measurements of the canine tooth are better sex indicators. [1, 3, 18] Another limitation of such studies is that they have not considered root measurements. This factor may impair the accuracy of sex determination since it has been demonstrated that the Y chromosome has a more decisive influence over root length growth than the X chromosome. [12]

Radiographic examinations are a non-destructive and ethical approach for evaluating the whole tooth if radiographs are taken due to clinical indications. Capitanian et al. [19] used panoramic radiographs to compare the length and width variables and ratios to determine the applicability of various maxillary and mandibular teeth in sexual determination. They showed that the tooth length of the mandibular canine was the most sexually dimorphic measurement. However, panoramic radiographs have disadvantages, such as unequal magnification and unpredictable distortion due to the patient positioning and location within the focal trough. [20] These factors preclude accurate measurements, and the results cannot accurately reproduce or represent direct measurements. In recent years, computed tomography (CT) or cone-beam CT (CBCT) has been increasingly used in forensic investigations, particularly for sex and age determination. [21] CT and CBCT provide images with a sub-millimeter resolution free from distortion, magnification, and superimposition of the adjacent structures, [22] which are not available in projection imaging and panoramic radiography and can positively affect the findings of the studies. [21] The portability, lower cost, ease of image acquisition, and user-friendliness of CBCT over CT make it

more practical for forensic applications, particularly in skeletal imaging and odontology. [20] Therefore, the present study aimed to assess the accuracy of sex determination in adult individuals using CBCT images based on the different length, width, and ratio measurements of the crown and root of canine teeth in mesiodistal and buccolingual dimensions in both jaws. Additionally, it attempted to present a specific formula for sex determination based on the canine teeth using the discriminant function analysis. The present study is the first to be conducted among the Iranian population. It is one of the few studies evaluating the accuracy of canine sex dimorphism considering the tooth root length and crown measurements.

## MATERIALS AND METHODS

In this cross-sectional study, the CBCT scans of 196 individuals (96 men and 100 females) referred to the Dental School of Shiraz University of Medical Sciences (Shiraz, Iran) for purposes other than the present study were evaluated. The study complied with all relevant principles of the Declaration of Helsinki at the time of imaging. All subjects signed a written informed consent form authorizing the use of their anonymous radiographic data in research and publications. The Ethics Committee of Shiraz University of Medical Sciences, Shiraz, Iran, approved the study (IR.Sums.Dental.REC. 1399.206). The study sample age ranged from 20 to 80 years and was divided into five age groups: 20-29, 30-39, 40-49, 50-59, and 60+ years old. Except for the final group, which comprised 16 males due to a lack of individuals matching the inclusion criteria, all groups included 40 CBCT scans distributed evenly between the two sexes. The CBCT images were digitally captured using a New Tom VGi Evo CBCT unit (QR SRL Company, Verona, Italy) with 3 mA, 110 kVp, and 0.3 mm voxel size, in accordance with the manufacturer's instructions for positioning and exposure.

The inclusion criteria of the study were CBCT scans with good image quality, the presence of fully developed and erupted maxillary and mandibular permanent canine teeth, the absence of restorations, significant occlusal wear on the crown of the canine teeth, root resorption, dilacerations, significant buccolingual inclination in the canines, any

pathology or skeletal disorders, and history of trauma or orthodontic treatment.

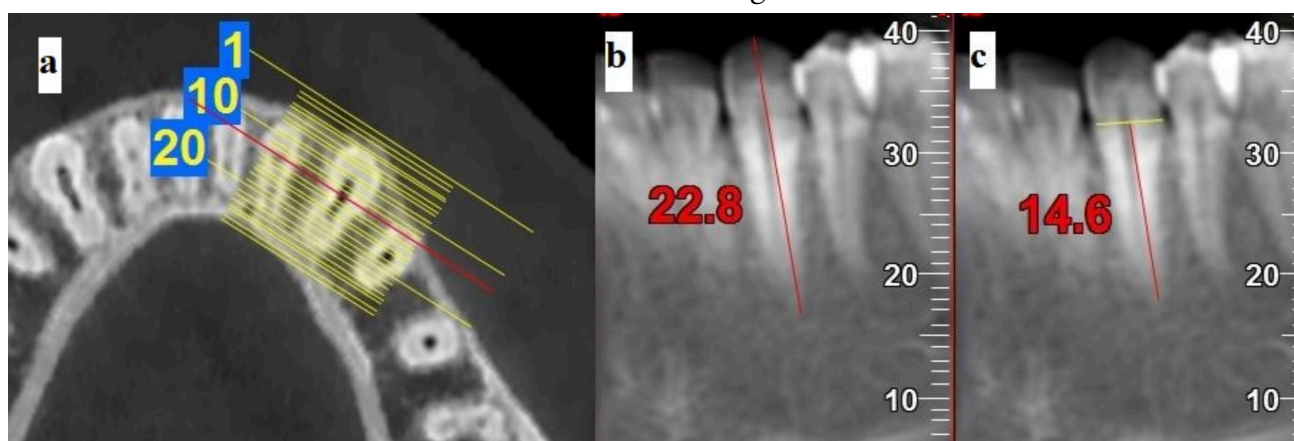
For each scan, the measurements were taken on the canine teeth of both jaws, i.e., maxilla and mandible. Since previous studies showed no significant difference in canine measurements between the left and right sides of the jaw, [3, 23, 24] all the measurements were made on the left canine teeth. Yet, if the left canine tooth did not meet the inclusion criteria, the procedure was made on its right counterpart. Each canine tooth underwent the following measurements:

- *The length measurements:* The maximum tooth length (TL) (defined as the distance between

the most incisal tooth point and the root apex) and the maximum root length (RL) (defined as the distance between the cemento-enamel junction (CEJ) and root apex) (Figure 1).

- *The width measurements:* The maximum buccolingual width of the crown (BL), the buccolingual width of the tooth at the CEJ level (CEJBL), the maximum mesiodistal width of the crown (MD), the mesiodistal width of the tooth at the CEJ level (CEJMD) (Figure 2).
- *The ratio and proportions:* TL/RL, TL/MD, TL/BL, TL/CEJMD, TL/CEJBL, RL/MD, RL/BL, RL/CEJMD, RL/CEJBL, MD/CEJMD, BL/CEJBL, CEJBL/CEJMD, BL/MD

**Figure 1.** Shows the tooth and root length measurements (TL & RL, respectively) used in the study: **a** Axial images used for reconstruction of mesiodistal cross-section; **b** the maximum tooth length; **c** the maximum root length



Based on the axial section at the mid-root level, cross-sections perpendicular to the canine tooth were prepared for the measurements. The length measurements (TL and RL) were done on the mesiodistal cross-sections. The thickness of these cross-sections was considered around 7 mm to account for the buccolingual inclination of the canine tooth and to include both the incisal edge and the apex of the tooth in one section. MD and CEJMD measurements were done on 1 mm thick mesiodistal cross-sections representing the maximum crown width. Buccolingual cross-sections with 1 mm thickness were prepared to measure BL and CEJBL variables. For each subject, additional information such as the subjects' birth dates, date of acquisition of the CBCT scans, and sex were also recorded.

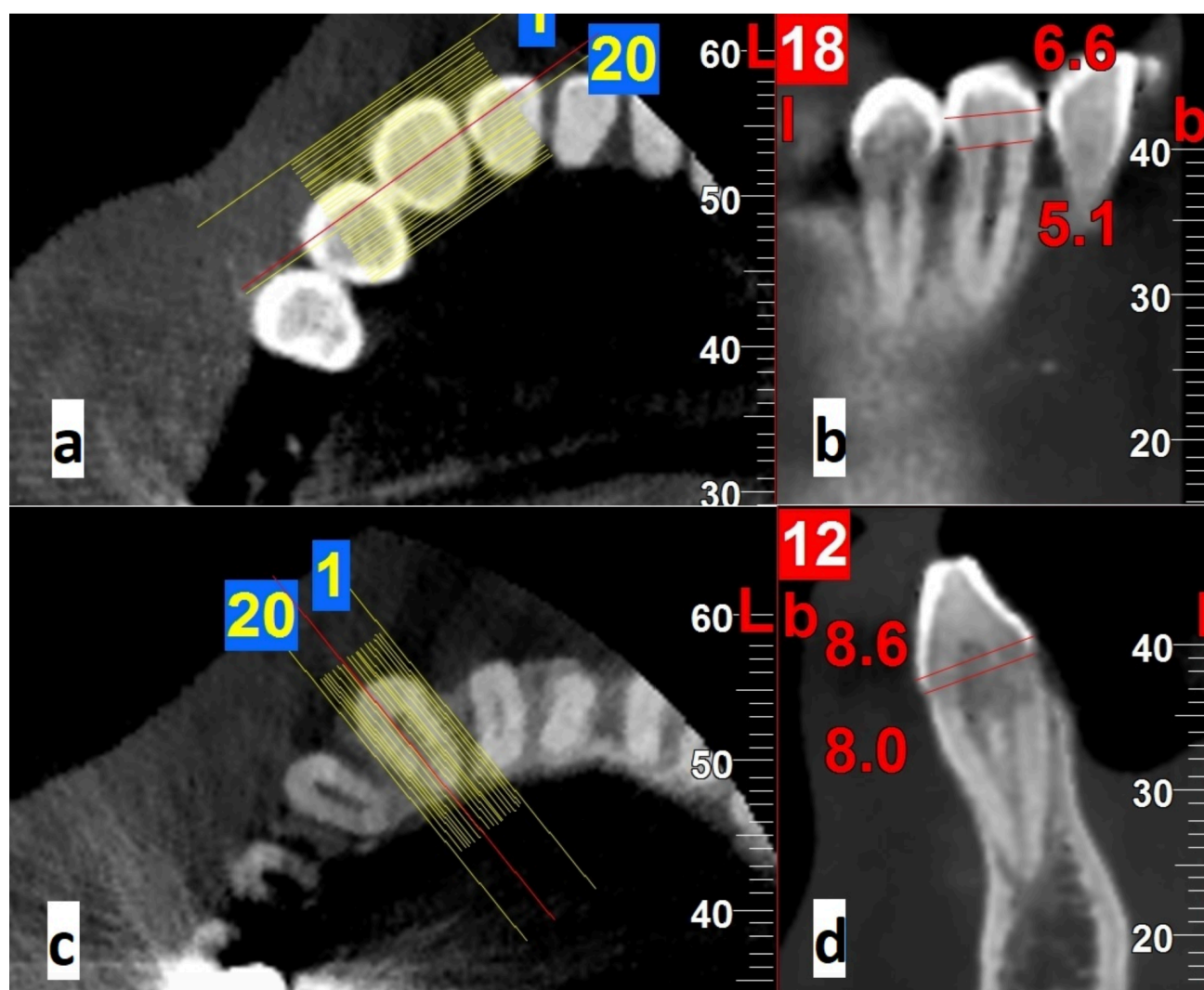
Two examiners, an experienced oral and maxillofacial radiologist and a well-trained post-graduate oral and maxillofacial radiology student,

recorded all the measurements separately using NNT Viewer software (NNT V2.21, Image works, Verona, Italy). The examiners were blinded to the subject's age and sex. To assess the intra- and inter-observer reliability, the examiners randomly selected one-third of the images and re-evaluated them after a two-week interval.

#### Statistical analysis

Data were analyzed using SPSS software, version 22.0 (IBM Corp., Armonk, N.Y., USA). For each variable, the two sexes were compared using an independent t-test. P values less than 0.05 were considered statistically significant. To find the best variables for sex determination, the discriminant analysis and stepwise selection method were used. The accuracy of inter- and the inter-examiner agreement was determined by Intra-class correlation coefficient test (ICC).

**Figure 2.** Shows the width measurements used in the study: a Axial image used for reconstructing mesiodistal cross-sections; b The maximum mesiodistal width of the crown (MD) and the mesiodistal width at the CEJ level (CEJMD); c Axial image used for reconstructing buccolingual cross-sections; d The maximum buccolingual width of the crown (BL) and the buccolingual width of the tooth at the CEJ level (CEJBL)



## RESULTS

Based on the ICC values, there was a high inter and intra-observer agreement for all odontometric measurements ( $r > 0.90$  and  $> 0.95$ , respectively). For analyzing the data, an average for each value was used.

According to the independent t-test results, all the maxillary and mandibular canine teeth length and width measurements significantly differed between the sexes (all P values  $< 0.05$ ). There were also significant differences between males and females in eight ratios of the upper jaw and two of the lower jaw (Table 1).

The results of the stepwise discriminant analysis are shown in Table 2. When all measurements from both jaws were considered, the most pronounced variables in sex group differentiation

were the TL and RL of maxillary canines. Other variables based on the magnitude of Standardized Discriminant Function Coefficients (SDFC) scores were CEJMD of maxillary canine, RL, MD, and CEJMD of mandibular canines, respectively.

The discriminant function for all maxillary and mandibular measurements was formulated using the Canonical Discriminant Function Coefficient (CDFC) as follows:

*Formula 1 (for both jaws):*  $D = [-20.254 + 0.571 (\text{MD of mandibular canine}) + 0.463 (\text{TL of maxillary canine}) - 0.270 (\text{RL of maxillary canine}) + 0.168 (\text{RL of mandibular canine}) + 0.976 (\text{CEJMD of maxillary canine}) + 0.434 (\text{CEJMD of mandibular canine})]$ .

Based on this formula, the discriminant D-score was 0.023 (values greater than 0.023 indicate males, while lower values indicate females).

Based on the corresponding CDFCs, the following formulae were presented for obtaining the discriminant function separately for each jaw measurements:

*Formula 2 (for the maxilla):*  $D = -18.568 + 0.502 (TL) - 0.247 (RL) + 1.286 (CEJMD) + 0.529 (CEJBL)$

The discriminant D-score was 0.022 (values greater than 0.022 indicate males, while lower values indicate females).

*Formula 3 (for the mandible):*  $D = -18.829 + 0.962 (MD) + 0.261 (RL) + 0.952 (CEJMD) + 0.542 (CEJBL)$

The discriminant D-score was 0.019 (values greater than 0.019 indicate males, while lower values indicate females).

Based on the stepwise analysis, the best differentiating variables for each jaw were TL for the maxilla and CEJMD for the mandible.

As presented in Table 2, the maxillary canine had an accuracy rate of 87.3% (87.5% for males and 87.0% for females), and the mandibular canine had an accuracy rate of 80.6% (79.2% for males and 82.0% for females). When both jaws were considered, the accuracy rate was 85.7% (86.0% for males and 85.4% for females).

Based on the magnitude of SDFC scores, the best ratio variables for sex discrimination were MD/CEJMD and TL/MD of the maxillary canine. Based on the corresponding CDFCs, the discriminant function for ratio variables was formulated as follows:

*Formula 4:*  $D = -6.330 - 1.171(TL/MD \text{ of maxillary canine}) + 7.995(MD/CEJMD \text{ of maxillary canine})$

With the discriminant D-score of 0.017 (values greater than 0.017 indicate males, while lower values indicate females). The overall accuracy of these ratio variables was 68.9%, which was the lowest among all the reported accuracies in the present study (Table3).

**Table 1.** Comparisons of all the variables of the permanent canine teeth between the two sexes)

		Variables	Mean±SD		P value
			Male	Female	
<b>Width and length measurements</b>	<b>Maxilla</b>	MD	7.12±0.47	6.63±0.51	<0.001*
		BL	8.27±0.56	7.57±0.56	<0.001*
		TL	26.30±1.82	23.43±1.86	<0.001*
		RL	19.16±1.84	17.01±1.67	<0.001*
		CEJMD	5.58±0.49	4.89±0.44	<0.001*
		CEJBL	7.53±0.51	6.90±0.52	<0.001*
	<b>Mandible</b>	MD	6.38±0.43	5.83±0.44	<0.001*
		BL	7.75±0.51	7.14±0.54	<0.001*
		TL	24.70±1.81	22.47±1.79	<0.001*
		RL	17.43±1.75	15.85±1.67	<0.001*
		CEJMD	5.47±0.53	4.84±0.56	<0.001*
		CEJBL	7.10±0.51	6.52±0.54	<0.001*

<b>Ratios and proportions</b>	<b>Maxilla</b>	TL/RL	1.37±0.07	1.38±0.06	0.601
		BL/MD	1.16±0.08	1.14±0.08	0.150
		RL/BL	2.32±0.23	2.26±0.24	0.038*
		RL/MD	2.70±0.28	2.58±0.28	0.002*
		TL/BL	3.19±0.25	3.10±0.28	0.026*
		TL/MD	3.70±0.31	3.55±0.35	0.001*
		TL/CEJBL	3.50±0.28	3.41±0.30	0.026*
		BL/CEJBL	1.09±0.03	1.09±0.03	0.349
		RL/CEJBL	2.56±0.26	2.48±0.27	0.040*
		MD/CEJMD	1.28±0.09	1.36±0.12	<0.001*
		CEJBL/ CEJMD	1.36±1.35	1.42±0.15	0.003*
		TL/CEJMD	4.74±0.47	4.82±0.53	0.0727
		RL/CEJMD	3.45±0.38	3.49±0.41	0.0572
	<b>Mandible</b>	TL/RL	1.42±0.10	1.42±0.10	0.940
		BL/MD	1.21±0.09	1.22±0.08	0.384
		RL/BL	2.25±0.26	2.22±0.27	0.440
		RL/MD	2.74±0.34	2.73±0.33	0.788
		TL/BL	3.19±0.26	3.15±0.29	0.331
		TL/MD	3.70±0.31	3.54±0.34	0.839
		TL/CEJBL	3.50±0.28	3.40±0.30	0.577
		BL/CEJBL	1.09±0.03	1.09±0.04	0.903
		RL/CEJBL	2.46±0.29	2.44±0.30	0.042
		MD/CEJMD	1.18±0.12	1.21±0.13	0.041*
		CEJBL/ CEJMD	1.30±0.14	1.36±0.15	0.024*
		TL/CEJMD	4.54±0.49	4.67±0.55	0.0751
		RL/CEJMD	3.21±0.41	3.29±0.46	0.0660

The results of the independent T-test are shown in the table

\* P value less than 0.05 was considered statistically significant

*MD*: the maximum mesiodistal width of the crown; *BL*: the maximum buccolingual width of the crown; *TL*: the maximum tooth length; *RL*: the maximum root length; *CEJMD*: the mesiodistal width of the tooth at the CEJ level; *CEJBL*: the buccolingual width of the tooth at the CEJ level

**Table 2.** The length and width measurements of canine teeth with significant differentiating function based on discriminant analysis

Jaw	Variable	C.D.F.C *	S.D.F.C**	Overall Accuracy (%)
Both Jaws	TL <sup>2</sup>	0.463	0.857	85.7
	RL <sup>2</sup>	-0.270	-0.475	
	CEJMD <sup>2</sup>	0.976	0.458	
	RL <sup>1</sup>	0.168	0.288	
	MD <sup>1</sup>	0.571	0.253	
	CEJMD <sup>1</sup>	0.434	0.217	
Maxillary canine	TL	0.502	0.928	87.3
	CEJMD	1.286	0.603	
	RL	-0.247	-0.435	
	CEJBL	0.529	0.277	
Mandibular canine	CEJMD	0.952	0.477	80.6
	MD	0.962	0.428	
	RL	0.261	0.448	
	CEJBL	0.542	0.286	

\* Canonical Discriminant Function Coefficient

\*\* Standardized Discriminant Function Coefficient

**TL**: the maximum tooth length; **RL**: the maximum root length; **CEJBL**: the buccolingual width of the tooth at the CEJ level; **MD**: the maximum mesiodistal width of the crown; **CEJMD**: the mesiodistal width of the tooth at the CEJ level

1 and 2 indicate mandibular and maxillary measurements, respectively.

**Table 3.** The ratio variables of canine teeth with significant differentiating function based on discriminant analysis

Jaw	Variables	C.D.F.C *	S.D.F.C**	Overall accuracy (%)
Maxillary canine	MD/CEJMD	7.995	0.841	68.9
	TL/MD	-1.171	-0.386	

\* Canonical Discriminant Function Coefficient

\*\* Standardized Discriminant Function Coefficient

**TL**: the maximum tooth length; **MD**: the maximum mesiodistal width of the crown; **CEJMD**: the mesiodistal width of the tooth at the CEJ level

## DISCUSSION

Exact sex estimation is the foremost step in the identification process. Teeth and skeleton-based methods have a prominent application in sex determination as they are usually the best-preserved remains. [9] Among different types of

teeth, the canine tooth has consistently been considered the most sexually dimorphic and critical tooth across various populations. [12, 18, 25, 26] Most studies on the applicability and accuracy of the canine teeth in sex dimorphism are based



on the crown measurements and canine index, and root measures have rarely been utilized for sex dimorphism analysis. This is mainly due to the inaccessibility of the tooth root.<sup>[27]</sup> The root, preserved in the bony socket, is considered a more resilient structure than the tooth crown and, unlike the crown, is not affected by wear.<sup>[28]</sup> According to Lähdesmäki and Alvesalo,<sup>[29]</sup> the Y chromosome may play a more significant role in root length development than the X chromosome, which may be responsible for the sexual dimorphic characteristics of the root. Zorba et al.<sup>[28]</sup> showed that root length measurements of single-rooted teeth were a reliable indicator of sex dimorphism. Moreover, other studies reported that the root length of permanent teeth had a higher degree of sexual dimorphism than the crown measurements.<sup>[9, 30]</sup> According to Garn et al.,<sup>[9]</sup> root length alone shows comparable or greater sexual dimorphism as the crown measurements. They also showed that combining root and crown measurements enhances the sexual discriminant power of each set of measurements on its own. However, few studies<sup>[9, 13, 19, 28, 31]</sup> considered canine tooth root measurements for sex determination.

Moreover, since different populations exhibited distinct patterns of sexual dimorphism, the findings of such studies were considered population-specific<sup>[13, 32]</sup> and should not be generalized. Only one study has examined tooth root dimensions for sex determination in the archaeological Iranian population.<sup>[13]</sup> This study was a CT volumetric examination of 52 archaeological skeletal remains dating from around 1400 to 800 BCE, which may not reliably represent the present population.

CBCT has been widely used for forensic purposes in recent years.<sup>[21, 33]</sup> Besides sub-millimeter resolution, CBCT offers other advantages over conventional two-dimensional radiographs, including distortion-free images, magnification, superimposition of the adjacent structures, and the capacity to adjust the structure orientation.<sup>[21]</sup> These features enhance the ability to locate the anatomic structures better, which leads to more accurate results. Sherrard et al.<sup>[34]</sup> investigated the reliability of the tooth measurements on CBCT scans. They found that the total tooth and root length measurements were not significantly different from the direct measurements on the extracted teeth. Similarly, Stratemann et al.<sup>[35]</sup> reported that the difference

between CBCT-based measurements using NewTom scanning and direct measurements by caliper was just  $0.07 \pm 0.41$  mm. In addition, Kim et al.<sup>[36]</sup> found no statistically significant differences in the crown and root length in CBCT scans and direct measurements of the premolar teeth using a digital caliper. However, CBCT-based measurements demonstrated that the total tooth length of the premolars was  $0.18 \pm 0.44$  mm shorter than the direct measurements. This study also found a weak positive correlation between the crown and root length in the canine and premolar teeth, indicating that the crown length cannot accurately estimate root length in most tooth types.

To lessen the impact of dental wear, the studies using tooth crown measurements for sex estimation<sup>[12, 19, 37, 38]</sup> had to restrict the age range of their study samples to young adults. According to Lambrechts et al.,<sup>[39]</sup> the annual enamel vertical loss *in vivo* ranged between 20 and 38 micrometers. Consequently, the teeth with significant attrition were excluded from the present investigation. On the other hand, since the present study included tooth root measurements, which were not affected by wear, the age range of the study sample was set at 20-80 years old. This age range was comparable to studies by Zorba et al.<sup>[28]</sup> and Kazzazi and Kranioti,<sup>[13]</sup> which similarly used root length and root volume measurements for sex determination.

The current study's findings indicated that all the length and width measurements of the maxillary and mandibular canine teeth were significantly higher in men than in women. However, only 8 ratio variables of the maxillary canines and 2 ratio variables of the mandibular canines demonstrated a significant difference between the sexes. Similarly, Capitaneanu et al.<sup>[19]</sup> assessed all the maxillary and mandibular teeth in the panoramic image and reported that males had higher mean tooth length and mean width measures. Other studies<sup>[1, 12, 24, 37]</sup> that evaluated the crown or cervical tooth measurements also found that men had higher values than women.

It is estimated that for the dental measurements to be used as the sole sex predictor, the accuracy should be at least 80%.<sup>[19]</sup> In the current study, discriminant analysis results indicated that maxillary canines had a higher sexual dimorphic ability with an accuracy of 87.3%, whereas mandibular canines had an accuracy of 80.6%.



When the measurements of both jaws were considered, the discriminant ability was found to be 85.7%. Dumančić et al., [40] who explored sex dimorphism in canine teeth, reported an accuracy of 73.5% for mandibular canine crown dimension and morphology. Zorba et al. [28] evaluated the root length of single-rooted teeth and discovered that the maxillary lateral incisors and canine were the most dimorphic teeth. Similar to the present study, they reported that maxillary canine had higher sexual discriminant accuracy than mandibular canine. They reported 80% and 76.9% discriminant accuracy for right and left maxillary canine and 74.4% and 77.6% for right and left mandibular canine, which was lower than the present study. While Zorba et al. [28] only measured the root length, the current study considered the length measurements of the tooth and root and the mesio-distal and buccolingual width measurements of the canine tooth crown.

In the present study, the tooth length and root length of maxillary canines showed the most prominent sex dimorphism among all the variables. This finding indicated that root dimension and tooth length measurements are more sex dimorphic than crown measurement and should be considered in forensic investigations. These findings were in agreement with the findings of Capitaneanu et al., [19] who reported that the length measurements of mandibular and maxillary canines had a higher discriminant ability than the width measures. They also reported that mandibular canine tooth length was the most discriminative variable among all teeth. According to the present study's findings, when the ratio variables were considered, the accuracy for sex dimorphism decreased to 68.9%. Similarly, Capitaneanu et al. [19] showed

that combining tooth variables using ratios did not increase the discriminant ability. They introduced ratio variables to reduce the undesirable effect of unequal magnification of panoramic radiography. However, employing ratio variables, which likewise have less accuracy in sex dimorphism, seems unnecessary for this purpose, as using CBCT makes it possible to have real-sized images.

## CONCLUSION

Based on the discriminant analysis results, the maxillary canine tooth was more sexually dimorphic than the mandibular canine tooth (87.3% vs. 80.6%). However, based on the accuracy, both had reliable sex dimorphism abilities. The use of ratio variables reduced the accuracy of sex dimorphism to 68.9%. The TL and RL of maxillary canine were the most discriminant variables of canine teeth. Root and total tooth measurements were more reliable sex indicators than crown measurements. Thus, it is recommended that root and total tooth measurements be considered in forensic investigations for sex determination.

## ACKNOWLEDGMENT

The authors thank the Vice-Chancellery of Shiraz University of Medical Sciences for supporting this research (Grant number: 22084). This manuscript is based on the thesis by Dr. Mohammad Tajik, a post-graduate student of Oral and Maxillofacial Radiology under the supervision of Dr. Najmeh Movahhedian. The authors also thank Dr. Mehrdad Vossoughi of the Center for Research Improvement of the School of Dentistry for the statistical analysis.

### Statements and Declarations:

This work was supported by Shiraz University of Medical Sciences (Grant number 22084)

## REFERENCES

1. Acharya AB, Mainali S. Limitations of the mandibular canine index in sex assessment. *J Forensic Leg Med* 2009;16(2):67-9.
2. Azevedo Á, Pereira ML, Gouveia S, Tavares JN, Caldas IM. Sex estimation using the mandibular canine index components. *Forensic Sci Med Pathol* 2019;15(2):191-7.
3. Gupta S, Chandra A, Gupta OP, Verma Y, Srivastava S. Establishment of sexual dimorphism in North Indian population by odontometric study of permanent maxillary canine. *J Forensic Res* 2014;5(2):1000224.
4. Movahedian N, Abedi S, Memarpour M. Comparison of the Demirjian and root resorption methods to estimate dental age in radiographic images. *J Dent Child (Chic)* 2018;85(2):45-50.
5. Röttscher K. *Forensic and legal dentistry*. 4 ed. Switzerland. Springer; 2014.
6. Steyn M, İşcan MY. Metric sex determination from the pelvis in modern Greeks. *Forensic Sci Int* 2008;179(1):86.e1-6.
7. Williams BA, Rogers T. Evaluating the accuracy and precision of cranial morphological traits for sex determination. *J Forensic Sci* 2006;51(4):729-35.
8. Hu KS, Koh KS, Han SH, Shin KJ, Kim HJ. Sex determination using nonmetric characteristics of the mandible in Koreans. *J Forensic Sci* 2006;51(6):1376-82.

9. Garn SM, Cole PE, Van Alstine WL. Sex discriminatory effectiveness using combinations of root lengths and crown diameters. *Am J Phys Anthropol* 1978;50(1):115-8.
10. Pretty IA, Sweet D. A look at forensic dentistry-Part 1: The role of teeth in the determination of human identity. *Br Dent J* 2001;190(7):359-66.
11. Capitaneanu C, Willems G, Thevissen P. A systematic review of odontological sex estimation methods. *J Forensic Odontostomatol* 2017;35(2):1-19.
12. Angadi PV, Hemani S, Prabhu S, Acharya AB. Analyses of odontometric sexual dimorphism and sex assessment accuracy on a large sample. *J Forensic Leg Med* 2013;20(6):673-7.
13. Kazzazi SM, Kranioti EF. A novel method for sex estimation using 3D computed tomography models of tooth roots: A volumetric analysis. *Arch Oral Biol* 2017;83:202-208.
14. Martins Filho IE, Lopez-Capp TT, Biazevic MG, Michel-Crosato E. Sexual dimorphism using odontometric indexes: Analysis of three statistical techniques. *J Forensic Leg Med* 2016;44:37-42.
15. Nadendla LK, Paramkusam G, Pokala A, Devulapalli RV. Identification of gender using radiomorphometric measurements of canine by discriminant function analysis. *Indian J Dent Res* 2016;27(1):27-31.
16. Davoudmanesh Z, Shariati M, Azizi N, Yekaninejad S, Hozhabr H, Kadkhodaei-Oliadarani F. Sexual dimorphism in permanent canine teeth and formulas for sex determination. *Biomed Res India* 2017;28:2773-7.
17. Macaluso PJ Jr. Sex discrimination potential of permanent maxillary molar cusp diameters. *J Forensic Odontostomatol* 2010;28(1):22: 31-22: 31.
18. Acharya AB, Mainali S. Univariate sex dimorphism in the Nepalese dentition and the use of discriminant functions in gender assessment. *Forensic Sci Int* 2007;173(1):47-56.
19. Capitaneanu C, Willems G, Jacobs R, Fieuws S, Thevissen P. Sex estimation based on tooth measurements using panoramic radiographs. *Int J Legal Med* 2017;131(3):813-21.
20. Mallya SM, Lam E. White and Pharoah's Oral Radiology: Principles and Interpretation. 8th ed. St. Louis: Elsevier Health Sciences; 2018.
21. Sarment DP, Christensen AM. The use of cone beam computed tomography in forensic radiology. *J Forensic Radiol Imaging* 2014;2(4):173-81.
22. Paknahad M, Dokohaki S, Khojastepour L, Shahidi S, Haghnegahdar A. A Radio-Odontometric analysis of sexual dimorphism in first molars using cone-beam computed tomography. *Am J Forensic Med Pathol* 2022;43(1):46-51.
23. Castillo L, Castro AM, Lerma C, Lozada D, Moreno F. Mesiodistal and bucolingual dental diameters in a group of mixed ethnicity population in Cali, Colombia. *Rev Estomat* 2012;20(1):16-22.
24. Kazzazi SM, Kranioti EF. Sex estimation using cervical dental measurements in an archaeological population from Iran. *Archaeol Anthropol Sci* 2018;10:439-48.
25. Prabhu S, Acharya AB. Odontometric sex assessment in Indians. *Forensic Sci Int* 2009;192(1-3):129.e 1-5.
26. da Silva PR, Lopes MC, Martins-Filho IE, Haye Biazevic MG, Michel-Crosato E. Tooth crown mesiodistal measurements for the determination of sexual dimorphism across a range of populations: A systematic review and meta-analysis. *J Forensic odontostomatol* 2019;37(1):2-19.
27. Bakkannavar SM, Manjunath S, Nayak VC, Kumar GP. Canine index-A tool for sex determination. *Egypt J Forensic Sci* 2015;5(4):157-61.
28. Zorba E, Vanna V, Moraitis K. Sexual dimorphism of root length on a Greek population sample. *Homo* 2014;65(2):143-54.
29. Lähdesmäki R, Alvesalo L. Root lengths in 47, XYY males' permanent teeth. *J Dent Res* 2004;83:771-75.
30. Harris EF, Couch Jr WM. The relative sexual dimorphism of human incisor crown and root dimensions. *Dent Anthropol* 2006;19(3):87-95.
31. Govindaram D, Bharanidharan R, Ramya R, Rameshkumar A, Priyadharsini N, Rajkumar K. Root Length: As a determinant tool of sexual dimorphism in an ethnic Tamil population. *J Forensic Dent Sci* 2018;10(2):96-100.
32. Vossoughi M, Movahhedian N, Ghafoori A. The impact of age mimicry bias on the accuracy of methods for age estimation based on Kvaal's pulp/tooth ratios: a bootstrap study. *Int J Legal Med* 2022;136(1):269-78.
33. Baglivo M, Winklhofer S, Hatch GM, Ampanozi G, Thali MJ, Ruder TD. The rise of forensic and post-mortem radiology—analysis of the literature between the year 2000 and 2011. *J Forensic Radiol Imaging* 2013;1(1):3-9.
34. Sherrard JF, Rossouw PE, Benson BW, Carrillo R, Buschang PH. Accuracy and reliability of tooth and root lengths measured on cone-beam computed tomographs. *Am J Orthod Dentofacial Orthop* 2010;137(4 Suppl):S100-08.
35. Stratemann SA, Huang JC, Maki K, Miller AJ, Hatcher DC. Comparison of cone beam computed tomography imaging with physical measures. *Dentomaxillofac Radiol* 2008;37(2):80-93.
36. Kim SY, Lim SH, Gang SN, Kim HJ. Crown and root lengths of incisors, canines, and premolars measured by cone-beam computed tomography in patients with malocclusions. *Korean J Orthod* 2013;43(6):271-8.
37. Acharya AB, Angadi PV, Prabhu S, Nagnur S. Validity of the mandibular canine index (MCI) in sex prediction: Reassessment in an Indian sample. *Forensic Sci Int* 2011;204(1-3):207.e1-4.
38. Khangura RK, Sircar K, Singh S, Rastogi V. Sex determination using mesiodistal dimension of permanent maxillary incisors and canines. *J Forensic Dent Sci* 2011;3(2):81-5.
39. Lambrechts P, Braem M, Vuylsteke-Wauters M, Vanherle G. Quantitative in vivo wear of human enamel. *J Dent Res* 1989;68(12):1752-4.
40. Dumančić J, Scott GR, Savić Pavičin I, Anić-Milošević S, Medančić N, Brkić H. Canine Crown Sexual Dimorphism in a Sample of the Modern Croatian Population. *Dent J (Basel)* 2023;11(7):175.