

RESEARCH STUDIES

DOI: 10.5281/zenodo.1105101

UDC: 616.65-002:615.276

Anti-inflammatory activity of Adenoprosin in nonbacterial prostatitis

Dumbraveanu Ion¹, MD, PhD, Associate Professor; Ciuhrii Ceslav², BioD, PhD
Tanase Adrian¹, MD, PhD, Professor

¹Department of Urology and Surgical Nephrology, Nicolae Testemitsanu State University of Medicine and Pharmacy
Chisinau, the Republic of Moldova; ²Biotehnos SA, Bucharest, Romania

*Corresponding author: ion.dumbraveanu@usmf.md. Received October 20, 2017; accepted December 07, 2017

Abstract

Background: The treatment of chronic nonbacterial prostatitis remains an unexplained urology problem. Adenoprosin is a new entomological product containing lipoprotein extract of Lepidopteran insect species. Laboratory studies of the product have shown that it possesses antioxidant, antiproliferative and anti-inflammatory properties.

Material and methods: Nonbacterial prostatitis was experimentally modeled on 100 white Wistar rats. Adenoprosin, 150 mg rectal suppositories, was tested against the reference product Vitaprost, 50 mg rectal suppositories and placebo on both the aseptic acute and chronic non-bacterial prostatitis models. In the acute prostatitis model, treatment lasted 7 days and in chronic prostatitis 15 days. The treatment efficacy criteria consisted of assessment of the general condition and histological results.

Results: In rats receiving Adenoprosin, the microscopic image of the prostate showed a decrease in the severity of the inflammatory process, in both acute aseptic and chronic nonbacterial prostatitis, manifested by the recovery on the surface of the epithelial cells in the stromal area of the prostate, and decrease in vascular congestion and number of acini with desquamated epithelium.

Conclusions: The product of entomological origin Adenoprosin, showed an obvious anti-inflammatory effect in the experimental model of aseptic acute or chronic non-bacterial prostatitis induced on Wistar white rats, similar to the Vitaprost reference product, and significant compared to placebo ($p < 0.05$).

Key words: Adenoprosin, prostatitis model, non-bacterial prostatitis treatment.

Introduction

Prostate diseases have been and continue to remain a major and controversial issue in urology. Prostatitis is the acute or chronic inflammation of the prostate gland and is characterized by the presence of pain in the groin, pelvic area or genitals, frequent urination, dysuria (difficulty urinating or burning sensation when urinating), and in acute inflammation flu-like symptoms. The persistence of prostate symptomatology has a negative impact on patient's sexual life and quality of life [1, 2, 3, 4].

The controversy begins with prevalence studies and ends with treatment methods. The prevalence of chronic prostatitis in the general population fluctuates from 10 to 38%, and that assessed by using validated NIH-CPSI questionnaires proposed by USA National Institute of Public Health, from 10 to 14% [5, 6, 7].

Though thousands of articles have been published, some clinicians tend to underestimate the illness and its consequences, and others to overdiagnose, especially attributing sexual complaints. Other controversies also arise in terminology; the term prostatitis involves the presence of an inflammatory disease, whereas bacterial infection itself is present in prostatitis patients in only 10% of cases. Approximately 40-60% of patients will have leukocytes and no bacteria, and the remaining 30-40% will have chronic aseptic prostatitis, prostatodynia, or chronic painful pelvic syndrome.

Without a clear classification of chronic prostatitis, treatment methods remain controversial and often uncertain. The role of antibacterial therapy is well defined for acute or chronic bacterial prostatitis, and uncertain for aseptic prostatitis and chronic pelvic pain syndrome [8, 9, 10].

For a deeper study of the causes of nonbacterial prostatitis, and their testing various treatment methods have been proposed among them several experimental models of prostatitis, that mimic human chronic prostatitis phenotype. The closest model is the one induced on white rats. Aseptic prostatitis can be induced by several methods, such as direct injection into the rat prostate of several substances such as ethanol, nitrobenzenesulfonic acid (DNBS), rectal administration of turpentine oil, or surgical modeling by zonal suppression of blood circulation. The interval of 12-48 hours is sufficient to cause an acute inflammation, and the 30-45 days period is sufficient for developing aseptic inflammation similar to that produced by non-bacterial prostatitis [11, 12, 13, 14, 15].

Adenoprosin is a product of entomological origin, obtained by using advanced biotechnologies, which contains lipoprotein extract from Lepidopteran insect species. The product was developed and registered in 2001 within the scientific center "New Tone Laboratories" Romania. After the preclinical studies at the "Nicolae Testemitsanu" State University of Medicine and Pharmacy in the Republic of

Moldova and then in Biotechnos Bioanalysis Laboratory, Romania, it was demonstrated that Adenoprosin possesses antioxidant, antiproliferative, anti-inflammatory and immunomodulating properties.

The purpose of this study is to investigate the anti-inflammatory and adverse effects of Adenoprosin, 150 mg rectal suppositories, in experimentally-modeled aseptic prostatitis on white Wistar rats.

Material and methods

The study included 120 white Wistar male rats with an initial weight of 200 ± 2.1 grams. The acclimation period of rats to baseline was 14 days. Animals were randomized into 6 groups of 10 samples each. Each specimen was marked for identification with a specific colorant (eosin or methylene blue) according to laboratory standards. Animal maintenance and care were held according to the standards described in the "Guide for care and use of Laboratory Animals (2011, National Academy Press)" and the ISO P-53434-2009 standards of Russian Federation [16, 17].

Adenoprosin, 150 mg rectal suppositories, was administered rectally as smaller, dose-proportional parts. The dose of the product Adenoprosin was calculated as the corresponding dose recommended for human use. Thus 150mg/70kg/24 hours is equivalent to 2.1mg/kg body weight. The respective dose was adjusted for rats using the equivalence coefficient of 39/6.5, corresponding to 12.6 mg/kg [18].

The study was performed by comparing with a reference product- Vitaprost, 50 mg rectal suppositories, used for a long time for the treatment of inflammatory diseases of the prostate. The dose of the comparison product, Vitaprost, was 4.2 mg/kg.

The modelling of acute aseptic inflammation of prostate was performed in 50 rats by intra-operative ligation of the anterior lobe artery of the prostate with silk ligature. 10 rats were not subjected to surgery and were cataloged in the control group No. 1 – intact.

Four groups of 10 rats each, received Adenoprosin medication for 7 days, in two different doses, or the Vitaprost comparison medication in two doses. The second dose of both products was about 3 times higher the recommended dose, i.e. 37.8 mg/kg for Adenoprosin and 12.6 mg/kg for Vitaprost.

The second control group consisted of 10 rats with acute aseptic prostatitis following placebo treatment (tab. 1).

The efficacy criteria of the treatment consisted of the: assessment of the general condition and the histological results performed 7 days after prostate ligation. Morphologically, animal necropsy was performed by determining the macroscopic appearance of the prostate, determining prostate weight, calculating mass coefficients, and performing microscopic examinations of the area of caused aseptic inflammation. Anti-inflammatory action was determined by studying the quantitative indices of acute inflammation: the surface of the epithelial cells in the stromal part of the prostate, the

surface and level of blood vascularization, the number of acini with desquamated epithelium placed on 100 consecutive marginal sections [18].

Table 1

The distribution of white Wistar rats (no. 60) with acute aseptic prostatitis under study according to study groups treatment

Group No	Administered treatment	No of rats
1	Healthy rats/intact rats	10
2	Aseptic Prostatitis. Placebo	10
3	Adenoprosin – recommended dose (12,6 mg/kg)	10
4	Adenoprosin – recommended x 3 (37,8 mg/kg)	10
5	Vitaprost – recommended dose (4,2 mg/kg)	10
6	Vitaprost – recommended dose x 3 (12,6 mg/kg)	10

The modelling of chronic aseptic prostatitis was achieved by intra-operative ligation of the right lobe of prostate gland under general anesthesia. The studied product was administered 30 days after the surgery for a period of 15 days. The distribution of the rat groups according to the administered treatment is shown in table 2.

Table 2

The distribution of white Wistar rats (no. 60) with acute aseptic prostatitis according to study groups treatment

Group No.	Administered Treatment	No of rats
1	Healthyrats/intactrats	10
2	AsepticProstatitis. Placebo	10
3	Adenoprosin – recommended dose (12,6 mg/kg)	10
4	Adenoprosin – recommended dose x 3 (37,8 mg/kg)	10
5	Vitaprost – recommended dose (4,2 mg/kg)	10
6	Vitaprost – recommended dose x 3 (12,6 mg/kg)	10

The treatment efficacy criteria were similar to those for the study of acute inflammation, with the exception that morphological examinations were performed after 15 days of treatment, respectively 45 days after ligation of the right prostate lobe. Anti-inflammatory action was determined by studying the quantitative indications of chronic inflammation: the surface of the epithelial cells in the stromal area of the prostate, the surface and level of blood vascularization, the surface of the marginal sections of the prostate and the surface of the collagen cells in the prostate fibrous tissue layers.

The statistical processing of the data was accomplished through the statistical elaboration programs Statistica 5.5. As parametric criteria were used Student criteria and non-parametric criteria were determined according to the Wilkison or Mann-Whitney criteria. The differences were considered true at the veracity level ($p < 0.05$).

Results

The action of the product Adenoprosin, 150 mg rectal suppositories, or Vitaprost, 50 mg rectal suppositories on the model of acute prostatitis

The anti-inflammatory action of the studied products on the model of acute prostatitis was appreciated. The first parameter studied was the general condition of the animals and the determination of the body mass (tab. 3).

Table 3

The dynamic of the body mass index in healthy rats and rats with aseptic acute prostatitis under the action of administered products

Assessed period	Group 1 healthy	Group 2 Placebo	Adenoprosin®		Vitaprost®	
			T Dose	T x 3 Dose	T Dose	T x 3 Dose
Before inflammation	299,00 ±1,54	298,90 ±1,73	299,60 ±2,17	299,20 ±2,41	301,60 ±2,22	302,00 ±2,47
After 7 days	316,60 ±0,78	273,90 ±1,55*	278,60 ±1,20*	279,50 ±1,93*	280,60 ±1,77*	277,50 ±2,25*

*- statistically veridical difference compared to group 1 (healthy, intact rats), $p < 0.05$.

From the table 3, it is clear that the acute aseptic inflammation of the prostate has had a negative impact on the rats' body mass increase in control, placebo group and the groups that were treated with Adenoprosin, rectal suppositories, or Vitaprost, rectal suppositories.

Pathomorphological studies performed 7 days after the onset of acute aseptic prostatitis determined the change in prostate weight coefficients, which are statistically veridical different ($p < 0.05$) (tab. 4). There is, however, evidence of maintenance of the prostate weight coefficient in rats given both Adenoprosin and Vitaprost compared to the placebo group.

It was studied the microscopic appearance of the prostate in healthy rats, those given placebo, and those administered Adenoprosin or Vitaprost.

Thus, in healthy rats the parenchyma of the prostate was represented by the terminal sections of the tubular alveolar glands. Most glands had a broad lumen with a large amount of secretion, which helps the plies of the epithelial mucosa to be smooth and the epithelial cells get a cubic form. Thin

layers of muscle-elastic tissue were located between the secretory units of the gland.

In animals subjected to surgical ligation of the anterior prostate lobe receiving placebo, the histological examination showed the presence of an acute prostatitis: pronounced interstitial edema with evident vascular congestion. The secretory epithelium was atrophied and absent glandular secretion.

In rats receiving Adenoprosin 150 mg rectal suppositories, the microscopic image of the prostate showed a decrease in the severity of the inflammatory process. The parenchyma of the prostate had a normal structure, the terminal sections being covered with a columnar secretory epithelium. At the same time, there were also sectors with stromal edema, but much less pronounced than in the control group without signs of vascular congestion. A similar morphological image of the prostate was observed in the animals treated with Vitaprost, 50 mg rectal suppositories (fig.1).

From a quantitative point of view, the anti-inflammatory action of the studied products was assessed by determining the surface area of epithelial cells on the gland section, the number and the surface of the blood vessels and the number of acini with desquamated epithelium per 100 consecutive marginal sections (tab. 5).

Thus, compared to intact (healthy) rats in placebo-treated animals, a significant numerical reduction of the surface of epithelial cells and blood vessels is observed, with an increased level of epithelial desquamation. In animals treated with Adenoprosin, 150 mg rectal suppositories, or with Vitaprost, 50 mg rectal suppositories, these numbers are much closer to those of the control group.

The action of the product Adenoprosin, 150 mg rectal suppositories, or Vitaprost, 50 mg rectal suppositories on the model of chronic prostatitis

Chronic bacterial prostatitis was modelled by intra-operative ligation of the right prostate lobe. The treatment was initiated 30 days after the ligation and had duration of 15 days. Under assessment was the action of the products on rat body mass and anti-inflammatory action confirmed by morphological changes of the prostate.

Body mass was determined every 7 days from the modelled chronic non-bacterial prostatitis and until the end of treatment. In intact animals a constant increase in body mass throughout the observation period was determined.

Table 4

Modification of the prostate weight index under the influence of the administered products

Assessed period	Group 1 Healthy	Group 2 Placebo	Adenoprosin®		Vitaprost®	
			T Dose	T x 3 Dose	T Dose	T x 3 Dose
7 days of inflammation	2,09±0,03	1,71±0,05*	1,99±0,12#	2,12±0,10#	1,97±0,08#	2,00±0,05#

*- statistically veridical difference compared to group 1 (healthy, intact rats ($p < 0,05$, Mann-Whitney criteria, # - veridical difference compared to control group, placebo ($p < 0,05$).

In animals with chronic prostatitis, a progressive decrease in body mass was observed immediately after the intervention. This decrease continued in rats placebo-treated. In rats receiving the Adenoprosin or Vitaprost products, weight loss stopped immediately after initiation of therapy and after 15 days of treatment weight gain was recorded (tab. 6).

After the evaluation of the animals included in the study, was noticed that the use of Adenoprosin, 150 mg rectal suppositories, and Vitaprost 50 mg rectal suppositories, contributed to the increase in body mass index in rats with non-bacterial chronic prostatitis, compared to placebo-treated

rats. Differences between the actions of the products were not noticed.

The morphological examination started with the determination of prostate weight at 45 days after the modelling of chronic prostatitis (tab. 7).

Histological examination at 45 days after modelled chronic non-bacterial prostatitis in placebo-treated rats showed the presence of interstitial edema, vascular congestion with connective tissue proliferation, high fibroblast content and inflammatory lymphocytic infiltration. The secretory epithelium was atrophied, and secretion at terminal

Table 5

The action of Adenoprosin, 150 mg rectal suppositories, or Vitaprost, 50 mg rectal suppositories, upon the prostate structure through the treatment of acute aseptic prostatitis (group n = 10)

Parametres	Group 1 healthy	Group 2 Placebo	Adenoprosin®		Vitaprost®	
			T Dose	Tx 3 Dose	T Dose	T x 3 Dose
The surface of the epithelial cells	20,8±1,2	8,3±0,9*	12,4±1,3*	16±1,2#	13±1,3*	17±0,9#
The surface of the blood vessels	0,3±0,04	1,2±0,2*	0,7±0,08	0,5±0,05	0,6±0,2	0,5±0,04
The number of the acini with desquamated epithelium per 100 sections	3,2±0,09	15±1,2*	11,3±0,9*	9,4±0,7*#	11,2±0,8*	8,5±0,6*#

* - veridical difference compared to group 1, healthy, intact rats ($p < 0,05$), Mann-Whitney criteria, # - veridical difference compared to control group, placebo ($p < 0,05$).

Table 6

The action of Adenoprosin, 150 mg rectal suppositories, or Vitaprost, 50 mg rectal suppositories upon the rat's body mass index under the treatment of chronic non-bacterial prostatitis (group n = 10)

Parametres	Group 1 healthy	Group 2 Placebo	Adenoprosin®		Vitaprost®	
			T Dose	T x 3 Dose	T Dose	T x 3 Dose
Incipient	299,50±2,24	300,00 ±2,26	297,90 ± 1,57	300,30 ±1,88	296,80 ±2,00	299,70 ±2,44
7 days after	314,60 ±0,85	280,00 ±1,91*	278,60 ±1,87*	277,40 ±1,77*	282,10 ±1,96*	283,90 ±2,02*
14 days after	323,50±1,11	265,20±1,25*	265,70±0,88*	264,20±1,05*	264,00±1,24*	263,00±0,92*
21 days after	333,40±0,86	243,70±0,93*	244,00±1,04*	244,90±1,00*	244,50±1,09*	244,60±1,09*
30 days after	338,20±0,85	237,70 ±1,05*	239,10 ±1,00*	237,60 ±1,42*	237,20 ±1,00*	234,00 ±0,58*
15 days on treatment or placebo	361,60±1,16#	223,80±0,98*	259,30±1,17*#	260,10±0,99*#	260,60±0,88*#	261,60±0,86*#

* - veridical difference compared to group 1, healthy, intact rats ($p < 0,05$), Mann-Whitney criteria, # - veridical difference compared to control group, placebo ($p < 0,05$).

Table 7

The action of Adenoprosin, 150 mg rectal suppositories, or Vitaprost, 50 mg rectal suppositories upon the rats prostate weight under the treatment of chronic non-bacterial prostatitis (group n = 10)

Assessed period	Group 1 healthy	Group 2 Placebo	Adenoprosin®		Vitaprost®	
			T Dose	T x 3 Dose	T Dose	T x 3 Dose
45 days after modelling/ 15 days after treatment	2,04±0,03	1,78±0,05*	2,02±0,04#	2,00±0,03#	2,02±0,08#	2,05±0,07#

* - veridical difference compared to group 1, healthy, intact rats ($p < 0,05$), Mann-Whitney criteria, # - veridical difference compared to control group, placebo ($p < 0,05$).

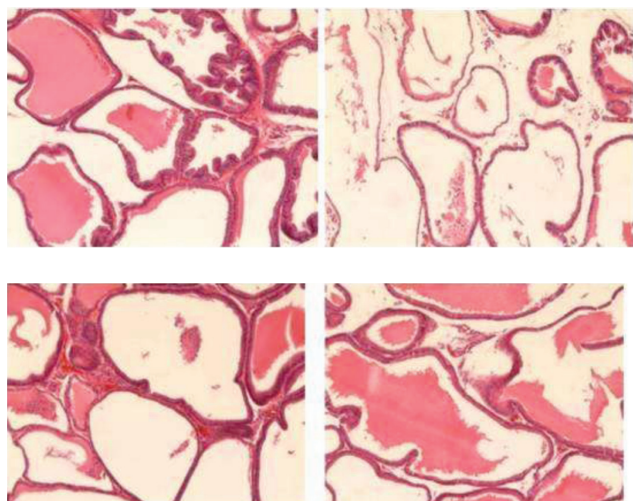


Fig. 1. Microscopic prostate structure: a) intact prostate, b) acute prostatitis treated with placebo, c) acute prostatitis treated with Adenoprosin, rectal suppositories 38 mg/kg, d) Vitaprost treated prostatitis, rectal suppositories 12 mg/kg. Hematoxylin-eosin, x 100.

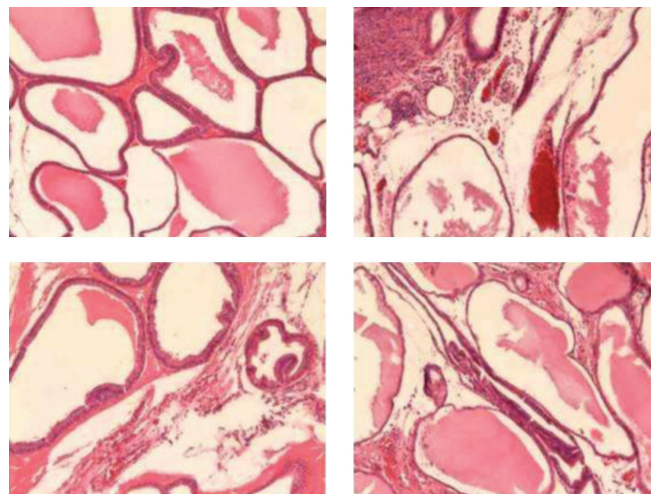


Fig. 2. Microscopic prostate structure: a) intact prostate, b) nonbacterial chronic prostatitis treated with placebo, c) non-bacterial chronic prostatitis treated with Adenoprosin, rectal suppositories 38 mg/kg, d) non-bacterial chronic prostatitis treated with Vitaprost, rectal suppositories 12 mg/kg. Hematoxylin-eosin, x 100.

Table 8

The action of Adenoprosin, 150 mg rectal suppositories, or Vitaprost, 50 mg rectal suppositories, upon the prostate structure through the treatment of chronic nonbacterial prostatitis (group n = 10)

Parametres	Group 1 healthy	Group 2 Placebo	Adenoprosin®		Vitaprost®	
			T Dose	T x 3 Dose	T Dose	T x 3 Dose
The surface of the epithelial cells	20,5±1,4	7,4±0,9*	12,3±1,2*	17,6±1,6#	11,8*±0,9	18,9±1,2#
The surface of the blood vessels	0,3±0,03	1,1±0,2*	0,6±0,2#	0,5±0,1#	0,5±0,09#	0,5±0,04#
The number of the acini with desquamated epithelium per 100 sections	3,3±0,7	50,5±1,4*	35,2±1,6*#	20,4±1,2*#	34,1±1,5*#	25,2±1,6*#
The surface of the collagen fibres	1,5±0,4	15,4±0,5*	13,6±0,7*	10,2±0,9*#	14,3±0,2*	11,1±0,5*#

* - veridical difference compared to group 1, healthy, intact rats (p<0,05), Mann-Whitney criteria, # - veridical difference compared to control group, placebo (p<0,05).

level absent. The presence of segments with epithelial desquamation and obvious dilatation of terminal sections due to exudative fluid accumulation was reported.

In rats treated with Adenoprosin, a reduction in interstitial edema and vascular congestion in the prostate was observed. The macroscopic aspect of the prostatic parenchyma was close to the usual one, secretory columnar cells and active secretion were present in the epithelium of the terminal sections.

Only a few portions have been noted with residual signs of chronic inflammation in the form of stromal lymphocytic infiltrate. The microscopic picture of the prostate of the rats treated with Vitaprost was similar (fig.2).

The anti-inflammatory effect of Adenoprosin product, 150 mg rectal suppositories, was also expressed by increas-

ing the surface of the epithelial cells in the terminal sections, reducing the surface of vascular congestion and the number of acini with desquamated epithelium. There were no signs of an increase in the number of collagen fibers in prostate tissue (tab. 8).

In this way it has been shown that the product Adenoprosin, 150 mg rectal suppositories significantly reduce signs of inflammation in rats with modelled chronic nonbacterial prostatitis.

Discussion

The problem of chronic prostatitis is not fully elucidated. According to national and international clinical protocols the treatment of chronic prostatitis is complex with the use of antimicrobial, antiinflammatory, antioxidant, α-receptor

blockers, phytotherapeutic products, etc. The duration of treatment would be at least 28 days. At the same time, the long-term administration of some pharmacological drugs may cause a number of adverse effects, including: hypotension or retrograde ejaculation due to the use of α -blockers; libido disappearance or erectile dysfunction due to use of 5 α -reductase inhibitors; peptic ulcers, dyspepsia, increased risk of cardiovascular events from using non-steroidal anti-inflammatory drugs, etc [19, 20, 21, 22].

Therefore, researches into the development of new pharmaceutical products for the treatment of chronic prostatitis continues. Evaluation of products on experimental models of prostatitis is one of the most viable solutions to appreciate their action. Most products used to treat chronic bacterial prostatitis were originally tested on animal models.

The product Cernitin, containing pollen extract, used in the treatment of chronic prostatitis has been tested on non-bacterial-induced prostatitis models in rats. Induction of non-bacterial prostatitis was modelled by administration of estradiol after castration. Histopathological evaluation of the prostate during the post-treatment period determined amelioration of the epithelial score, respectively the reduction of the glandular atrophy, along with the inhibition of stromal proliferation [23].

Another herbal product (WSY-1075), tested on non-bacterial prostatitis models induced in Wistar rats, showed that the product significantly reduced the level of prostate proinflammatory cytokines (IL-6 and IL-8) and histological lesions after 8 weeks of administration compared to the control group [24].

A Finnish study has shown that the spruce extract, orally administered for 18 weeks to rats with non-bacterial prostatitis induced experimentally relieves pain and urine evacuation without adverse effects [25].

Several studies recommend the use of products with organotropic action on the prostate for the improvement of local haemodynamic indices [26, 27, 28].

Prostatilen, a product similar to the product included in our study, Vitaprost, contains regulating peptides extracted from the bovine prostate, was tested in rat models weighing 180-200g, to which prostatitis was induced by injection of 10% dimexide solution. The experiment demonstrated the organotropic anti-inflammatory effect of the product [29].

The use of bovine prostate peptides (cytomedins) has been known for many years. They are recommended for their local anti-inflammatory effect and immunomodulatory properties. In several clinical trials, their effect on the evolution of chronic prostatitis and benign prostatic hyperplasia was noted [30, 31].

Adenoprosin is a product that contains lipoproteins that have organotropic action on the prostate. These lipoproteins are obtained from *Lymantria dispar* larvae by a major new method. Biologically active components of the product contribute to the reduction of A2 phospholipase formation and arachidonic acid elimination, followed by a decrease in prostaglandin and leukotriene production [32].

The study assessed the effect of Adenoprosin on the experimental model of non-bacterial acute and chronic prostatitis administered as rectal suppositories. After the morphological examination of the aseptic acute prostatitis model, a decrease in the severity of the inflammatory process, manifested by decreased stromal edema and vascular congestion, was observed. After the quantitative evaluation of Adenoprosin action compared to the control group treated with placebo and the reference product Vitaprost, in animals without organotropic treatment it was observed a significantly reduced surface of epithelial cells, reduced number of blood vessels, and increased level of epithelial desquamation. In rats with aseptic acute prostatitis treated with Adenoprosin or Vitaprost, these indices were much closer to the control group and healthy rats.

On the experimental model of non-bacterial chronic prostatitis, both the tested and the reference products acted by reducing interstitial edema and vascular congestion. The histological appearance of the prostate is suggestive. In rats with non-bacterial chronic prostatitis without treatment, the secretory epithelium is clearly atrophied, interstitial edema and vascular congestion are reported. Under the action of organotropic products, there is a significant reduction in edema, and residual signs of inflammation are present only in certain sectors.

The results of our study are encouraging and open new perspectives for the treatment of non-bacterial chronic prostatitis.

Conclusions

The product of entomological origin Adenoprosin 150 mg rectal suppositories tested in the experimental study of aseptic acute prostatitis showed an obvious anti-inflammatory effect.

The anti-inflammatory activity of the product Adenoprosin is also manifested in the non-bacterial chronic prostatitis model by restoring morphological status of the secretory epithelium, reducing interstitial edema, vascular congestion and the number of acini with prostate desquamation.

The anti-inflammatory activity of Adenoprosin 150 mg rectal suppository on the experimental model of aseptic or chronic non-bacterial prostatitis induced on Wistar white rats is similar to that of the reference product Vitaprost, 50 mg rectal suppositories and is significant compared to placebo.

References

- McNaughton Collins M, Pontari MA, O'Leary MP, et al. Quality of life is impaired in men with chronic prostatitis: the Chronic Prostatitis Collaborative Research Network. *J Gen Intern Med.* 2001;16(10):656-62.
- Walz J, Perrotte P, Hutterer G, Suardi N, et al. Impact of chronic prostatitis-like symptoms on the quality of life in a large group of men. *BJU International.* 2007;100(6):1307-11. doi:10.1111/j.1464-410X.2007.07250.x.
- Chen X, Zhou Z, Qiu X, Wang B, Dai J. The effect of chronic prostatitis/chronic pelvic pain syndrome (CP/CPPS) on erectile function: a

- systematic review and meta-analysis. *PLoS One*. 2015;10(10):e0141447. doi.org/10.1371/journal.pone.0141447.
4. Trinchieri A, Magri V, Cariani L. Prevalence of sexual dysfunction in men with chronic prostatitis/chronic pelvic pain syndrome. *Arch Ital Urol Androl*. 2007;79(2):67-70.
 5. Liang CZ, Li HJ, Wang ZP, et al. The prevalence of prostatitis-like symptoms in China. *J Urol*. 2009;182(2):558-63. doi: 10.1016/j.juro.2009.04.011.
 6. Bartoletti R, Cai T, Mondaini N, et al. Prevalence, incidence estimation, risk factors and characterization of chronic prostatitis/chronic pelvic pain syndrome in outpatients urological hospital in Italy: results of a multicenter case-control observational study. *J Urol*. 2007;178(6):2411-15; discussion 2415; pmid:17937946.
 7. Bajpayee P, Kumar K, Sharma S, et al. Prostatitis: prevalence, health impact and quality improvement strategies. *Acta Pol Pharm*. 2012;69(4):571-9.
 8. Rees J, Abrahams M, Doble A, Cooper A; Prostatitis Expert Reference Group (PERG). Diagnosis and treatment of chronic bacterial prostatitis and chronic prostatitis/chronic pelvic pain syndrome: a consensus guideline. *BJU Int*. 2015;116(4):509-25. doi:10.1111/bju.13101.
 9. Rees J, Doble A. Diagnosis and treatment of chronic prostatitis/chronic pelvic pain syndrome. *Trends Urology & Men Health*. 2016;6:12-7. doi:10.1002/tre.434
 10. Schaeffer AJ. Clinical practice. Chronic prostatitis and chronic pelvic pain syndrome. *N Engl J Med*. 2008;355(16):1690-8.
 11. Keetch DW, Humphrey P, Ratliff L. Development of a mouse model for nonbacterial prostatitis. *J Urol*. 1994;52(1):247-50. doi.org/10.1016/S0022-5347(17)32871-9.
 12. Wang X, Zhong S, Xu T, et al. Histopathological classification criteria of rat model of chronic prostatitis/chronic pelvic pain syndrome. *Int Urol Nephrol*. 2015;47(2):307-16.
 13. Lang MD, Curtis JC, Olson ME, et al. Rat model of experimentally induced bacterial prostatitis. *Prostate*. 2000;45(3):201-6. doi: 10.1002/1097-0045 (20001101) 45:3<201: AID-PROS1>3.0.CO;2-Q.
 14. Kniaz'kin IV, Gorbachev AG, Al'-Shukri SH, et al. Patogeneticheskaya model' prostatita v experimente na melkikh laboratornykh zhyvotnykh [Pathogenetic prostatitis model in experiments with small laboratory animals]. *Nefrologiya*. 2012;16(3):109-13. Russian.
 15. Nizomov SA, Zhukova NA, Sorokina IV. Prostatotropnyy effekt Betamida v modeli abakterial'nogo prostatita u krysa [The prostatotropic effect of Betamid in non-bacterial prostatitis modelled in rats]. *Urologicheskie vedomosti*. 2017;7(Suppl):78-9. Russian.
 16. Kigel' TB, Harabadzhahian AV, Novoderzhkina YuG. Pokazateli biologicheskoi normy dlia laboratornykh zhyvotnykh [Indexes of biological norm for laboratory animals]. Rostov-na-Donu: Rostov Gos Med Institute; 1978. 95 p. Russian.
 17. National Research Council. Guide for care and use of laboratory animals. 8th ed. Washington: National Academies Press; 2011. 246 p. doi: 10.17226/12910.
 18. Mironov AN, et al, editors. Rukovodstvo po provedeniiu doklinicheskikh issledovaniy lekarstvennykh sredstv. Chast' 1. [Guideline in performing preclinical studies for drugs. Part 1]. Moscow: Grif; 2012. 944 p. Russian.
 19. Franco JVA, Tirapegui FI, Turk T, et al. Pharmacological interventions for treating chronic prostatitis/chronic pelvic pain syndrome (Protocol). *Cochrane Database of Systemic Reviews*. 2017;2. art. NoCD012552. doi:10.1002/14651858.CD012552.
 20. Magistro G, Wagelehner FM, Grabe M, et al. Contemporary management of chronic prostatitis/chronic pelvic pain syndrome. *Eur Urol*. 2016;69(2):286-97.
 21. Nickel JC. Prostatitis. *CUA Guidelines*. *Can Urol Assoc J*. 2011;5(5):306-15.
 22. Aliaev YuG, Grigorian VA, Allenov SN, et al. Kompleksnaya medikamentoznaya terapiya khronicheskogo prostatita. [Complex drug approach in treatment of chronic prostatitis]. *Russkii Meditsinskii Zhurnal*. 2005;25(249):1675-8. Russian.
 23. Kamijo T, Sato S, Kitamura T. Effect of cernitin pollen-extract on experimental nonbacterial prostatitis in rats. *Prostate*. 2001;49(2):122-31. doi: 10.1002/pros.1126.
 24. Yoon B, Bae WJ, Kim SJ, et al. The anti-inflammatory effects of a new herbal formula (WSY-1075) in a nonbacterial prostatitis rat model. *World J Men's Health*. 2013;31(2):150-6. doi: 10.5534/wjmh.2013.31.2.150.
 25. Konkol Y, Vuorikovski H, Tuomela J, et al. Norway spruce galactoglucomannan attenuates symptoms of nonbacterial chronic prostatitis/chronic pelvic pain syndrome in rat model. *Eur Urol Suppl*. 2015;14(2):e787.
 26. Dumbaveanu I, Chiukhrui C, Cornea N, Tanase A, et al. Adenoprosin v lechenii zabolovaniy predstatei'noi zhelezy [Adenoprosin in the treatment of prostate diseases]. *Arta Medica*. 2015;57(4):101-4. Russian.
 27. Lopatkin NA, Kamalov AA, Mazo EB, et al. Vitaprost Plus v lechenii khronicheskogo bakterial'inogo prostatita [Vitaprost Plus in treatment of chronic bacterial prostatitis]. *Urologiya*. 2009;3:54-61. Russian.
 28. Tkachuk VN, Tkachuk IN. Effektivnost' vitaprostu u bol'nykh khronicheskimi prostatitom [The efficacy of vitaprost in patients with chronic prostatitis]. *Urologiya*. 2012;4:88-91. Russian.
 29. Savateeva-Liubimova TN, Sivak KV, Malinin VV. [Effect of prostatilen (R) AC suppositories on course of experimental prostatitis]. *Urologiya*. 2012;4:50-54. Russian.
 30. Demidko YuL, Gazimiev MA, Baidualiev AM, et al. [The use of vitaprost in the treatment of patients with prostate diseases]. *Urologiya*. 2014;1:66-70. Russian.
 31. Al'-Shukri SH, Kuz'min IV, Lukina EE. Primenenie kompleksa peptidov predstatei'noi zhelezy Uroprost u bol'nykh s narusheniem ottoka mochi [Uroprost Peptide Complex in treatment of patients with voiding disturbances]. [Experimental and Clinical Urology]. 2010;3:80-4. Russian.
 32. Shalekenov BU, Ghil'iazov AKh, Boguspaev DA, et al. Primenenie Adenoprosina 250 mg, supozitorii v kompleksnom lechenii khronicheskogo prostatita i dobrokachestvennoi giperplazii predstatei'noi zhelezy [The use of Adenoprosin 250 mg rectal suppositories in the complex treatment of chronic prostatitis and benign prostatic hyperplasia]. *Vestnik Khirurgii Kazakhstana*. 2012;1:72-4. Russian.