

Bal Wioletta Anna, Bąk Tomasz Krzysztof, Krasuska Beata, Topyła Weronika Sandra. Osteomyelitis of the mandible in the patient with plasmocytoma – case report. Journal of Education, Health and Sport. 2017;7(12):53-58. eISSN 2391-8306. DOI <http://dx.doi.org/10.5281/zenodo.1098557>
<http://ojs.ukw.edu.pl/index.php/johs/article/view/5100>

The journal has had 7 points in Ministry of Science and Higher Education parametric evaluation. Part B item 1223 (26.01.2017).

1223 Journal of Education, Health and Sport eISSN 2391-8306 7

© The Authors 2017;

This article is published with open access at Licensee Open Journal Systems of Kazimierz Wielki University in Bydgoszcz, Poland

provided the original author(s) and source are credited. This is an open access article licensed under the terms of the Creative Commons Attribution Non Commercial License (http://creativecommons.org/licenses/by-nc/4.0/) which permits unrestricted, non commercial use, distribution and reproduction in any medium, provided the work is properly cited.

This is an open access article licensed under the terms of the Creative Commons Attribution Non Commercial License (http://creativecommons.org/licenses/by-nc/4.0/) which permits unrestricted, non commercial use, distribution and reproduction in any medium, provided the work is properly cited.

The authors declare that there is no conflict of interests regarding the publication of this paper.

Received: 10.11.2017. Revised: 15.11.2017. Accepted: 09.12.2017.

Osteomyelitis of the mandible in the patient with plasmocytoma – case report

Wioletta Anna Bal

<http://orcid.org/0000-0003-4992-5322>

<https://orcid.org/0000-0003-4992-5322>

Student Medical University of Lublin, Poland

Tomasz Krzysztof Bąk

<http://orcid.org/0000-0002-6062-0848>

<https://orcid.org/0000-0002-6062-0848>

**Chair and Clinic of Maxillofacial Surgery, Medical University of Lublin,
Poland**

M.D., D.D.S.

Beata Krasuska

<http://orcid.org/0000-0001-8010-1642>

<https://orcid.org/0000-0001-8010-1642>

Medical University of Lublin, Poland

Student, Medical University of Lublin

Weronika Sandra Topyła

<http://orcid.org/0000-0002-3997-9952>

<https://orcid.org/0000-0002-3997-9952>

Medical University of Lublin, Poland

Student, Medical University of Lublin

Key words: osteomyelitis, plasmocytoma, osteonecrosis

ABSTRACT

Osteomyelitis is an infection of bone which may be caused by infection carried to the bone via the bloodstream or from surrounding tissue. Treatment of osteomyelitis of the mandible is extremely difficult because of oral environment and teeth presence. Management often involves both debridement and antibiotic selection. Despite this, aggressive surgical interventions and conservative therapy are most important aspects of treatment.

Medication-related osteonecrosis of the jaw (MRONJ) is an avascular necrosis related to osteomyelitis and characterized by necrotic bone in the maxillofacial region. The prevalence of this is associated with treatment with high-potency bisphosphonates or denosumab and it seems to be getting increasingly frequent.

Due to lack of prospective studies with long-term follow-up there are no recommendation for treatment of MRNOJ. The main aim of treatment of patients with MRNOJ is to continue and to support oncological treatment as well as to provide patient education, comfort to life, control of pain and to prevent from secondary infection and development of new areas of necrosis.

INTRODUCTION

Osteomyelitis is one of the oldest described diseases. Some records come from the 5th and the 4th century BC, that is, from the time of Hippocrates. In the days before antibiotics, the treatment of osteomyelitis was exclusively surgical and it consisted in total excision of necrotic material. Osteomyelitis can occur as a result of infection carried to the bone via the bloodstream, trauma of the bone, contiguous spread of infection to bone from soft tissues and joints or poor circulation (as seen in diabetes). In case of osteomyelitis, intramedullary pressure increases due to inflammation, which spreads into the bone cortex where it can rupture through the periosteum. The sequestrum is formed. Sometimes, pus which may occur in colaca of involucrum [1].

Hematogenous osteomyelitis is more common in children than adults. The most frequent locations of changes are long bones in children and the vertebrae in adults [2]. In younger patients the contagious osteomyelitis is a complication of trauma or related surgery and in the older ones it is a result of decubitus ulcers or infected implants [3].

Typical symptoms of chronic osteoarthritis include: pain, swelling, redness and sometimes fistula (which is pathognomic of chronic osteomyelitis)[4]. Chronic osteomyelitis should be suspected in patients who have bad healing wounds, peripheral neuropathy, bedsores and who use underlying hardware. Microbial cultures from a bone biopsy and histologic findings of inflammation or osteonecrosis are the basis of diagnosis [5]. The preferred method is open biopsy. During surgical debridement, bone samples should be obtained [6].

Osteomyelitis of the jaw can be caused by odontogenic infections that spread contiguously. The mandible is much more predisposed to osteomyelitis because of thin and poorly vascularised cortex plates. However, mandibular inflammation is relatively rare and occurs in patients with risk factors such as compound fracture, diabetes mellitus, irradiation or steroid therapy [7]. The greatest risk of fistulas is in the region of molar teeth and anteriorly on the buccal aspect of mandible [8].

Medication-related osteonecrosis of the jaw (MRONJ) is an avascular necrosis related to osteomyelitis and characterized by necrotic bone in the maxillofacial region. The

prevalence of this is associated with treatment with high-potency bisphosphonates or denosumab and it seems to be getting increasingly frequent [9].

CASE REPORT

A 78-year old man suffering from plasmocytoma admitted to the Clinic of Maxillofacial Surgery due to inflammation and necrosis of mandible.

The patient suffered from colonic diverticulosis, hypertension and ischemic disease. In the past, he had posterior myocardial infarction. The Patient was taking a substitute dose of dexamethasone because of secondary hypopituitarism. He was allergic to salicylates.

Since 2014 he has been treated for Plasmocytoma in Hemato-oncology Department. The disease exacerbated in December of 2016 and in February of 2017 the first suspicion of Bisphosphonate-Related Osteonecrosis of the Jaw (BRONJ) aroused. Bisphosphonate therapy was discontinued. In March of 2017 the last hospitalization in Maxillofacial Surgery Department due to inflammation of mandible took place.

Physical examination revealed inflammation of cutis in genian area with purulent fistula. The submandibular lymph nodes were enlarged. Poor oral hygiene was observed - oral mucosa altered pathologically. In mandible there was anodontia - the patient had a few teeth (lower incisors) (Fig.1). The heartbeat was irregular (80 per minute).

The laboratory test detected elevated markers of inflammation (C reactive protein 10 mg/l) and anaemia (HGB 9,4 g/dl, RBC 3,27 M/ul, HCT 29,6%, RDW 19,9%). Low total serum protein (4,87 g/dl), high chloride (112,1 mmol/l) and low total calcium level (1,88 mmol/l) were marked, too.

Coagulation tests had abnormal results. Prothrombin time was taken longer (15 sec.) and D-dimer (988 ng/ml) and fibrinogen (3,8 g/l) level was high.

ECG demonstrated the features of the posterior myocardial infarction – characteristics of left anterior hemiblock and Q waves in aVL, V1-V2 leads were presented.

In CT of the facial skeleton with contrast there was hypodense area within the body of mandible on the left side of the tooth 45 (dimension 32x14 mm) (Fig.2) which was causing thinning and loss of cortical bone and hypodense area in mentum (31x8 mm). The CT image was responsible for osteolytic focuses. Lack of teeth: 13, 35, 22, 26, 37, 46, 47. X-ray of the chest without changes.

After anesthesia consultation and cross matching, 2 units of packed red blood cells were transfused.

Surgery was performed in general anaesthesia and tracheal intubation per mouth. Dermal fistula in the genian area was cut and the body of mandible was exposed in the middle. Necrotic and granulation tissues within the cancellous bone were removed. Extraction of teeth 35 – 45 was performed due to root necrosis. The alveolus and wound in genian area were sewed.

Histopathological examination of the removed tissue was ordered. In specimen of cutis, chronic inflammation and resorptive granulation were founded. Non-specific granulation and suppuration with plasma cell infiltration were observed.

During discharging from the hospital, the patient was in a good general condition.

DISCUSSION:

Treatment of osteomyelitis of the mandible is extremely difficult because of oral environment and teeth presence. As a result, the antibiotic therapy must be often prolonged for weeks or months [10]. Debriment, selection of the appropriate antibiotic and duration of therapy are the most important aspects of treatment of osteomyelitis. Surgical treatment is as common as conservative treatment and they both are also used together for debridement of

necrotic tissue and eradication of infection. Bacterial culture and susceptibility findings should be the basis of antibiotic therapy. Broad-spectrum of empiric therapy should be applied if culture result could not be obtained [11].

Due to lack of data, there are no recommendation for management of MRNOJ. There are not any prospective studies with long-term follow-up. Despite this, aggressive surgical interventions and conservative therapy (such as limited debridement, antibiotics, oral rinses with chlorhexidine or hydrogen peroxide) are used frequently. Conservative treatment is effective in 30 to 60% of cases, while some cases develop complications and become chronic [12]. Normal oral microbes are usually cultured from bone biopsy. However, bacterial cultures may help identify comorbid oral infections and choose antibiotic regimen if large part of soft tissue is involved [13]. Necrotic bone and loose bony sequestra should be removed and reconstructed because it is a cause of soft tissue irritation. This management is intended to optimize the tissue healing [14]. It is necessary to consider removing the symptomatic teeth within and it is unlikely that extraction will aggravate the necrotic process. Furthermore, the surgical resection is recommended only in the refractory or advanced cases [15]. The main aim of treatment of patients with MRNOJ is to continue and to support oncological treatment as well as to provide patient education, comfort to life, control of pain and to prevent from secondary infection and development of new areas of necrosis [16].

The negative pressure wound therapy (NPWT) and hyperbaric oxygen (HBO) are the most frequent adjunctive therapies. Indirect effects of NPWT are associated with increased local blood flow, reduction in mediators of inflammation, reduction of edema, reduction of bacterial growth and removal of healing inhibitors [17]. Neutrophil and macrophage activity is increased in ischemic tissue due to HBO. Therefore could be effective therapy in patients with osteomyelitis.

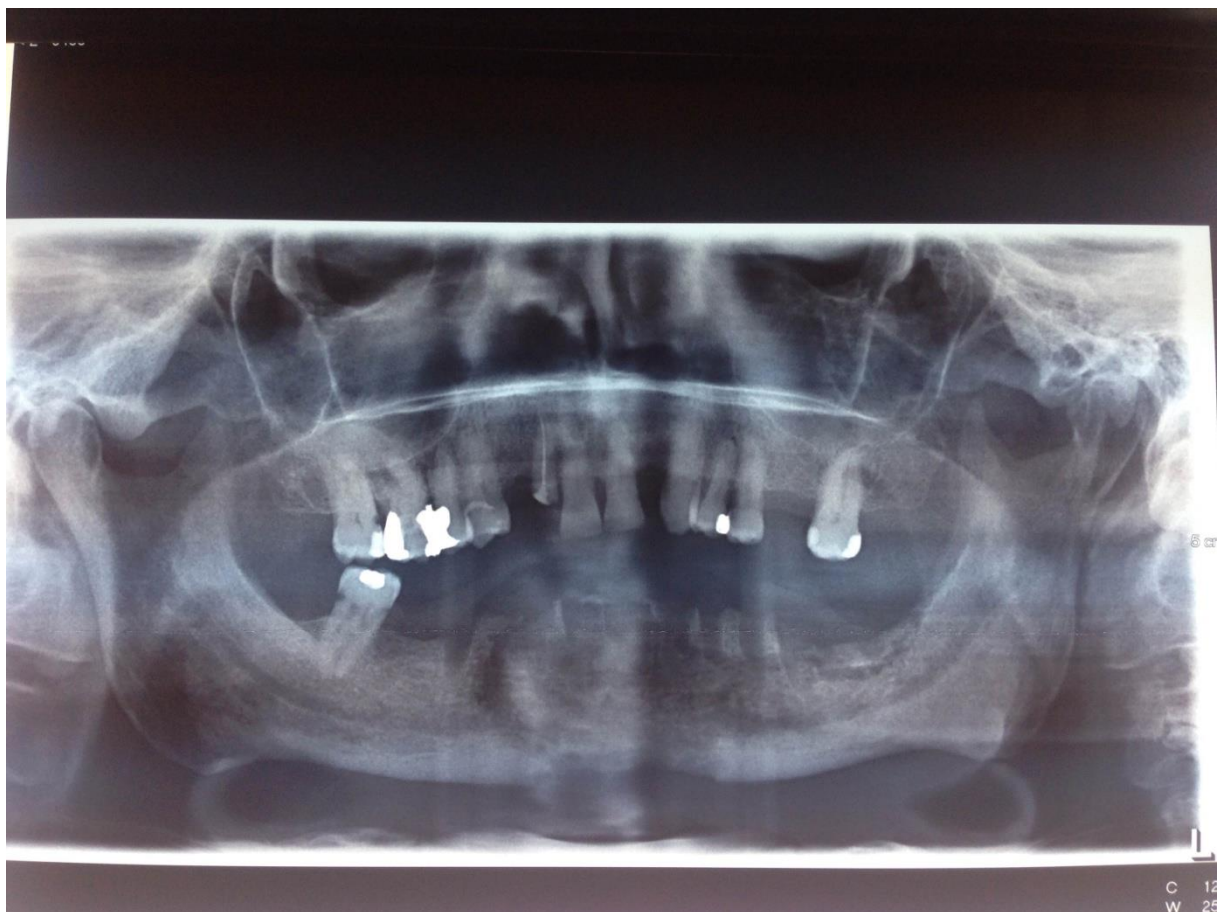


Fig. 1. Adontia in mandible

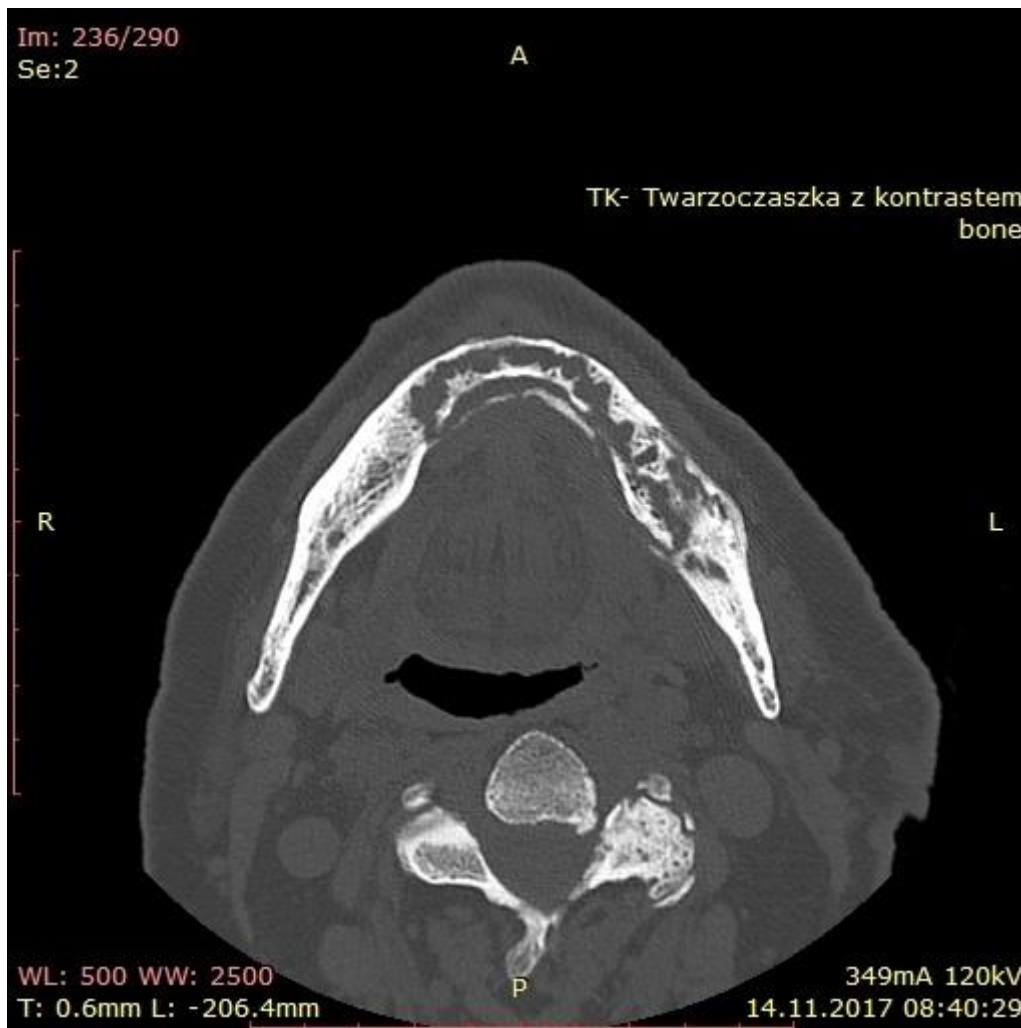


Fig. 2. Hypodense area within the body of mandible on the left side of the tooth 45

REFERENCES

1. Lew DP, Waldvogel FA. Osteomyelitis Lancet. 2004 Jul 24-30;364(9431):369-79.
2. David R, Barron BJ, Madewell JE, Osteomyelitis, acute and chronic., Radiol Clin North Am. 1987;25(6):1171.
3. Waldvogel FA, Medoff G, Swartz MN, Osteomyelitis: a review of clinical features, therapeutic considerations and unusual aspects. N Engl J Med. 1970;282(4):198.
4. Newman LG, Waller J, Palestro CJ, Schwartz M, Klein MJ, Hermann G, Harrington E, Harrington M, Roman SH, Stagnaro-Green A, Unsuspected osteomyelitis in diabetic foot ulcers. Diagnosis and monitoring by leukocyte scanning with indium in 111 oxyquinoline. JAMA. 1991;266(9):1246.
5. Lipsky BA, Berendt AR, Deery HG, Embil JM, Joseph WS, Karchmer AW, LeFrock JL, Lew DP, Mader JT, Norden C, Tan JS, Infectious Diseases Society of America, Diagnosis and treatment of diabetic foot infections. Clin Infect Dis. 2004;39(7):885
6. Darouiche RO, Landon GC, Klima M, Musher DM, Markowski J, Osteomyelitis associated with pressure sores. Arch Intern Med. 1994;154(7):753.
7. Prasad KC, Prasad SC, Mouli N, Agarwal S Osteomyelitis in the head and neck. Acta Otolaryngol. 2007;127(2):194.

8. Mandell GL, Dolin R, Blaser MJ (Eds), Chow AW. Infections of the oral cavity, neck and head. In: Principles and Practices of Infectious Diseases, Elsevier Churchill Livingstone, Philadelphia 2014. p.789
9. Hong SO, Lee CY, Jung J, Kim DY, Walter C, Kwon YD, A retrospective study of osteomyelitis and osteonecrosis of the jaws and its etiologic implication of bisphosphonate in Asians. Clin Oral Investig. 2016
10. Chrcanovic BR, Reher P, Sousa AA, Harris M Osteoradionecrosis of the jaws--a current overview--Part 2: dental management and therapeutic options for treatment. Oral Maxillofac Surg. 2010;14(2):81
11. Lazzarini L, Lipsky BA, Mader JT, Antibiotic treatment of osteomyelitis: what have we learned from 30 years of clinical trials? Int J Infect Dis. 2005;9(3):127.
12. Saad F, Brown JE, Van Poznak C, Ibrahim T, Stemmer SM, Stopeck AT, Diel IJ, Takahashi S, Shore N, Henry DH, Barrios CH, Facon T, Senecal F, Fizazi K, Zhou L, Daniels A, Carrière P, Dansey R, Incidence, risk factors, and outcomes of osteonecrosis of the jaw: integrated analysis from three blinded active-controlled phase III trials in cancer patients with bone metastases. Ann Oncol. 2012;23(5):1341. Epub 2011 Oct 10.
13. Allen MR, Ruggiero SL, A review of pharmaceutical agents and oral bone health: how osteonecrosis of the jaw has affected the field. Int J Oral Maxillofac Implants. 2014 Jan;29(1):e45-57.
14. Kademani D, Koka S, Lacy MQ, Rajkumar SV, Primary surgical therapy for osteonecrosis of the jaw secondary to bisphosphonate therapy. Mayo Clin Proc. 2006;81(8):1100.
15. Badros A, Weikel D, Salama A, Goloubeva O, Schneider A, Rapoport A, Fenton R, Gahres N, Sausville E, Ord R, Meiller T Osteonecrosis of the jaw in multiple myeloma patients: clinical features and risk factors. J Clin Oncol. 2006;24(6):945.
16. Medication-Related Osteonecrosis of the Jaw - 2014 Update. American Association of Oral and Maxillofacial Surgeons. http://www.aaoms.org/docs/position_papers/mronj_position_paper.pdf?pdf=MRONJ-Position-Paper (Accessed on September 04, 2014).
17. Orgill DP, Manders EK, Sumpio BE et al. The mechanisms of action of vacuum assisted closure: more to learn. Surgery 2009;146(1):40–51
18. Calhoun JH, Cobos JA, Mader JT , Does hyperbaric oxygen have a place in the treatment of osteomyelitis?, Orthop Clin North Am. 1991;22(3):467.