

**A Case Report****An Unusual Case of Peripheral Ossifying Fibroma of the Mandible in an Adult Male**

DR. Kumar Gaurav Dubey, MDS [1]; DR. Saurabh Shekhar, MDS. [2]

1 and 2 Senior Residents,  
Department of Dentistry,  
Anugrah Narayana Magadh Medical College and Hospital, Gaya, Bihar, INDIA

Correspondence: DR Saurabh Shekhar, Senior Resident,  
Department of Dentistry, Anugrah Narayana Magadh Medical College and Hospital,  
Gaya-823001, Bihar-INDIA. saurabhshekhar2001@gmail.com

Keywords: Peripheral ossifying fibroma, fibrous epulis, peripheral cemento ossifying fibroma, calcifying fibroblastic granuloma, gingival growth

**ABSTRACT**

Peripheral ossifying fibroma is a benign reactive swelling of the gingiva, most commonly affecting young adults. It is said to be derived from cells of the periodontal ligament and is usually termed as a reactive hyperplasia. There has been considerable confusion in the terminologies used to describe this lesion; until it was separated from peripheral odontogenic fibroma in a recent WHO classification. It is sometimes also called as the peripheral cemento-ossifying fibroma but is quite distinct from the central cemento-ossifying tumour of bone.

Peripheral ossifying fibroma is a frequently encountered lesion that represents 1-3% of all oral biopsies in most cases. It is rare in paediatric patients in relation to primary dentition and frequency reduces after the age of 30 years. Its incidence increases in the adolescent years. It is seen commonly in females suggesting a hormonal influence in its development. Trauma or irritation caused by dental prosthesis or restorations, plaque or calculus, is said to play a role.

Peripheral ossifying fibroma occurs predominantly on the gingiva, specifically developing in the interdental papilla. It

is seen commonly in the maxilla especially in the anterior area; the most common site being the incisor/ cuspid area.

Clinically, it is difficult to differentiate this lesion from other growths on the gingiva, such as the irritation fibroma, peripheral giant cell granuloma, pyogenic granuloma, and the giant cell fibroma. Radiographs rarely show bone involvement. The histology is characteristic, with the presence of either cementum or bone or calcium deposits in a cellular connective tissue stroma. The treatment for peripheral ossifying fibroma is complete excision and elimination of the causative factor. The recurrence rate is high hence the lesion is kept under observation.

The case report of a 40-year-old male patient who had a growth that had a normal overlying surface mucosa and of firm consistency, in the anterior portion of his lower jaw, has been reported here. Histological features were confirmatory for a peripheral ossifying fibroma.

**INTRODUCTION**

Fibro-osseous lesions of the jaws have been categorised by Waldron and Giansanti into three discrete groups:

(a) Fibrous dysplasia,

(b) Fibro-osseous lesions arising from the periodontal ligament that would include central ossifying fibroma and peripheral ossifying fibroma,

(c) Fibro-osseous neoplasms of uncertain or debatable relationships, in which osteoblastoma and cementoblastoma have been categorised. [1]

Cemento ossifying fibroma is one of the third category of non-odontogenic tumours since the 1992 World Health Organization classification. The mineralized tissue seen in ossifying fibromas probably originates from periosteal cells or the periodontal ligament. [2]

History: Menzel, in 1872 first described the ossifying fibroma, and it was only in 1927 that the terminology 'Peripheral Ossifying Fibroma', was assigned, by Montgomery. [1]. Peripheral ossifying fibroma is the term devised by Eversol and Robin [1], [3]. In 1971, the World Health Organization (WHO) categorised the cementum containing lesions into four types that included fibrous dysplasia, ossifying fibroma, cementifying fibroma, and cemento-ossifying fibroma, [1]. However, the term "cementifying ossifying fibroma" was reduced to the term "ossifying fibroma" in the new WHO classification in 2005. [1]

Terminologies used to describe Ossifying fibromas include epulis; ossifying fibroma with calcification; peripheral cemento-ossifying fibroma and calcifying fibroma, [4] calcified fibroid epulis. [2].

POF has also been exchangeable with peripheral odontogenic fibroma, but the peripheral odontogenic fibroma is now deliberated to be an extra-osseous counterpart of the neoplastic central odontogenic fibroma and therefore should not be used in place of POF. The term peripheral ossifying fibroma is now being commonly used. [5]

The lesion is considered to be an inflammatory or reactive process rather than a neoplastic one.

Clinically, there is a greater occurrence of this lesion in younger individuals,

especially between 10 to 19 years of age; and is seen to commonly affect the females (2-4 times). [4] The lesion is well-delineated, having a smooth surface, usually with normal colored mucosa or red or pink in color [3]; either sessile or pedunculated, of hard consistency; with a wide size ranging from 2 centimetres to 6 centimetres. The growth of this lesion is rapid due to the effect of certain growth factors like the basic fibroblast growth factor and vascular endothelial growth factors and by additional factors such as nitric oxide synthetase. It is frequently seen in the anterior maxillary jaw, especially in the interdental area; histopathologically presenting with a stratified squamous epithelium, with or without ulceration, that covers the underlying connective tissue stroma that contains several fibroblasts. The ulcerated epithelial surface is covered by a fibrous-purulent exudate and an adjacent area of granulation tissue.

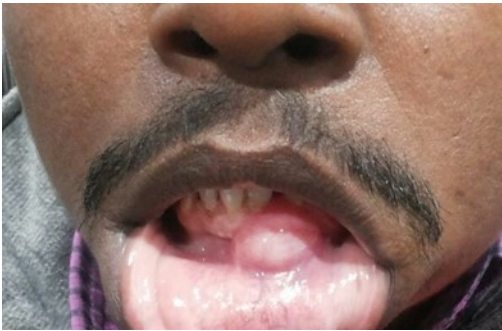
The calcification in this lesion may be varied, accounting for mature lamellar bone, dystrophic calcifications, immature bone, or cementum-like bony tissue [3], trabecular bone, oval and/or spheroid ossicles blended irregular bone trabeculae and curved bone trabeculae. Although the bone is the trabecular type, older lesions might show a mature lamellar one. Histologically, the ossifying fibroma is more cellular and less vascular than the pyogenic granuloma. The studies state that the origin of the peripheral ossifying fibromas may be from the pluripotent cell of the periosteum or periodontal ligament

It can reach a large size rather rapidly, but there is often a delay of months or years before the patient seeks treatment which may be due to the development of ulceration, gross appearance of the lesion or due to discomfort. Though the lesion is benign, there is a high recurrence rate of about 20%, occurring in an average of 12 months following initial excision. Therefore regular follow-up is required. If left unattended the lesion continues to cause the destruction of surrounding bone. [6]

Treatment for the peripheral ossifying fibroma consists of surgical excision along with the periosteum and periodontal ligament in the involved area; as well as the removal of the causative agent. The extraction of teeth is rarely required. This approach is adopted, taking into consideration, its high recurrence rate. [4]

#### CASE REPORT

A patient aged 40 years complained of swelling in the lower anterior region of the jaw. The lesion was around 2x2 centimetres in the dimension. The overlying mucosa appeared normal. (Figure 1)



**FIGURE 1:** Swelling in the Lower anterior region. The Lesion was around 2x2 centimetres in the dimension. The overlying mucosa appeared normal.

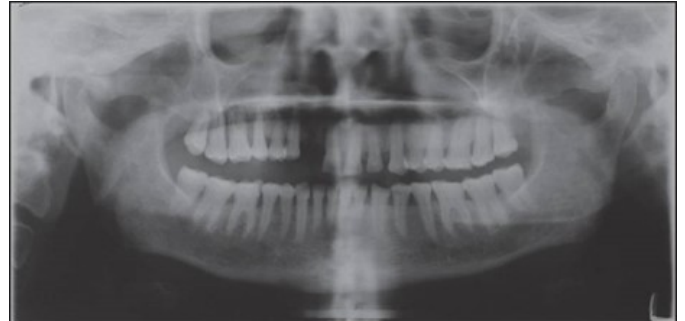On palpation, the lesion was sessile and firm in consistency. Ortho Pantomogram showed no abnormalities. There was a bone loss in association with the lower central incisors. (Figure 2)

The lesion was excised under strict aseptic conditions by giving a crevicular incision with a vertical releasing incision. Histopathological examination of the tissue showed:

*Under Scanner view:* Hematoxylin and Eosin stained section showed stratified squamous epithelium overlying fibro-cellular connective tissue stroma.

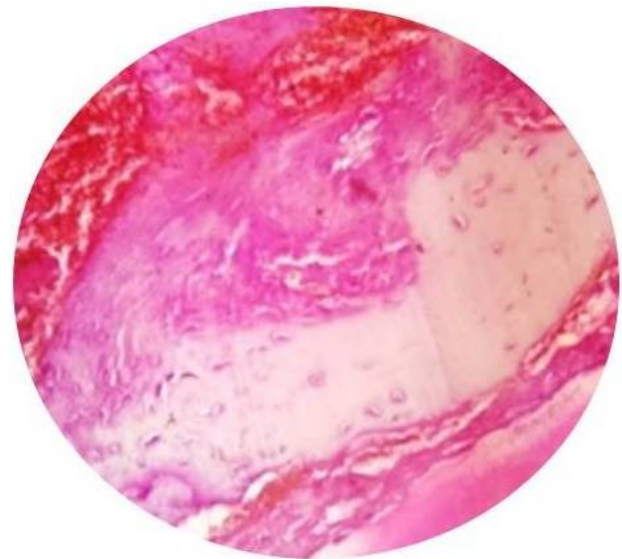
*Under Higher Magnification:* Section showed a stratified squamous epithelium overlying

connective tissue stroma consisting of loose to dense bundles of collagen fibres with predominantly plump shaped fibroblasts. An area of eosinophilic structure suggestive of ossification with osteocytes in the lacunae,



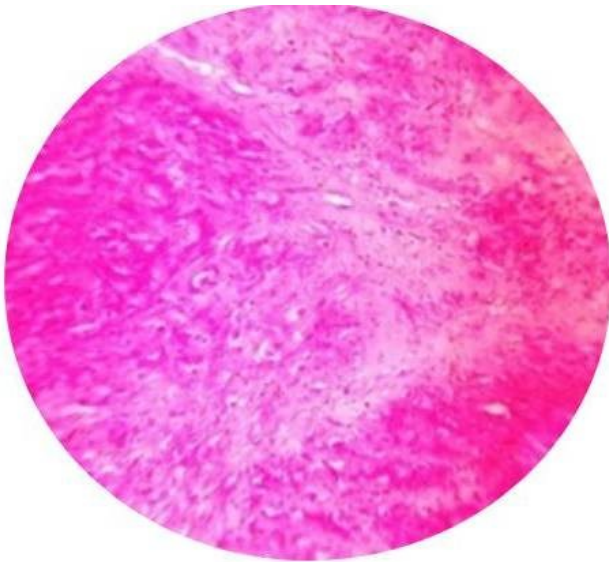
**FIGURE 2:** Orthopantomogram (OPG) showing an absence of bone involvement with the loss of bone around lower incisors.

(Figures 3 and 4) and osteoblastic rimming; which was surrounded by hypercellular connective tissue stroma, was evident. Scanty chronic inflammatory infiltrated cells predominantly made up of lymphocytes and plasma cells were seen. Extravasated and RBC (red blood cells)



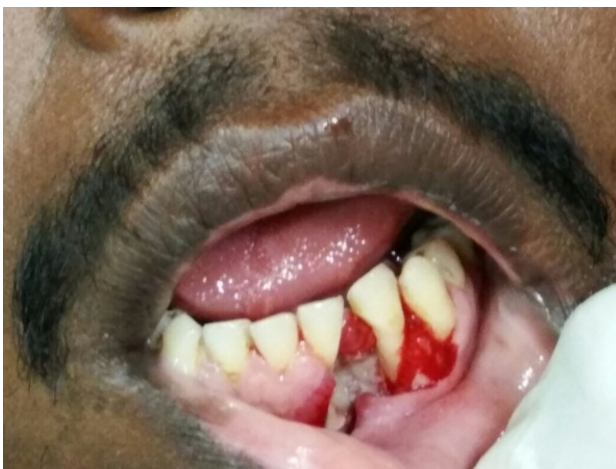filled endothelial lined blood vessels was noticed.

**FIGURE 3:** Hematoxylin and Eosin stained section showing the osteoid formation in the fibro-vascular connective tissue



**FIGURE 4:** Higher magnification showing the osteoblasts forming osteoid.

The Gross Examination of two pieces of tissue, 1.5 centimetres x 1 centimetre and 0.7 millimetres x 0.7 millimetres in size approximately, showed irregular borders, firm in consistency, and greyish in colour.



**FIGURE 5:** Post-operative picture of the patient shows the reflected gingiva and the Lesion.

The clinical and histo-pathological features were suggestive of a Peripheral Ossifying Fibroma

## DISCUSSION

Ossifying fibromas was first described in 1844. Bhasker et al. termed this tumor as a peripheral fibroma with calcification. Arnott later described the microscopic features of the lesion and gave it a diagnosis of ossifying fibroma. [7] In

1982, Gardner coined the term, "peripheral ossifying fibroma" for the same lesion that was reactive in nature, and was not the extraosseous counterpart of a central ossifying fibroma of the maxilla and mandible. [1]

The aetiology and pathogenesis of peripheral ossifying fibromas are unknown, although these lesions have the periodontal ligament for their source of origin:

- The lesion occurred exclusively in the gingival tissue, close to the periodontal ligament;
- Oxytalan fibres were reported to be found within the mineralized matrix of some lesions;
- The fibro-cellular response was similar to that of other reactive gingival lesions originating from the periodontal ligament.
- The age distribution of the lesion was inversely proportional to the number of permanent teeth lost.
- Local irritants such as dental plaque, calculus, poor-quality restorations, microorganisms, masticatory forces, ill-fitting dentures, and trauma have all been implicated in the aetiology; as also the masticatory forces. [3]

While the aetiology of POF is unclear, inflammatory hyperplasia originating in the superficial periodontal ligament is considered to be one of the factors.

Hormonal influence is because of its predilection in females. [1]

The rapid growth of this lesion could be attributed to certain growth factors like basic fibroblast growth factor, vascular endothelial growth factors and additional factors such as nitric oxide synthetase. [2]

**Radiographic features:** Based on the size of the lesion; the rate of mineralisation and presence of calcific masses, radiographic changes were seen in the form of foci of radio-opaque masses and slight bony resorption. Mild cupping defects of adjacent alveolar bone were also seen. Maxilla was involved more than the mandible. The lesion usually measured to a size of <2 centimetres in diameter, but lesions of 6 cm or as large as 9 cm have also been reported. [3]

The histological features of POF include:

- Intact or ulcerated stratified squamous surface epithelium;
- Benign fibrous connective tissue stroma containing varying number of fibroblasts;
- Sparse to profuse endothelial cell proliferation;
- Calcified masses consisting of mature, lamellar or woven osteoid, cementum-like material, or dystrophic calcifications;
- Acute or chronic inflammatory cells were also seen in the lesion.

Buchner and Hansen observed that the mineralized tissues in peripheral ossifying fibromas were of three basic types.

- ❖ The bone that may be woven, lamellar, or trabecular, sometimes surrounded by osteoid.
- ❖ Cementum-like material that appeared as spherical bodies or large acellular round to oval eosinophilic bodies which coalesced to form islands of various sizes and shapes.
- ❖ Dystrophic calcifications that ranged from small clusters of minute basophilic granules or tiny globules to large solid irregular masses.

Immunohistochemical profile studies indicated that the nature of the proliferating cells was

- Myofibroblastic in nature.
- C68 positive histiocytic component intermingling with lymphocytes and plasma cells suggesting the existence of a reactive phenomenon or a response to inflammation.

Multicentre peripheral ossifying fibroma may sometimes be seen in the oral and maxillofacial region, in conditions linked to known genetic mutations such as:

- Nevoid basal cell carcinoma syndrome,
- Multiple endocrine neoplasia Type II,
- Neurofibromatosis, and
- Gardner's syndrome. [1]

Though the common treatment modality is the surgical excision with a blade, new treatment practises have been introduced such as the laser excision (Nd: YAG laser, flash lamp pulsed dye laser) so as to obtain a bloodless surgical field, cryosurgery and electrodesiccation. Mergoni et al. have shown a 30% recurrence rate in cases of peripheral ossifying fibromas. [1]

Alternative modalities may also be practised such as the use of intra-lesional injection of corticosteroid and the sodium tetradecyl sulphate sclerotherapy, as well as ethanol. Lasers are being used for treating peripheral ossifying fibromas due to its advantage in creating a bloodless field during the surgery and also to minimize scarring and wound contraction. [2]

#### Differential Diagnosis:

**Pyogenic Granuloma:** Pyogenic granuloma is soft, nodular and friable lesions that bleed with minimum probing, but there is no tooth displacement and resorption of alveolar bone.

Peripheral giant cell granuloma appears similar to POF, but the surface has a purple, or blue discoloration and calcifications may not be visible in radiographs.

Osteosarcomas and chondrosarcomas are less common on the gingiva as compared to the POF. Malignant lesions show more pronounced bony changes, and there is usually an asymmetric widening of the PDL.

[1] The term cemento ossifying has been referred to as out-dated; and scientifically inaccurate because the clinical presentation and the histopathology of cemento ossifying fibroma are the same in areas where there is no cementum, such as the femur, skull, and the tibia. Also, there is no histologic or biochemical difference between cementum and bone. Cemento-ossifying fibroma is the term given mainly due to the presence of altered round basophilic bone particles within ossifying fibroma, which have arbitrarily been called cementicles.

Investigators have attempted to establish a relationship between PG and POF,

suggesting the pyogenic granuloma and the POF may signify the progressive stages of the same pathology. Long standing PG is thought to undergo organization and healing, which is apparent histologically along with the features of decreased vascularity, decreased inflammation and focal ossification. This long standing nature and maturation may lead to the development of POF. However, it has also been stated that the POF is a distinct clinical unit rather than an intermediate form of PG. [2]

### CONCLUSION

When a gingival growth is found, it is important to give a right diagnosis of the condition, which would help in managing the patient. Histopathological findings play a major role in establishing a diagnosis. The treatment of these focal

reactive overgrowths is the complete elimination of the lesion and etiologic factors. Regular follow up is also very essential to avoid recurrence of the lesion. Due to their clinical and histopathological similarities; it is thought that some peripheral ossifying fibromas develop from a pyogenic granuloma, which has undergone fibrous maturation and then ossification. These lesions are often mistakenly removed by superficial incision. It is important to remove this lesion completely to reduce recurrences; and by also including the adjacent periosteum and periodontal ligament apart from their possible causes.

**Funding:** No funding has been received for the article

**Competing Interests:** The authors have no conflicting interest with regard to the article.

### REFERENCES

1. Choudary SA, Naik AR, Naik MS, Anvitha D. Multicentric variant of peripheral ossifying fibroma. *Indian J Dent Res* 2014; 25: 220-4
2. Raja Sridhar, Sangeeta Wanjari, Kanteshwari I.K. Interrelationship between Pyogenic Granuloma and Peripheral Ossifying. Fibroma: A Case Report *The Journal of Dental Hygiene. Summer 2012; 86(3):179-184*
3. Junior JCM, Keim FS, Kreibich MS. Peripheral Ossifying Fibroma of The Maxilla: Case Report. *Int. Arch. Otorhinolaryngol.* 2008; 12(2):295-299

4. John RR, Kandasamy S, Achuthan N. Unusually Large-sized peripheral ossifying fibroma. *Ann Maxillofac Surg* 2016; 6:300-3
5. Zenaida Elvira S. Cuisia, Robert B. Brannon. Peripheral ossifying fibroma – A Clinical evaluation of 134 Pediatric cases. *American Academy of Pediatric Dentistry. Pediatric Dentistry.* 2001; 23:3
6. Dr Delwyn Dyall-Smith. *DermNET NZ. All about skin*
7. Keluskar V, Byakodi R, Shah N. Peripheral ossifying fibroma. *J Indian Acad Oral Med Radiol.* 2008; 20: 54-6