



# Mutations in *GFAP*, encoding glial fibrillary acidic protein, are associated with Alexander disease

Michael Brenner<sup>1</sup>, Anne B. Johnson<sup>2</sup>, Odile Boespflug-Tanguy<sup>3</sup>, Diana Rodriguez<sup>4</sup>, James E. Goldman<sup>5</sup>  
& Albee Messing<sup>6</sup>

Alexander disease is a rare disorder of the central nervous system of unknown etiology<sup>1,2</sup>. Infants with Alexander disease develop a leukoencephalopathy with macrocephaly, seizures and psychomotor retardation, leading to death usually within the first decade; patients with juvenile or adult forms typically experience ataxia, bulbar signs and spasticity, and a more slowly progressive course. The pathological hallmark of all forms of Alexander disease is the presence of Rosenthal fibers, cytoplasmic inclusions in astrocytes that contain the intermediate filament protein GFAP in association with small heat-shock proteins<sup>3,4</sup>. We previously found that overexpression of human GFAP in astrocytes of transgenic mice is fatal and accompanied by the presence of inclusion bodies indistinguishable from human Rosenthal fibers<sup>5</sup>. These results suggested that a primary alteration in *GFAP* may be responsible for Alexander disease. Sequence analysis of DNA samples from patients representing different Alexander disease phenotypes revealed that most cases are associated with non-conservative mutations in the coding region of *GFAP*. Alexander disease therefore represents the first example of a primary genetic disorder of astrocytes, one of the major cell types in the vertebrate CNS.

We collected genomic DNA samples from 11 unrelated patients in whom the diagnosis of Alexander disease had been confirmed by autopsy (Table 1). Most of these patients displayed the typical onset of clinical signs in early childhood, although one had an onset at 10 years of age with a protracted course extending 38 years. In addition, we analyzed DNA from two patients with leukodystrophies other than Alexander disease for which the genes have not yet been cloned but which map to loci different from *GFAP*: childhood ataxia with central hypomyelination<sup>6</sup> and an autosomal dominant leukodystrophy<sup>7</sup>. Each exon with some adjoining intron segment and 1,717 bp of the 5' flanking region of *GFAP* were amplified by PCR and sequenced. We compared these results with the sequence previously determined from a human genomic clone<sup>8,9</sup>.

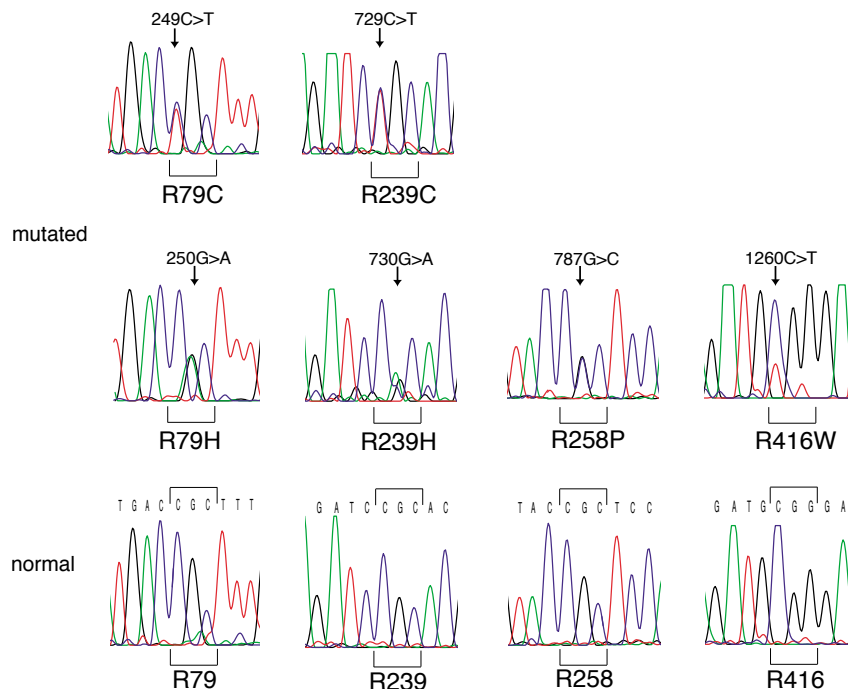
Of the 11 DNAs from Alexander disease patients, 10 contained novel heterozygous mutations of *GFAP* predicting non-conservative amino acid changes, all involving arginines (Table 1 and Fig. 1). None of these mutations was observed in the two non-Alexander disease leukodystrophy control DNAs that were fully sequenced, or in 53 control DNA samples from individuals without neurologic disease that were analyzed specifically for these mutations by restriction digestion.

Table 1 • Characteristics of patients with Alexander disease and associated *GFAP* mutations

Patient	Sex	Age at onset	Age at death	Exon	Nucleotide <sup>a,b</sup>	Predicted amino acid change	Parental DNA
fully sequenced							
1 <sup>c</sup>	m	3 m	14 y	1	249C→T	R79C	normal
2 <sup>c,d</sup>	f	10 y	48 y	1	250G→A	R79H	
3	m	13 m	6 y	4	729C→T	R239C	
4 <sup>e</sup>	f	17 m	11 y	4	729C→T	R239C	
5	f	< 1 y	10 y	4	729C→T	R239C	normal
6	f	< 1 y	4 y	4	729C→T	R239C	normal
7	f	4 m	11 m	4	730G→A	R239H	normal
8 <sup>c</sup>	m	2 m	6 y	4	787G→C	R258P	
9 <sup>c</sup>	m	10 m	7 y	8	1260C→T	R416W	normal
10 <sup>c</sup>	f	3 m	8 y	8	1260C→T	R416W	
11 <sup>f</sup>	f	birth	4 m		normal	none	
checked for mutations shown above <sup>g</sup>							
12 <sup>f</sup>	m	11 m	na <sup>h</sup>	1	249C→T	R79C	normal
13	f	1 y	na <sup>h</sup>	1	250G→A	R79H	normal

<sup>a</sup>Nucleotide numbers refer to the reported cDNA sequence<sup>8</sup>. <sup>b</sup>In addition to the above exonic changes, changes in noncoding regions were observed as follows (underline indicates homozygous for the base change): T→Cat bp -988, patients 1-3, 4, 6, 7-10, 11 and 12 control; T→A at -504, patients 1, 2, 3, 6, 7, 8-10, 11 and 12 control; C→A at -250, patients 1, 2, 3, 6, 7, 8-11 and 12 control; C→T in intron 3, 12 bp from start of exon 4, patient 3; C→G in intron 3, 9 bp from start of exon 4, patient 2; C→G in intron 6, 66 bp from start of exon 7 (bottom strand only sequenced), patients 1, 5, 6, 7, 9 and 11; G→C in 3' UTR, 21 bp from translation stop, patients 5 and 7; C→G in 3' UTR, 33 bp from translation stop, patients 1, 5, 6, 7, 9 and 11. <sup>c</sup>Patients 1, 2, 8, 9 and 10 are heterozygous for the silent 872G→A polymorphism in exon 5 that was previously found in 9% of controls<sup>30</sup>. <sup>d</sup>Patient 2 is heterozygous for the 897G→A polymorphism, predicting a conservative D295N amino acid change that was previously found in 3% of controls<sup>30</sup>. <sup>e</sup>Patient 4 also carried a heterozygous mutation in exon 1 (154C→T) predicting a P47L change. <sup>f</sup>Patients 11 and 12 are heterozygous for the silent 155G→A polymorphism in exon 1 that we found in 20% of our controls. <sup>g</sup>DNA from patients 12 and 13 was analyzed by restriction digestion for known mutations previously identified in the other patients. All mutations so identified were confirmed by sequencing. <sup>h</sup>Not applicable; patient 12 was still alive at 7 years, and patient 13 was still alive at 8 years.

<sup>1</sup>Departments of Neurobiology, and Physical Medicine and Rehabilitation, University of Alabama-Birmingham, Birmingham, Alabama, USA. <sup>2</sup>Departments of Pathology and Neuroscience, Albert Einstein College of Medicine, Bronx, New York, USA. <sup>3</sup>Inserm U.384, Faculté de Médecine, Clermont-Ferrand, France. <sup>4</sup>Service de Neuropédiatrie, Hôpital Saint Vincent de Paul, AP-HP, Paris, France. <sup>5</sup>Department of Pathology and Center for Neurobiology and Behavior, Columbia University College of Physicians & Surgeons, New York, New York, USA. <sup>6</sup>Department of Pathobiological Sciences, Waisman Center and School of Veterinary Medicine, University of Wisconsin, Madison, Wisconsin, USA. Correspondence should be addressed to A.M. (e-mail: [messing@waisman.wisc.edu](mailto:messing@waisman.wisc.edu)).



**Fig. 1** GFAP mutations in Alexander disease patients characterized by DNA sequencing. Mutant sequences are shown in the first two rows and the corresponding normal sequence, in the bottom row. Affected nucleotides in the mutant sequences are shown in italics above each chromatogram, with the predicted amino acid change shown below. In the normal chromatograms, the wild-type codon is bracketed above and the encoded amino acid shown below. The chromatograms illustrated are from the following patients: R79C (patient 1), R79H (patient 2), R239C (patient 6), R239H (patient 7), R258P (patient 8) and R416W (patient 10).

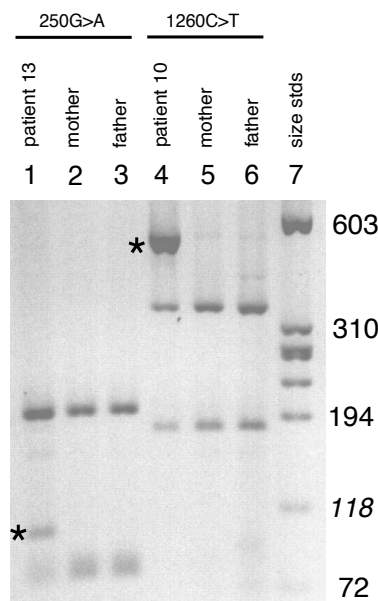
by restriction digestion for the described mutations, followed by sequence analysis for confirmation, showed that one of these patients was heterozygous for the R79C mutation and another, for the R79H mutation (Table 1, patients 12 and 13, respectively). In both cases, restriction digestion of the parental samples identified the corresponding normal sequence. Thus, of 14

Five of the mutations affected the same R239 amino acid, with four resulting in the same substitution to cysteine. One patient (Table 1, patient 4) had a P47L mutation as well as the R239C mutation; the P47L mutation was also absent from all of the controls, but its significance is not yet clear. In addition to these mutations, we found three other base-pair changes in the coding region, but did not pursue these further because they were also present in controls (Table 1). Several Alexander disease samples displayed additional minor sequence differences from the reference human genomic clone in the 5' flanking region, introns 3 and 6, and the 3' UTR (Table 1). We did not analyze these further, because the missense mutations seem to be sufficient to account for the disease in all but 1 of the 11 patient DNA samples sequenced, and no unique base changes in the non-coding region were found in the DNA from the remaining patient (Table 1, patient 11).

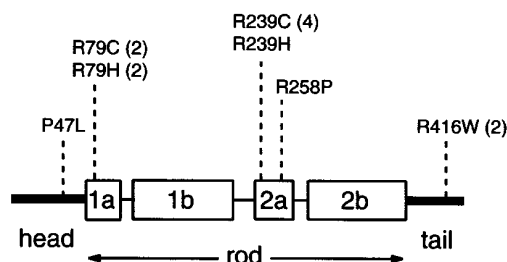
In each case, the Alexander disease patient was heterozygous for the mutation, suggesting a dominant mode of action. Because all the parents were phenotypically normal, we predicted that these mutations arose *de novo*. To test this hypothesis, we obtained DNA samples from the parents of five of the patients (Table 1, patients 3, 5, 6, 8 and 10) and analyzed them by restriction digestion (Fig. 2). None of the parental samples contained the mutations found in the affected children. To expand the pool of parental samples, we obtained DNA from four additional patients with biopsy- or autopsy-proven infantile Alexander disease and their parents. Testing of the patient DNAs

parental DNAs tested, none had the non-conservative mutation found in the affected child. These results show that most cases of pathologically proven Alexander disease are associated with *de novo* mutations in the coding region of GFAP.

The intermediate filaments share common structural domains including a highly conserved core helical rod domain surrounded by less conserved head and tail domains. Our analysis of DNA samples from Alexander disease patients has identified putative disease-causing mutations in four amino acids in the rod and tail domains of GFAP (Fig. 3). All four affected amino acids are arginines that are conserved between mouse, rat and human. Arginine codons have been recognized as particularly prone to mutation, presumably due to methylation of the CpG dinucleotide<sup>10</sup>.



**Fig. 2** Detection of mutations by restriction endonuclease digestion. Appropriate PCR fragments were digested with *AclI* and the products resolved on a 3% agarose gel. Lanes 1–3, PCR fragments from exon 1 for patient 13, her mother and her father, respectively; lanes 4–6, PCR fragments from exon 8 for patient 10, her mother and her father, respectively; lane 7,  $\phi$ x174-HaeIII size standards as indicated in the right margin. In each case, presence of the mutation causes loss of an *AclI* site, with resultant appearance of a novel product and reduction in yield of one or two fragments produced from the normal sequence. Diagnostic of the 250G→A mutation in patient 13 (lane 1) is the appearance of the novel band at 105 bp (asterisk) and reduction in the band at 78 bp. Diagnostic of the 1260C→T mutation in patient 10 (lane 4) is the appearance of the novel band at 529 bp (asterisk) and reduction in the bands at 347 and 182 bp. The parents show normal patterns.



Human diseases have previously been associated with mutations of genes encoding intermediate filaments, including several of the keratins (for review, see ref. 11), desmin<sup>12,13</sup> and nuclear lamins<sup>14</sup>. The *GFAP* R79 mutations correspond to hot spots found for the genes encoding type I keratins K10 and K14 (refs. 11,15,16). The *GFAP* R239 and R258 mutations occur in coil 2A of the rod domain, however, where no other intermediate filament mutation has been reported. The missense mutations of keratin, desmin and lamin genes are generally considered to act in dominant-negative fashions causing loss of function, in part due to the similarity in phenotypes between the human patients and mice with null mutations of the same gene. But the *GFAP* mutations observed in Alexander disease patients most likely act in a dominant gain-of-function fashion, as the phenotype of *Gfap*-null mice is subtle and does not resemble Alexander disease<sup>17–20</sup>.

Our studies indicate that Alexander disease is a genetic disease. Moreover, we suggest that *GFAP* should be evaluated as a candidate gene for adult-onset dominant disorders in which Rosenthal fibers are a prominent feature of the pathology<sup>21,22</sup>. DNA from one of the Alexander disease patients, however, showed no evidence for mutations in the coding region of *GFAP*. It is possible that this patient has duplications of *GFAP*, or unknown promoter mutations that increase *GFAP* transcription, either of which would result in elevated levels of a normal protein. These possibilities are currently under investigation. Rosenthal fibers do form in situations of GFAP excess, such as chronic marked gliosis<sup>23,24</sup> or the transgenic mice that overexpress wild-type *Gfap* (ref. 5). Our results do not exclude the possibility that defects in other genes may be responsible for some cases of Alexander disease. In this regard, a child with a phenotype resembling Alexander disease (but without pathological confirmation) was homozygous for recessive mutations in the gene *NDUFV1*, which encodes a component of mitochondrial complex I (ref. 25). Nevertheless, most cases of Alexander disease can now be placed among the hereditary disorders of intermediate filaments, providing a new neurological disease of genetic origin in which abnormal protein aggregation occurs.

## Methods

**Patient and parental DNA samples.** We isolated DNA by proteinase K digestion of frozen brain, blood or immortalized cell lines from patients with autopsy or biopsy-confirmed diagnoses of Alexander disease. None of these patients had any family history of Alexander disease, and are thus considered sporadic. In several cases, we obtained samples from the parents of affected individuals, and paternity was verified by minisatellite analysis. We obtained control samples from two patients with leukodystrophies other than Alexander disease (childhood ataxia with central hypomyelination<sup>6</sup> and an autosomal dominant leukodystrophy<sup>7</sup>, the latter sample referred to in Table 1 as “control L2”), patients with non-neurological diseases and clinically normal individuals. Of the 13 patients, 8 were of European descent, 1 was Asian and 4 were of unknown ethnicity. Two-thirds of the control population were European with the remainder unknown. More precise ethnic matching was deemed unnecessary based

**Fig. 3** Location of mutations in *GFAP* associated with Alexander disease in relation to protein domain structure of intermediate filaments. The boxes indicate the four  $\alpha$ -helical subdomains within the central rod domain, separated by non-helical linkers. Multiple occurrences of a mutation are indicated by the number shown in parentheses. Although not found in our controls, the P47L mutation may not be disease-related as it occurred in a patient (4, Table 1) who also had the R239C mutation.

on our finding that the mutations arise *de novo* rather than being inherited. Details of the clinical histories and neuropathology have been reported for patients 2 (case 2 in ref. 26), 7 (ref. 27), 9 (case 1 in ref. 26) and 10 (ref. 28), with additional information on patients 4 and 10 reported by Johnson<sup>2</sup>.

**PCR amplifications.** We used PCR to amplify fragments for sequencing. Amplifications typically used DNA (100 ng) in a 100  $\mu$ l reaction, a hot start and 35 cycles. One exception was generation of a fragment of the first exon used to test for the presence of the P47L mutation. For this amplification, the 3' primer contained two base mismatches to introduce a *Bst* site into the wild-type sequence, and previously amplified exon 1 DNA was used as the template. Primer sequences and cycle details are available on request.

**Sequence analysis.** DNA was purified from PCR reactions using Qiaquick PCR purification columns (Qiagen) and sequenced either on a 373A ABI sequencer at the NINDS sequencing facility in Bethesda, Maryland, or on a 377 ABI sequencer at the University of Alabama, Birmingham. Regions sequenced included all of the coding region, from 13 to 204 intronic nucleotides on either side of each exon, and most of the 1,717 nt 5' of the RNA start site, a region sufficient to drive astrocyte-specific transcription in mice<sup>29</sup>. The only segment omitted from the latter was nt –457 to –494 (RNA start site is +1), a region immediately downstream of a poly(T) segment contributed by an *Alu* sequence, which was not sequenced due to technical difficulties. Criteria for identifying heterozygosity included presence of a second nucleotide with a peak height at least 25% that of the normal nucleotide on sequences of both strands, and a reduction of at least 40% in peak height, relative to an adjacent peak, of the normal nucleotide compared with its peak height in a wild-type sequence. Screening of DNA from non-leukodystrophy controls, patients 12 and 13 (Table 1), and parents was performed by restriction digestion. Each of the mutations resulted in loss of an *Aci* site except the P47L mutation, which was screened by introducing a *Bst* site into the wild-type sequence by PCR as described above. Mutations detected by restriction digestion were confirmed by sequencing.

## Acknowledgments

We thank the Brain and Tissue Bank for Developmental Disorders at the University of Maryland (supported by NIH), the National Neurological Specimen Bank, and the Laboratorio di Diagnosi Pre e Postnatale delle Malattie Metaboliche (Istituto G. Gaslini; supported by Telethon project C.20) for samples of Alexander disease tissues from their collections; A. Koepfen and M. Mahadevan for control samples; the AECOM Human Genetics Program and J. Cowell for helping to prepare some of the samples; D. Klimanis, J. Salmon and Y. Yang for processing samples and data analysis; J. Nagle and S. Hollingshead for sequencing; L. Harman for paternity testing; R. Spritz and M. Hutton for advice; the families of Alexander disease patients for encouragement and assistance; and the United Leukodystrophy Foundation for support. The UAB sequencing facility is partially supported by grants from the Tennessee Valley Authority and the Howard Hughes Foundation. During the early stages of this work, M.B. was supported at the NIH by the NINDS intramural program through J.M. Hallenbeck. This project was supported by NIH grants NS-22475 (A.M.) and EY-09331 (J.E.G.), by the Lie Endowment (M.B.), and by the Institut National de la Santé et de la Recherche Médicale, the European Leukodystrophies Association (ELA France), the Biomed 2 EC project and the Jean Pierre and Nancy Boespflug Foundation for Myopathic Research (O.B.-T. and D.R.).

Received 19 May; accepted 16 November 2000.

1. Duckett, S. & Goldman, J.E. in *Pediatric Neuropathology* (ed. Duckett, S.) 620–624 (Williams & Wilkins, Baltimore, 1995).
2. Johnson, A.B. in *Handbook of Clinical Neurology: Neurodystrophies and Neurolipidoses* (ed. Moser, H.G.) 701–710 (Elsevier, Amsterdam, 1996).
3. Johnson, A.B. & Bettica, A. On-grid immunogold labeling of glial intermediate filaments in epoxy-embedded tissue. *Am. J. Anat.* **185**, 335–341 (1989).



4. Iwaki, T., Kume-Iwaki, A., Liem, R.K.H. & Goldman, J.E.  $\alpha$ B-Crystallin is expressed in non-lenticular tissues and accumulates in Alexander's disease brain. *Cell* **57**, 71–78 (1989).
5. Messing, A. *et al.* Fatal encephalopathy with astrocyte inclusions in GFAP transgenic mice. *Am. J. Pathol.* **152**, 391–398 (1998).
6. Leegwater, P.A. *et al.* The gene for leukoencephalopathy with vanishing white matter is located on chromosome 3q27. *Am. J. Hum. Genet.* **65**, 728–734 (1999).
7. Coffeen, C.M. *et al.* Genetic localization of an autosomal dominant leukodystrophy mimicking chronic progressive multiple sclerosis to chromosome 5q31. *Hum. Mol. Genet.* **9**, 787–793 (2000).
8. Brenner, M. *et al.* Characterization of human cDNA and genomic clones for glial fibrillary acidic protein. *Mol. Brain Res.* **7**, 277–286 (1990).
9. Besnard, F. *et al.* Multiple interacting sites regulate astrocyte-specific transcription of the human gene for glial fibrillary acidic protein. *J. Biol. Chem.* **266**, 18877–18883 (1991).
10. Cooper, D.N. & Youssoufian, H. The CpG dinucleotide and human genetic disease. *Hum. Genet.* **78**, 151–155 (1988).
11. Fuchs, E. The cytoskeleton and disease: genetic disorders of intermediate filaments. *Annu. Rev. Genet.* **30**, 197–231 (1996).
12. Goldfarb, L.G. *et al.* Missense mutations in desmin associated with familial cardiac and skeletal myopathy. *Nature Genet.* **19**, 402–403 (1998).
13. Sjöberg, G. *et al.* A missense mutation in the desmin rod domain is associated with autosomal dominant distal myopathy, and exerts a dominant negative effect on filament formation. *Hum. Mol. Genet.* **8**, 2191–2198 (1999).
14. Bonne, G. *et al.* Mutations in the gene encoding lamin A/C cause autosomal dominant Emery-Dreifuss muscular dystrophy. *Nature Genet.* **21**, 285–288 (1999).
15. Coulombe, P.A. *et al.* Point mutations in human keratin 14 genes of epidermolysis bullosa simplex patients: genetic and functional analyses. *Cell* **66**, 1301–1311 (1991).
16. Irvine, A.D. & McLean, W.H.I. Human keratin diseases: the increasing spectrum of disease and subtlety of the phenotype-genotype correlation. *Br. J. Dermatol.* **140**, 815–828 (1999).
17. Gomi, H. *et al.* Mice devoid of the glial fibrillary acidic protein develop normally and are susceptible to scrapie prions. *Neuron* **14**, 29–41 (1995).
18. Pekny, M. *et al.* Mice lacking glial fibrillary acidic protein display astrocytes devoid of intermediate filaments but develop and reproduce normally. *EMBO J.* **14**, 1590–1598 (1995).
19. McCall, M.A. *et al.* Targeted deletion in astrocyte intermediate filament (*Gfap*) alters neuronal physiology. *Proc. Natl. Acad. Sci. USA* **93**, 6361–6366 (1996).
20. Liedtke, W., Edelmann, W., Chiu, F.-C., Kucherlapati, R. & Raine, C.S. Experimental autoimmune encephalomyelitis in mice lacking glial fibrillary acidic protein is characterized by a more severe clinical course and an infiltrative central nervous system lesion. *Am. J. Pathol.* **152**, 251–259 (1998).
21. Howard, R.S. *et al.* A familial disorder associated with palatal myodonus, other brainstem signs, tetraparesis, ataxia and Rosenthal fibre formation. *J. Neurol. Neurosurg. Psychiatry* **56**, 977–981 (1993).
22. Schwankhaus, J.D., Paris, J.E., Gullledge, W.R., Chin, L. & Currier, R.D. Hereditary adult-onset Alexander's disease with palatal myodonus, spastic paraparesis, and cerebellar ataxia. *Neurology* **45**, 2266–2271 (1995).
23. Rosenthal, W. Über eine eigenthümliche, mit syringomyelie complicirte geschwulst des rückenmarks. *Beitr. Pathol. Anat.* **23**, 111–143 (1898).
24. Herndon, R.M., Rubinstein, L.J., Freeman, J.M. & Mathieson, G. Light and electron microscopic observations on Rosenthal fibers in Alexander's disease and in multiple sclerosis. *J. Neuropathol. Exp. Neurol.* **29**, 524–551 (1970).
25. Schuelke, M. *et al.* Mutant NDUFB1 subunit of mitochondrial complex I causes leukodystrophy and myoclonic epilepsy. *Nature Genet.* **21**, 260–261 (1999).
26. Iwaki, A. *et al.* Accumulation of  $\alpha$  B-crystallin in brains of patients with Alexander's disease is not due to an abnormality of the 5'-flanking and coding sequence of the genomic DNA. *Neurosci. Lett.* **140**, 89–92 (1992).
27. Klein, E.A. & Anzil, A.P. Prominent white matter cavitation in an infant with Alexander's disease. *Clin. Neuropathol.* **13**, 31–38 (1994).
28. Reichard, E.A.P., Ball, W.S. & Bove, K.E. Alexander disease—a case report and review of the literature. *Pediatr. Pathol. Lab. Med.* **16**, 327–343 (1996).
29. Brenner, M., Kisseberth, W.C., Su, Y., Besnard, F. & Messing, A. GFAP promoter directs astrocyte-specific expression in transgenic mice. *J. Neurosci.* **14**, 1030–1037 (1994).
30. Isaacs, A., Baker, M. & Hutton, M. Determination of the gene structure of human GFAP and absence of coding region mutations associated with frontotemporal dementia with Parkinsonism linked to chromosome 17. *Genomics* **51**, 152–154 (1998).

