

Results of Morphological Studies of Various Forms of Chronic Tonsillitis



Firdavs N. Nordjigitov, Jamolbek A. Djuraev

Abstract: Traditionally, the diagnosis of chronic tonsillitis is based on the assessment of clinical signs. It should also be born in mind that the morphological examination of the tonsils is an invasive method and can only be used to confirm the diagnosis after tonsillectomy, and not as a routine examination of patients with chronic tonsillitis. Morphological changes in palatine tonsils during chronic tonsillitis are represented by the proliferation of connective tissue in the thickness of the lymphoid tissue, the presence of necrotic foci, damage to the walls of capillary vessels, and disturbances in the crypt epithelium. In the case of the toxic-allergic form of chronic tonsillitis, the process of inflammation in the palatine tonsils proceeds more actively than in the simple form of chronic tonsillitis. However, these changes are not specific. Morphological changes are usually verified by examining the tissue of the tonsils their removal.

Key words: Palatine Tonsil, Chronic Tonsillitis, Infiltration, Lacuna, Epithelium.

I. INTRODUCTION

Today, the prevalence of chronic tonsillitis (CT) has increased several times and reaches 5-10% in adults [1] and 12-15% in children [3]. According to some authors, the prevalence of chronic tonsillitis can reach 37% in adults and 63% in children [2]. In the structure of ENT pathology, CT occupies one of the leading places and accounts for 13-35% [4,5]. This, in turn, indicates that the CT problem has not yet been resolved. Despite the fact that chronic pathology of the palatine tonsils (PT) is mainly characteristic of childhood, it is also significantly common among the adult working-age population [6,7]. Thus, chronic tonsillitis is a socially significant disease and requires new approaches to solving this problem [8,9]. CT is an active, with periodic exacerbations, chronic inflammatory focus of infection in the tonsils with a general infectious-allergic reaction [10]. In our country, the most common are two classifications of CT: according to Soldatov and according to Preobrazhensky-Palchun. According to I.B. Soldatov, numerous clinical and morphological varieties of chronic tonsillitis are reduced to two forms - compensated and decompensated CT [11-15].

Manuscript received on 25 November 2021 | Revised Manuscript received on 06 December 2022 | Manuscript Accepted on 15 December 2023 | Manuscript published on 30 December 2023.

*Correspondence Author(s)

Firdavs N. Nordjigitov*, Student, Department of Otolaryngology and Stomatology Tashkent, Magistracy Tashkent Medical Academy, 100109, Uzbekistan. E-mail: nordjigitovfirdavsent@gmail.com

Jamolbek A. Djuraev, PhD, Associate Professor, Department of Otolaryngology and Stomatology Tashkent, Magistracy Tashkent Medical Academy, 100109, Uzbekistan. E-mail: drdjuraev@mail.ru

© The Authors. Published by Lattice Science Publication (LSP). This is an open access article under the CC-BY-NC-ND license (<http://creativecommons.org/licenses/by-nc-nd/4.0/>)

The stages of development of pathomorphological changes in the structure of the palatine tonsils, as well as the formation of general and local associated diseases (metatonsular complications) are reflected in the classification of B.S. Preobrazhensky - V.T. Palchun [16,17].

The cause of chronic tonsillitis is considered to be a pathological transformation (development of chronic inflammation) of the physiological process of the formation of immunity in the tissue of the palatine tonsils, where the normally existing limited process of inflammation stimulates the production of antibodies. The body's immune system normally maintains the activity of physiological inflammation in the tonsils at a level sufficient for the formation of antibodies to various microbial agents entering the crypts. Due to local and general reasons, microorganisms can overcome the protective immune barrier, limited physiological inflammation in crypts becomes pathological and spreads to the parenchyma of the tonsils [18-23][24][25][26][27][28].

The purpose of the study was - to study the morphological research of the clinical forms of chronic tonsillitis.

II. MATERIAL AND METHODS.

A total of 60 people were examined. In accordance with the objectives of the study, all patients included in the study were divided into 2 groups:

Group 1 - patients with uncomplicated (simple) form of chronic tonsillitis (31 patients);

Group 2 - patients with complicated (toxic-allergic grade 1-2) chronic tonsillitis (29 patients).

Group I included patients with only local signs of CT:

- congestive hyperemia of the anterior palatine arches (sign of Giese);
- edema of the upper edges of the anterior and posterior palatine arches (sign of Zak);
- roll-like thickening of the edges of the anterior arches (sign of Preobrazhensky);
- Fusion and adhesions of the tonsils with the arches and a triangular fold;
- loosened surface of the palatine tonsils;
- liquid pus or caseous-purulent plugs in the lacunae.

Group II included patients who, in addition to complaints from the pharynx, presented general complaints:

- Periodic functional disorders of cardiac activity,
- Heartbeat, abnormal heart rhythms, pain in the region of the heart without exacerbation;
- Pain in the joints without exacerbation;



Results of Morphological Studies of Various Forms of Chronic Tonsillitis

- Prolonged low-grade fever.

Also, the second group of examined patients included those patients in whom the disease was accompanied by local complications (paratonsillar abscess, parafangitis) and general diseases, which were confirmed by the corresponding diagnoses: rheumatism, arthritis, acquired heart defects, diseases of the urinary system.

Research inclusion criteria:

- the presence of chronic inflammation of the tonsils;
- age over 18 years old;
- signed informed consent to participate in the research and the processing of personal data.

Exclusion criteria from the study:

- inflammatory diseases of other localization;
- decompensated flow of concomitant pathology;
- conditions that impede the implementation of the study;

Table 1. Frequency of Occurrence of Morphological Changes in Palatine Tonsils in Patients with Toxic-Allergic CT in Histological Examination

Morphological trait	Number of patients (n)	Frequency of occurrence (P±m%)
Infiltration of the epithelium of the walls of the lacunae	57	82.9±3.5
Detritus of lacunae	45	71.8±4.5
Reactive hyperplasia of lymphoid follicles and interfollicular space	38	61.7±4.1
Expansion of lacunae	41	61.7±4.1
Obliteration of lacunae	29	33.6±4.9
Detritus microorganisms	22	24.8±3.93

When analyzing the data obtained, it was revealed that in most patients with toxic-allergic form of CT, infiltration of the epithelium of the walls of the lacunae of the palatine tonsils was observed ($85.96 \pm 3.25\%$). This is due to the fact that the main changes in chronic tonsillitis occur precisely from the side of the epithelial cover. These changes are usually expressed in lacunae.

More than half of the patients had detritus in the lacunae ($72.81 \pm 4.17\%$), which can also be a sign of chronic inflammation in the palatine tonsils due to excessive desquamation of the lacunae epithelium (Fig. 1).

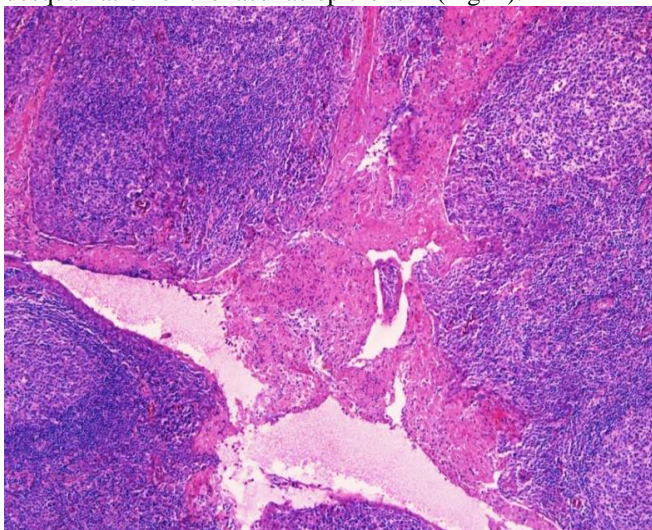


Figure 1. Expanded Tonsil Crypts, Filled with Tissue Detritus, Leukocytes. Staining with Hematoxylin and Eosin. Magnification X 50

A frequent sign of an inflammatory process in the tonsils is reactive hyperplasia of the lymphoid follicles and interfollicular space ($61.7 \pm 4.1\%$), as well as widening of the

- refusal of the subject to participate in the study;

- a history of tonsillectomy;

- under 18 years of age.

The study was carried out in the Department of Otorhinolaryngology of the TMA Multidisciplinary Clinic.

III. STUDY RESULTS

Patients with toxic-allergic form of CT after tonsillectomy underwent a morphological examination of the tissue of the removed tonsils to confirm the diagnosis and identify changes in the tissue during CT.

The results of histological examination of 60 palatine tonsils were analyzed. The frequency of detection of morphological signs of CT is presented in Table 1.

lacunae ($61.7 \pm 4.1\%$). During ultrasound examination, these signs can be identified as pronounced hypoechogenicity in patients with toxic-allergic CT.

Signs such as obliteration of lacunae ($33.6 \pm 4.9\%$) and the presence of microorganisms in detritus ($24.8 \pm 3.93\%$) (Fig. 2) were found in less than half of the tonsils studied.

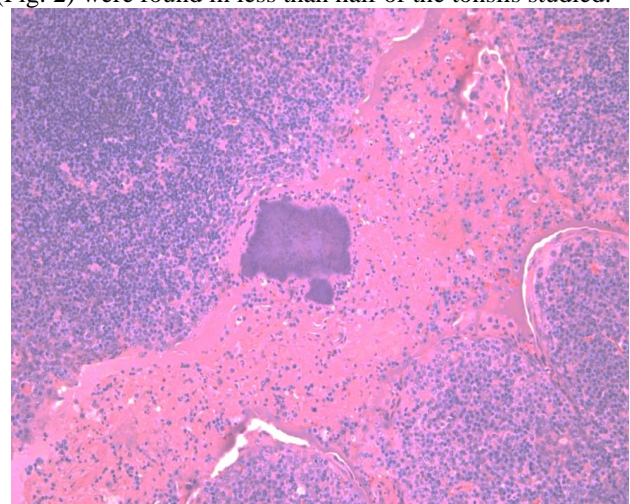


Figure 2. Expanded Tonsil Crypts, Filled with Tissue Detritus, Leukocytes, Actinomycete Druses. Staining with Hematoxylin and Eosin. Magnification X 100

However, it is difficult to characterize the histological picture of CT, mainly because in the palatine tonsils the border between norm and pathology is relatively expressed.

This is due to the fact that the tissue of the tonsils itself consists of lymphocytes - cells involved in inflammation, in this regard, it is difficult to establish which changes are associated with the normal functional activity of the tonsils as a lymphoid organ, and which can be attributed to a pathological inflammatory process. According to the classification of morphological changes occurring in the palatine tonsils during CT, there is, in particular, lacunar - parenchymal (total) CT, in which PT take the form of a so-called "sponge", the stroma of which is connective tissue, and the contents are pus, detritus and caseous masses. With ultrasound examination, such pronounced inflammatory and destructive changes in the tonsils may be accompanied by the presence of hypochoic areas of lymphadenoid tissue. As the results of the study showed, in patients with a simple form of chronic tonsillitis, tonsils with hyperechoic areas predominated (72.13±5.74%), in contrast to patients with toxic-allergic form of chronic tonsillitis (40.7±5.3%), which are characterized by PT with hypochoic areas, which corresponded to morphological picture. The specificity of this trait was 59.3%, and the sensitivity was 72.1%.

IV. CONCLUSIONS

Thus, it should also be taken into account that the morphological examination of the tonsils is an invasive method and can only be used to confirm the diagnosis after tonsillectomy, and not as a routine examination of patients with CT. Morphological changes in PT during CT are represented by the proliferation of connective tissue in the thickness of the lymphoid tissue, the presence of necrotic foci, damage to the walls of capillary vessels, and disturbances in the crypt epithelium. In the case of the toxic-allergic form of chemotherapy, the process of inflammation in the PT proceeds more actively than in the simple form of CT. However, these changes are not specific. Morphological changes are usually verified by examining the tissue of the tonsils after their removal.

DECLARATION STATEMENT

Funding	No, I did not receive.
Conflicts of Interest	No conflicts of interest to the best of my knowledge.
Ethical Approval and Consent to Participate	No, the article does not require ethical approval and consent to participate with evidence.
Availability of Data and Material	Not relevant.
Authors Contributions	I am only the sole author of the article.

REFERENCES

- Ågren K. et al. What is wrong in chronic adenoiditis/tonsillitis immunological factor //International journal of pediatric otorhinolaryngology. – 1999. – T. 49. – C. S137-S139. [https://doi.org/10.1016/S0165-5876\(99\)00148-2](https://doi.org/10.1016/S0165-5876(99)00148-2)
- Avramović V. et al. Quantification of cells expressing markers of proliferation and apoptosis in chronic tonsillitis //Acta Otorhinolaryngologica Italica. – 2015. – T. 35. – №. 4. – C. 277.
- Belz G. T., Heath T. J. The epithelium of canine palatine tonsils //Anatomy and embryology. – 1995. – T. 192. – №. 2. – C. 189-194. <https://doi.org/10.1007/BF00186007>
- Bondareva G. P., Antonova N. A., Chumakov P. L. Immunomorphological features of chronic tonsillitis //Vestnik otorinolaringologii. – 2013. – №. 3. – C. 12-16.
- Casteleyn C. et al. Ultramicroscopic examination of the ovine tonsillar epithelia //The Anatomical Record: Advances in Integrative

- Anatomy and Evolutionary Biology. – 2010. – T. 293. – №. 5. – C. 879-889. <https://doi.org/10.1002/ar.21098>
- Chikovani N. V., Gabuniia U. A., Lomaia T. G. Morphology of the palatine tonsil lymphocytes in chronic tonsillitis using data of electron microscopic radioautography //Arkhiv patologii. – 1989. – T. 51. – №. 2. – C. 55-59.
- Fidan V. et al. Morphological asymmetry in tonsilla palatina by handedness in patients with chronic tonsillitis //Neurology, Psychiatry and Brain Research. – 2012. – T. 18. – №. 1. – C. 19-21. <https://doi.org/10.1016/j.npbr.2011.11.004>
- Honma M. et al. Co-expression of fibroblastic, histiocytic and smooth muscle cell phenotypes on cultured adherent cells derived from human palatine tonsils: a morphological and immunocytochemical study //Pathology international. – 1995. – T. 45. – №. 12. – C. 903-913. <https://doi.org/10.1111/j.1440-1827.1995.tb03415.x>
- Kuki K., Hotomi M., Yamanaka N. A study of apoptosis in the human palatine tonsil //Acta oto-laryngologica. Supplementum. – 1996. – T. 523. – C. 68-70.
- Kusano K. et al. Helicobacter pylori in the palatine tonsils of patients with IgA nephropathy compared with those of patients with recurrent pharyngotonsillitis //Human pathology. – 2007. – T. 38. – №. 12. – C. 1788-1797. <https://doi.org/10.1016/j.humpath.2007.04.012>
- Luginbuhl A., Sanders M., Spiro J. D. Prevalence, morphology, and prognosis of human papillomavirus in tonsillar cancer //Annals of Otolaryngology & Laryngology. – 2009. – T. 118. – №. 10. – C. 742-749. <https://doi.org/10.1177/000348940911801010>
- Mogoantă C. A. et al. Chronic tonsillitis: histological and immunohistochemical aspects //Rom J Morphol Embryol. – 2008. – T. 49. – №. 3. – C. 381-386.
- Nave H., Gebert A., Pabst R. Morphology and immunology of the human palatine tonsil //Anatomy and embryology. – 2001. – T. 204. – №. 5. – C. 367-373. <https://doi.org/10.1007/s004290100210>
- Noussios G. et al. Morphological study of development and functional activity of palatine tonsils in embryonic age //Acta otorhinolaryngologica italica. – 2003. – T. 23. – №. 2. – C. 98-101.
- Nurov U. I. et al. Morphology of palatine tonsils in chronic tonsillitis in identical twins //International Engineering Journal For Research & Development. – 2020. – T. 5. – №. SPECIAL ISSUE. – C. 6-6.
- Palmer M. V., Thacker T. C., Waters W. R. Histology, immunohistochemistry and ultrastructure of the bovine palatine tonsil with special emphasis on reticular epithelium //Veterinary immunology and immunopathology. – 2009. – T. 127. – №. 3-4. – C. 277-285. <https://doi.org/10.1016/j.vetimm.2008.10.336>
- Qosimov Q. К-К-Косимов. Морфологические и микологические исследования миндалин у больных хроническим тонзиллитом //Архив исследований. – 2020.
- Saltanova Z. E. Chronic tonsillitis, etiological and pathogenetic aspects of the development of metatonsillar complications //Vestnik otorinolaringologii. – 2015. – T. 80. – №. 3. – C. 65-70. <https://doi.org/10.17116/otorino201580365-70>
- Torre V. et al. Morphological study of the palatine tonsils: clinical and histopathological considerations //Acta otorhinolaryngologica Italica: organo ufficiale della Societa italiana di otorinolaringologia e chirurgia cervico-facciale. – 2000. – T. 20. – №. 1. – C. 40-46.
- Torre V. et al. Palatine tonsils in smoker and non-smoker patients: a pilot clinicopathological and ultrastructural study //Journal of oral pathology & medicine. – 2005. – T. 34. – №. 7. – C. 390-396. <https://doi.org/10.1111/j.1600-0714.2005.00319.x>
- Velinova M. et al. New histochemical and ultrastructural observations on normal bovine tonsils //Veterinary Record. – 2001. – T. 149. – №. 20. – C. 613-617. <https://doi.org/10.1136/vr.149.20.613>
- Yamamoto Y. et al. Distribution and morphology of macrophages in palatine tonsils //Acta Oto-Laryngologica. – 1988. – T. 105. – №. sup454. – C. 83-95. <https://doi.org/10.3109/00016488809125010>
- Yildirim N., Şahan M., Karslıoğlu Y. Adenoid hypertrophy in adults: clinical and morphological characteristics //Journal of International Medical Research. – 2008. – T. 36. – №. 1. – C. 157-162. <https://doi.org/10.1177/147323000803600120>
- Shahlee, S., & Ahmad, S. (2020). Morphological Processes of Neologisms in Social Media Among the Public Figures. In International Journal of Innovative Technology and Exploring Engineering (Vol. 9, Issue 3, pp. 2526-2531).

Results of Morphological Studies of Various Forms of Chronic Tonsillitis

- <https://doi.org/10.35940/ijitee.b7275.019320>
25. Suárez-Domínguez, E. (2019). Surface Morphology: Theoretical Model and Correlation with Experimental Results. In International Journal of Engineering and Advanced Technology (Vol. 9, Issue 1, pp. 3308–3313). <https://doi.org/10.35940/ijeat.a1455.109119>
 26. Muluk, Dr. S., & Grover, Dr. I. (2023). Aesthetics of Claps in Removable Partial Denture - A Literature Review. In International Journal of Advanced Dental Sciences and Technology (Vol. 2, Issue 4, pp. 1–4). <https://doi.org/10.54105/ijadst.d1009.062422>
 27. Patel, Mr. K., Bhatnagar, Mr. M., Thakor, Mr. N., & Dodia, M. R. V. (2022). Evaluation of Protein and Carbohydrate Content of Some Anti Diabetic Medical Plants. In International Journal of Advanced Medical Sciences and Technology (Vol. 2, Issue 3, pp. 1–6). <https://doi.org/10.54105/ijamst.c3027.042322>
 28. Shujauddin, Dr. M., Alam, S., Rehman, S., & Ahmad, M. (2023). Scientific Evaluation of A Unani Pharmacopoeia-Based Formulation on BPH in Animal Model. In International Journal of Preventive Medicine and Health (Vol. 4, Issue 1, pp. 1–8). <https://doi.org/10.54105/ijpmh.a1032.114123>

Disclaimer/Publisher's Note: The statements, opinions and data contained in all publications are solely those of the individual author(s) and contributor(s) and not of the Lattice Science Publication (LSP)/ journal and/ or the editor(s). The Lattice Science Publication (LSP)/ journal and/or the editor(s) disclaim responsibility for any injury to people or property resulting from any ideas, methods, instructions or products referred to in the content.