

## FEATURES OF INFLAMMATORY PROCESSES OF THE NEO-VAGINA

Shopulotova Zarina Abdumuminovna<sup>1</sup>, Uktamova Yulduz Umarovna<sup>2</sup>, Azimova Sevinch Akmal kizi<sup>3</sup>

<sup>1</sup>Samarkand State Medical University, assistant of department Obstetrics and gynecology №1

<sup>2,3</sup>Samarkand State Medical University, student of 620 group

<https://doi.org/10.5281/zenodo.10395582>

**Abstract.** *Colpopoiesis is an operation to form an artificial vagina, which is performed in the congenital absence of a vagina. The purpose of the study is to maximize the quality of life of patients so that a woman can create a family and have a full sex life. The sample population of the study consisted of 30 patients after sigmoid colpopoiesis, operated on in the maternity ward of the Samara State Medical University clinic. The control group consisted of 20 women without developmental anomalies and with a natural vagina. During the study, we studied the condition of the neovagina and natural vagina using a bacteriological research method, colpotest with determination of the pH of the environment, and histological analysis of the neovagina. The state of the intravaginal environment in patients with artificial vagina was assessed. Based on the data obtained, the management tactics for patients with artificial vagina were optimized.*

**Keywords:** *neovagina, vaginal aplasia, sigmoid colpopoiesis, uterine aplasia b Rokitansky-Küstner-Hausen syndrome.*

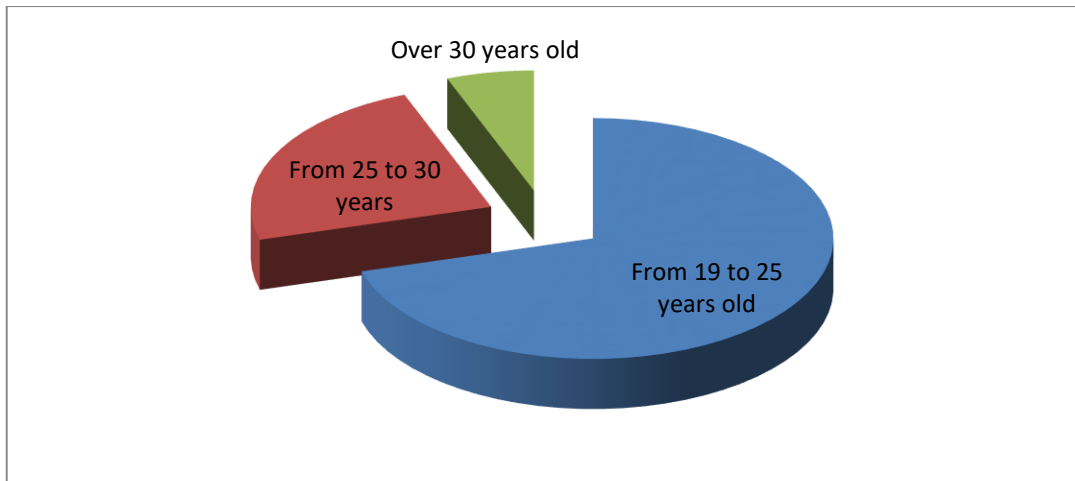
**Relevance.** **Inflammatory diseases of the female genital organs** are one of the most common groups of pathologies in gynecology. They affect all parts of the woman's reproductive system (D.M. Nuradilova 2015). Currently, gynecology allows reconstructive surgery for congenital aplasias and hypoplasias of the uterus and vagina. Such patients acquire a new vagina – a neovagina. Timely provision of medical care to patients with this condition is a priority, on which the prognosis of future sexual life and the patient's adaptation to society depends.

Neo vagina is a vagina that is artificially created using autografts for various pathologies of the development of internal organs with impaired development of the vagina. Colpopoiesis is used to successfully create a new vagina, which is most often used for congenital malformations. As a result of colpopoiesis, women have the opportunity to have an active sex life, however, difficulties arise in diagnosing inflammatory diseases of the new vagina and this affects even greater study of the vaginal microbiome.

**Purpose of the study:** improve the management of women with neovaginitis after sigmoid colpopoiesis.

**Materials and methods of research.** A study on the condition of the vagina after colpopoiesis was carried out in the gynecological department of the multidisciplinary clinic of SamSMU. 30 women with aplasia of the vagina and uterus were taken and underwent colpopoiesis surgery. A control group of 20 healthy women was also taken.

General clinical research methods were used: general blood test and general urinalysis, ECG, ultrasound before and after surgery, and also special research methods were used (bacterial culture of vaginal discharge, colpotest, histological analysis of neovaginal smears).



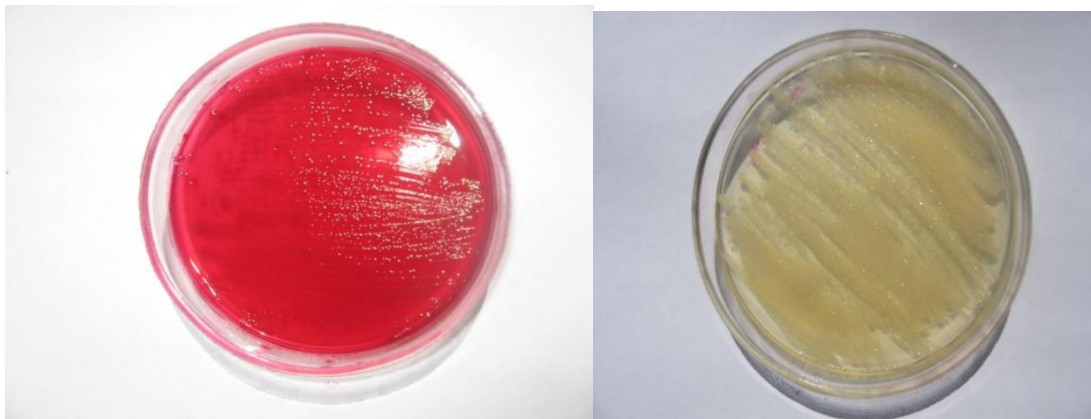
**Figure 1. Age distribution of patients.**

Bacteriological examination of the contents of the neovagina was carried out in the laboratory of the clinic by agreement. This method is used to diagnose pathological biological disorders of the vaginal microflora:

\* Identification of microorganisms that cause the development of infectious and inflammatory processes in the vagina and pelvic organs;

\* For the diagnosis of nonspecific bacterial vaginosis / vulvovaginitis, bacterial vaginosis, candidiasis vulvovaginitis.

The results are interpreted by the attending physician taking into account the patient's complaints, medical history, clinical manifestations of the disease and the exclusion of sexually transmitted diseases.



**Figure 2. Bacteriological cultures of microflora**

This study also used cytological collection and determination of the type of microflora of secretions from the female genital tract, based on the data of which sensitivity to antibiotics was determined.

Colpo test (measuring the pH of vaginal contents) was carried out using special strips. A decrease in pH indicates acidification, a shift in the acid-base state to the acidic side. Thus, if the value is higher than 7.0 compared to the pH standard, this indicates alkalization.

Histological examination of neovagina carried out using excisional and incisional methods in the preoperative and postoperative period. When examining the material taken, hematoxylin-eosin and Van Gieson staining methods were used. The finished preparations were examined under a microscope at 150- and 450-times magnification.

Ultrasound examination was performed on a Toshiba (Canon) Aplio 300 device using transabdominal and transvaginal sensors with a frequency of 5 MHz.

All received materials were subjected to automatic statistical processing. For variational and statistical processing of the research results, the Statistica6.0 program was used to determine the key variational indicators of the mean (M), error of the mean (m) and standard deviation (p).

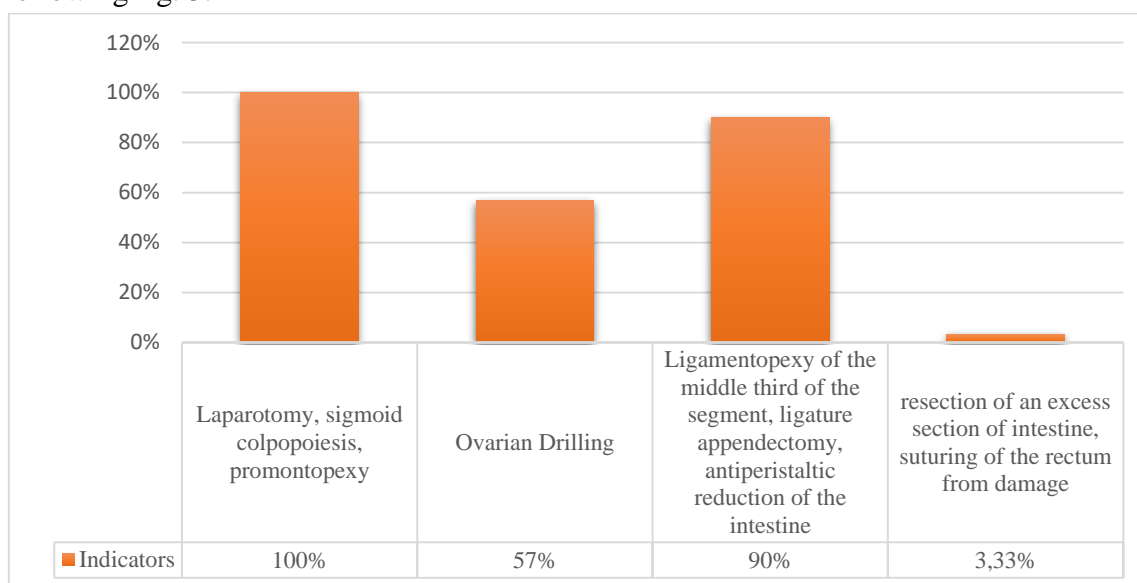
The reliability of the results obtained was determined using the Student's test. When the P value was less than 0.05, the difference between the two means was considered significant. The reliability level was at least 95%.

**Research results and discussion.** Mostly, the age was at puberty (from 12 to 18 years), at which the main complaint was the absence of menarche. On average, the age of the patients at the time of diagnosis of Rokitansky – Küstner – Hausen syndrome was  $14.8 \pm 1.15$  years.

During a preliminary ultrasound examination, it was confirmed that the uterus or its congenital hypoplasia was absent in the presence of ovaries. In some patients (86.7%), the structure of the ovaries also changed, i.e. polycystic changes were observed in 40%, cysts in the right or left ovary in 16.7%, and ovarian hypoplasia in 30%.

Microscopic examination of most of these patients showed a fuchsin yellow staining of tissue removed during Wangison staining, indicating the presence of fetal mesenchymal tissue in the area of vaginal hypoplasia.

Subsequently, all patients underwent surgical treatment to create an artificial vagina. At the same time, based on the patients' data, the scope of the operation expanded, which can be seen in the following fig. 3.



**Figure 3. Scope of surgical interventions performed**

All patients underwent a complete clinical data analysis. Upon admission, patients complained of frequent vaginitis, a large amount of discharge from the genital tract, frequent disruption of the vaginal biocenosis, and so on.

An analysis of patient complaints is given in Table 3.1.

As you can see, all patients had complaints characteristic of bacterial vaginosis, and they are comparable to the data of patients with a natural vagina with bacterial vaginosis.

*Table 1.*

*Analysis of complaints data from patients of the main group*

No.	Complaints	Abs (n=30)	%
1	a large amount of discharge from the genital tract	thirty	100.0 _
2	Frequent vaginitis	25	83.33
3	Presence of odor in the discharge	23	76.7
4	Burning and itching	15	50.0
5	Burning sensation when urinating	18	60.0
6	Pain during intercourse	8	26.7
7	Foreign body sensation	1	3.33

As can be seen from the table, the indicators of the main group, although different from the control group, were within normal limits. In patients over 40 years of age (6.7%), an increase in ESR of more than 15 mm/h. Due to anemia, a decrease in color index and hematocrit was observed.

In a general urine analysis, salts (usually oxalates) were detected in a third of patients, the presence of a large amount of epithelium was noted by half (50%) of the patients in the main group, and epithelium of 5-6-7 visual fields was present in 26.7% of patients.

The presence of mucus was observed in all patients of the main group and in 10% of patients in the control group.

The presence of protein in the urine was observed in 23.3% of patients in the main group, but the amount of protein varied from 0.033 to 1 g/l.

Leukocytes were completely detected in 33.3% of patients in the main group, a significant number - in 40%, 5-6-7 in the field of view - in 26.7%. In the control group, these figures were 5%, 10% and 15%, respectively.

The presence of yeast was present in all patients of the main group and only in 15% of patients in the control group.

According to the results of the colpo test, in patients of the main group, a slightly acidic environment was observed in 30%, almost neutral in 53.3% and alkaline in 16.7% of women from the main group.

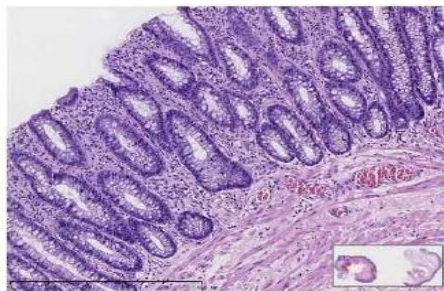
*table 2*

*Results of a general blood test in examined patients after surgery.*

No.	Index	Main group	Control group	p
1	Hemoglobin (g/l)	79.1±5.32	94.2±9.41	<0.0 5
2	Red blood cells (10 <sup>12</sup> /l)	3.6±1.1	4.1±0.79	<0.0 5
3	Leukocytes (10 <sup>9</sup> /l)	6.12±2.07	5.18±1.38	<0.0 5
4	Color index	0.80±0.02	0.85±0.03	<0.0 5
5	Hematocrit (%)	32.5±4.12	37.9±2.85	<0.0 5
6	Reticulocytes (%)	1.02±0.03	0.8±0.06	<0.0 5
7	Platelets (10 <sup>9</sup> /l)	247.3±36.5	217.4±29.46	<0.0 5
8	ESR (mm/hour)	11.3±4.07	7.2±2.11	<0.0 5

Histological examination of curettage of a new vaginal smear preserved the structural features and morphological histological type of the sigmoid colon (a significant accumulation of lymphocytes is located on the proper plates of the mucous and submucosal tissues; the outer longitudinal layer is not continuous in the muscular layer; the serous membrane has a normal structure), but a number of phenomena characteristic of a bacterial inflammatory process were observed.

Smears of neovaginal lesions had an exudative inflammatory process (66.7%) with congestion of capillaries and inflammatory cell infiltration. Intense staining of the smears was observed. In other patients' inflammatory processes were alterative in nature.



**Figure 4. Morphological examination of the neovagina**

**Conclusions.** In the immediate and long-term periods after sigmoid colpopoiesis, patients most often suffer from vaginosis. Which requires periodic treatment and adherence to a careful sanitary regime of the artificial vagina. Women in the postoperative period need to be more careful in relation to hypothermia, heavy physical labor, and violations of personal hygiene rules, since they have a greater susceptibility to vaginitis and vaginosis. As complications, the patients noted impaired sexual life, constant discharge and unpleasant odor, which caused their mental state and family life to suffer. Possible reasons for the development of inflammatory diseases of the neovagina after sigmoid colpopoiesis in the immediate and long-term periods are the histological structure of the neovagina with its pH environment. Violation of the pH balance leads to the active reproduction of conditionally pathogenic and pathogenic microflora, as well as fungal flora, which in turn causes vaginosis. The structure of inflammatory diseases of the neovagina after sigmoid colpopoiesis was represented mainly by gram-negative bacilli, gram-positive cocci, *Escherichia coli* and fungal flora to an equal extent.

## REFERENCES

1. Адамян Л. В. и др. Способ хирургической коррекции при аплазии влагалища с функционирующей замкнутой маткой. – 1999.Кругляк Д. А. и др. Синдром Майера-Рокитанского-Кюстера-Хаузера: современные возможности бескровного формирования неовлагалища //Репродуктивное здоровье детей и подростков. – 2021. – Т. 17. – №. 1. – С. 40-48.
2. Аникиев А. В. и др. Женская гипоспадия в сочетании со стенозом артифициального интроитуса у больной с идиопатической внутриутробной вирилизацией //Андрология и генитальная хирургия. – 2018. – Т. 19. – №. 4.
3. Гараева М. А. Становление микрофлоры влагалища женщин //Молодежь, наука, медицина. – 2020. – С. 43-43.
4. Гусак Ю. К., Ришук С. В., Тарасов В. Н., Гусак В. Н Инфекционные заболевания влагалища. Поиски оптимального решения в их терапии. защита или нападение? (обзор литературы) // Вестник новых медицинских технологий. Электронное издание. – 2019. – № 4. – С. 22-40. – DOI 10.24411/2075-4094-2019-16485. – EDN XDHULN.
5. Журавлева В. И., Галаутдинова Д. И. Эффективность лечения аплазии влагалища методом брюшинного кольпопозеза на примере синдрома Майера-Рокитанского-Кюстера-Хаузера //Два сердца как одно. – 2015. – С. 40-45.
6. Захаренкова Т. Н. и др. Акушерство и гинекология. – 2017. Кругляк, Д. А., Батырова, З. К., Уварова, Е. В., Ипатова, М. В., Буралкина, Н. А., Маланова, Т. Б., ... & Чупрынин, В. Д. (2018). Способ прогнозирования эффективности кольпоэлонгации у пациенток с аплазией влагалища. Изобретение РИД



7. Остонакулова Ф. Б., Маматкулова М. Д., Негмаджанов Б. Б. Усовершенствованный сигмоидальный кольпопоз у пациенток с синдромом Майера-Рокитанского //Достижения науки и образования. – 2020. – №. 5 (59). – С. 56-59.
8. Панделис Ц., Василеос К., Ефимиос Д. Обследование, тактика ведения и лечение врожденных аномалий влагалища в пубертатном периоде //Репродуктивное здоровье детей и подростков. – 2019. – Т. 15. – №. 2.
9. Bazarova Z. HOMILADORLARDA PREEKLAMPSIYANING SOMATIK KASALLIKLARGA TA’SIRI //Евразийский журнал медицинских и естественных наук. – 2023. – Т. 3. – №. 10. – С. 52-55.
10. Iskandarovna T. N. HYPERPLASTIC PROCESSES IN PREMENOPAUSAL AGE WOMEN //JOURNAL OF BIOMEDICINE AND PRACTICE. – 2023. – Т. 8. – №. 3.
11. Khudoyarova D. R., Shopulotova Z. A., Solieva Z. M. PREVENTION OF COMPLICATIONS IN PREGNANT WOMEN WITH CHRONIC PYELONEPHRITIS //Бюллетень студентов нового Узбекистана. – 2023. – Т. 1. – №. 5. – С. 25-29.
12. Rakhimovna K. D., Abdumuminovna S. Z. Traumatization of the genital organs. – 2022.
13. Shopulotova Z. COMPARATIVE ANALYSIS OF CLINICAL CASES OF EXACERBATION OF CHRONIC PYELONEPHRITIS IN PREGNANT WOMEN //International Bulletin of Medical Sciences and Clinical Research. – 2023. – Т. 3. – №. 8. – С. 22-25.
14. Shopulotova Z. A., Zubaydilloeva Z. K., Khudoyarova D. R. COMORBID EVENTS IN PREGNANT WOMEN WITH PYELONEPHRITIS AND PREVENTION OF THESE CONDITIONS //Бюллетень педагогов нового Узбекистана. – 2023. – Т. 1. – №. 9. – С. 35-38.
15. Shopulotova Z. A., Zubaydilloeva Z. K. THE VALUE OF ULTRASOUND DIAGNOSTICS IN PREGNANT WOMEN WITH CHRONIC PYELONEPHRITIS //Бюллетень студентов нового Узбекистана. – 2023. – Т. 1. – №. 9. – С. 19-22.
16. Shopulotova Z. A., Zubaydilloeva Z. K. PERINATAL CARDIOLOGY: PREGNANCY AND CONGENITAL HEART DEFECTS //Евразийский журнал академических исследований. – 2023. – Т. 3. – №. 9. – С. 55-59.
17. Shopulotova Z. A. et al. PHENOMENA OF COMORBIDITY IN PREGNANT WOMEN WITH PYELONEPHRITIS.
18. Shamatov I., Shopulotova Z. ADVANNAGES OF PALATE LASER THERAPY IN COMPLEX TREATMENT OF LARINGITIS //International Bulletin of Medical Sciences and Clinical Research. – 2023. – Т. 3. – №. 9. – С. 104-107.
19. Shamatov I. Y. et al. COMPREHENSIVE AUDIOLOGICAL STUDIES SENSORY NEURAL HEARING LOSS OF NOISE GENESIS //American Journal Of Social Sciences And Humanity Research. – 2023. – Т. 3. – №. 10. – С. 128-132.
20. Shamatov I. Y., Shayqulov H. S. H., Shopulotova Z. A. O’RTA QULOQNING ZAMBURUG’LI ZARARLANISHLARI //Евразийский журнал медицинских и естественных наук. – 2022. – Т. 2. – №. 6. – С. 425-427.
21. Yakubovich S. I., Abdumuminovna S. Z., Batiobekovna A. N. Analysis of the Effectiveness and Errors of Medical Care //Eurasian Journal of Research, Development and Innovation. – 2023. – Т. 20. – С. 1-4.

22. Yakubovich S. I. et al. Morphofunctional Changes of the Adrenals at Chronic Exposure to Magnesium Chlorate //Central Asian Journal of Medical and Natural Science. – 2022. – Т. 3. – №. 6. – С. 178-185.
23. Shernazarov Farrukh ORGANIZATION OF DIGITALIZED MEDICINE AND HEALTH ACADEMY AND ITS SIGNIFICANCE IN MEDICINE // SAI. 2023. №Special Issue 8. URL: <https://cyberleninka.ru/article/n/organization-of-digitalized-medicine-and-health-academy-and-its-significance-in-medicine> (дата обращения: 20.11.2023).