

Percutaneous Access to the Subarachnoid Space—An Approach to the Patient With Difficult Body Habitus

Ivan Chaitowitz, MD, Michael Letzing, MD, Evan Finkelstein, MD, and Robert Quencer, MD

University of Miami, Miami, FL, USA

INTRODUCTION

The needle technique for accessing the subarachnoid space (SAS) was first described by German physician Heinrich Quincke [1] in 1891. The popular Quincke spinal needle still bears his name.

The lumbar puncture is performed in the same manner today as it was in the late 1800s, except with minor modifications in equipment and technique. Our radiology department is regularly called upon to access the SAS for both diagnostic and therapeutic indications, to assess or treat such entities as follows:

1. Raised intracranial pressure
2. Suspected infection
3. Demyelinating disease
4. Disease progression or regression in neurooncology
5. Degenerative disc disease, for preoperative assessment with myelography (usually in those with a contraindication to magnetic resonance imaging or in those patients with extensive instrumented hardware causing significant artifact)
6. Intrathecal chemotherapy for patients with leukemia or lymphoma or metastatic disease

Despite advances in equipment and imaging, new challenges have arisen as the face of the world population changes. The CDC estimates that more than one-third of U.S. adults, and nearly, 17% of youth in America are obese [2]. According to the national scoliosis foundation, 2–3% of the U.S. population is affected by scoliosis. Generalized edema in sick and hospitalized patients, degenerative disk disease, spinal disorders such as ankylosing spondylitis, and a history of prior lumbar surgery can also make an ordinarily simple procedure more challenging and time-consuming.

CONVENTIONAL AND ALTERNATIVE TECHNIQUES

Lumbar puncture is typically performed at the bedside using surface landmarks. Conventional medical wisdom tells us that palpation of the iliac crests and spinous processes allow us to accurately determine an appropriate interspinous space for needle entry site. However, studies have demonstrated a high frequency of clinician error using this traditional methodology. Even in the patient with easily palpable surface landmarks, studies have shown that the technique is only accurate in identifying the correct lumbar interspace in 30% of patients [3,4]. In the obese patient, palpation of the spinous processes can become difficult, if not impossible. Furthermore, patients are typically only referred to the radiology department after one or more failed attempts at the bedside. This selects out a difficult patient population for the interventional neuroradiologist and necessitates a rapid, simple, and cost-effective method for gaining access.

Multiple alternative techniques have been described to address the problem of difficult body habitus. Ultrasound has been used to guide lumbar puncture and epidural anesthesia since the early 1970s [5]. In the typical technique, the ultrasound probe is used to identify the spinous processes. The needle entry site is then marked on the skin at the desired interspace prior to starting the procedure, which then proceeds in the standard “blind” fashion. The needle and its depth are not typically visualized under real-time ultrasound guidance. This can become problematic in the obese patient, where even small changes in angulation can lead to significant stray from the midline. The technique is also operator-dependent. An additional problem is that the transverse process may be mistaken for the spinous process, resulting in a lateralized puncture site.

Fluoroscopy with the patient in the prone position can also be used when palpation of surface landmarks fails.

Using the spinous processes as a guide, a midsagittal or parasagittal approach can be accurately selected. Unlike with ultrasound or the blind technique, a straight line to the thecal sac can be assured by aligning the hub of the needle with the tip (radiographically “looking down the barrel”). However, unless a C-arm is available, this technique also suffers from its inability to gauge the depth of the needle with respect to the subarachnoid space. When prior imaging is available, the distance from skin to thecal sac can be estimated; however, changes in patient positioning may make such estimates inaccurate. This technique also precludes the accurate measurement of opening pressure.

We describe a simple technique that allows the operator to ensure a midline entry site and to gauge the depth of the needle, without the need for a C-arm or changes in patient positioning. Our approach places the patient in the lateral decubitus positioning, which allows for the accurate assessment of opening pressure, greater patient comfort, and easier collection of CSF.

PROCEDURE IN DETAIL

As with any procedure, patient history, laboratory values, and prior imaging should be reviewed prior to beginning the procedure, in order to identify the rare patient with contraindications to lumbar puncture (including intracranial mass lesions with the evidence of raised intracranial pressure, bleeding diathesis, skin infection at the puncture site, and epidural abscess). After informed consent is obtained, the patient is placed in a lateral decubitus position on the fluoroscopic table. The fetal position is desirable, with the knees drawn closely to the chest, allowing for the optimal separation of the spinous processes. If palpable, the iliac crests can be used to estimate the craniocaudal level of the L4 spinous process. A radiopaque localizer grid is then placed over the patient’s back centering at the site where needle puncture is grossly anticipated (Figs. 1, 2). A frontal radiograph is then obtained and centered over the grid marker. A high kVp technique may be required in obese patients in order to adequately visualize the spinous processes (Fig. 3). The film is then reviewed by the radiologist in order to see which line of the grid corresponds to the patient’s spinous processes. A line is then drawn on the patient’s back using the grid as a guide, keeping in mind that some ink will be removed during the sterile preparation (Fig. 4). In the scoliotic patient, multiple points may be drawn, alternatively. The craniocaudal site of puncture is later determined under real-time fluoroscopic guidance.




Figure 1. A disposable radiopaque “Fast Find Grid”™ Webb Manufacturing is placed over the back with the patient in the lateral decubitus position, approximating the midline at the level of puncture.

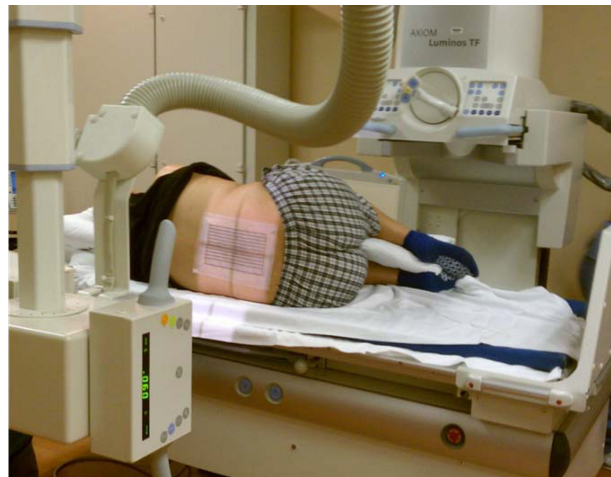


Figure 2. Prior to beginning the procedure a PA radiograph is obtained for localization of the spinous processes.

The procedure is then completed in typical fashion. We use the following technique at our institution: the patient is prepped and draped in the usual sterile manner. Under fluoroscopic guidance, the craniocaudal site of puncture is determined. A clamp or forceps can be used to avoid radiation exposure to the operator’s hand. The clamp is passed up and down the previously marked midline, in order to select the appropriate interspace. L3–L4 or L4–L5 is usually selected on the basis of how much degenerative change is present or how widely the spinous processes are separated. The skin and subcutaneous tissues are infiltrated with local anesthetic. An appropriate spinal needle is then introduced with the stylet in place. It has been suggested that a smaller gauge, “pencil-tipped”

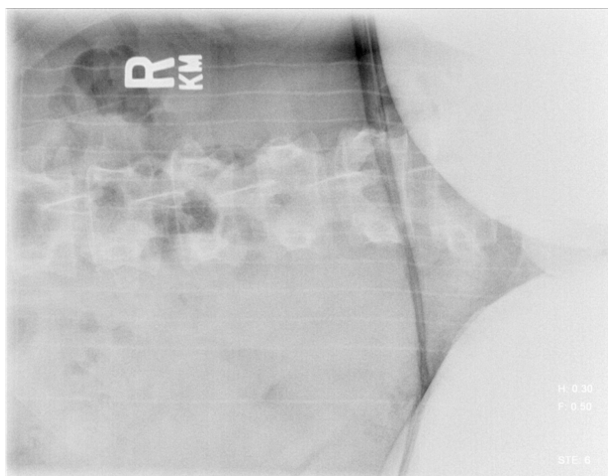


Figure 3. Spinous processes can clearly be seen overlying the radiopaque grid.

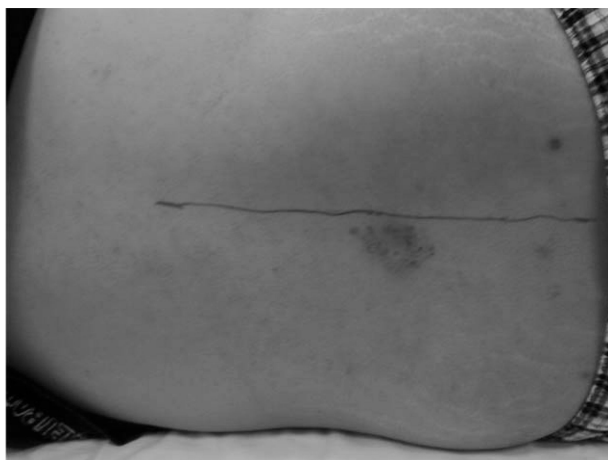


Figure 4. Line drawn over the true midline/spinous processes. Note the skin contusion from multiple prior “blind” attempts, significantly off the midline.

needle reduces the incidence of postprocedure headache [6], which is usually caused by CSF leakage that exceeds the rate of CSF production. Keeping the bevel of the needle oriented in the sagittal plane can theoretically result in the same effect, spreading the elastic fibers of the dural sac rather than cutting them (dural fibers run in the craniocaudal direction).

Careful attention should be paid to the orientation of the needle in order to maintain a midline position. Assuming proper patient positioning, the needle should be advanced parallel to the fluoroscopic table. This is performed under real-time fluoroscopic guidance to the level of the ligamentum flavum, approximately the spi-

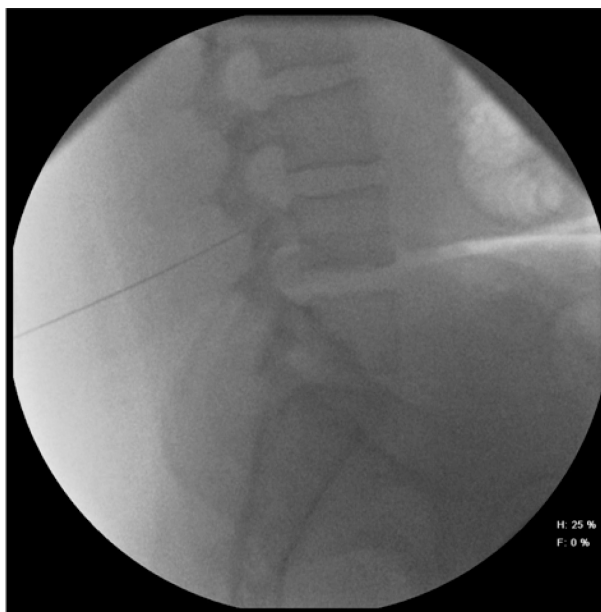


Fig 5. The needle is easily advanced to the spinolaminar line in the midline. Clear CSF spontaneously flowed in a single, atraumatic puncture.

nolaminar line (Fig. 5). The needle is then advanced at millimetric intervals by periodically removing the stylet until spontaneous return of (cerebrospinal fluid) CSF occurs. A palpable popping sensation can often be felt as the needle punctures the ligamentum flavum. If bone is encountered, the needle bevel can be used to steer the needle and/or deflect the tip off of bony structures (the raised marker on the needle hub indicates the side of the bevel). If poor flow is encountered after entering the thecal sac, the needle may be rotated by 90°, as a nerve root may occasionally obstruct the flow of CSF. Opening pressure can be recorded and fluid sent for laboratory analysis as the clinical history dictates. Medication or contrast for myelography can be injected if warranted. After the procedure is finished, the stylet is replaced and the needle is removed. Although no significant difference has been shown in the incidence of postprocedural headache between patients kept supine and those allowed to ambulate immediately [7], bed rest can be prescribed at the operator’s preference.

CONCLUSION

The use of a radiopaque localizer grid is suggested as a fast and easy way to access the subarachnoid space in patients with difficult body habitus (Fig. 6). The procedure allows the operator to accurately identify the interspinous space and gauge the depth of the needle in real

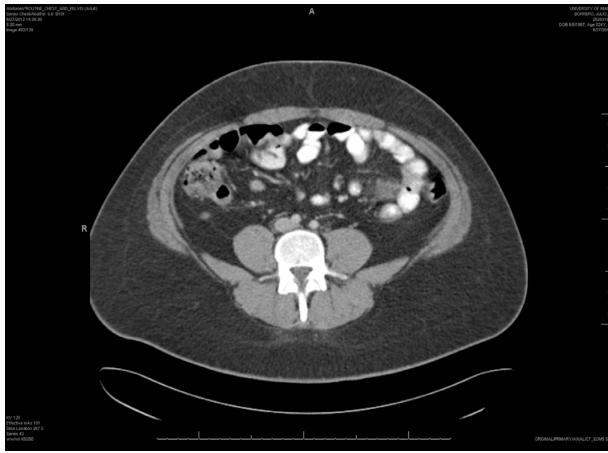

Fig 6. Difficult body habitus exhibited by increased diameter from skin to subarachnoid space on CT of obese patient.

time. It takes only one or two additional minutes prior to beginning the procedure, and we have found significantly decreased procedure time overall. The potential for decreased fluoroscopic time leads to decreased radiation dose to both the patient and the operator. In theory, a faster procedure with less attempts at accessing the

SAS should lead to a decreased rate of complication. Further prospective study could evaluate these end results in patients undergoing lumbar puncture in the following circumstances: AP approach without grid, lateral approach without grid, and the lateral approach with a grid.

References

1. Quincke H. Die Lumbalpunktion des Hydrocephalus. *Berliner klinische Wochenschrift* 1891;28:929–33. 965–8.
2. Ogden CL, Carroll MD, Kit BK, Flegal KM. Prevalence of Obesity in the United States, 2009–2010. Available at <http://www.cdc.gov/nchs/data/databriefs/db82.pdf>
3. Broadbent CR, Maxwell WB, Ferrie R, Wilson DJ, Gawne-Cain M, Russell R. Ability of anaesthetists to identify a marked lumbar interspace. *Anaesthesia* 2000;55(11):1122–6.
4. Furness G. An evaluation of ultrasound imaging for identification of lumbar intervertebral level. *Anesthesia* 2002;57:277–80.
5. Bogin IN, Stulin ID. [Application of the method of 2-dimensional echospondylography for determining landmarks in lumbar punctures]. *Zh Nevropatol Psikhiatr Im S S Korsakova* 1971;71(12):1810–1.
6. Strupp M, Schueler O, Straube A, Von Stuckrad-Barre S, Brandt T. “Atraumatic” Sprotte needle reduces the incidence of post-lumbar puncture headaches. *Neurology* 2001;57:2310–2.
7. Spriggs DA, Burn DJ, French J, et al. Is bed rest useful after diagnostic lumbar puncture? *Postgrad Med J* 1992;68:581–3.