

Extensive bilateral vertebral artery remodeling following treatment of dissection using pipeline embolic device

Bartley Mitchell, MD PhD¹, Eric Momin, MD¹, Liang-Der Jou, PhD², Hashem Shaltoni, MD³, Hesham Morsi, MD³, and Michel Mawad, MD^{2,3}

¹Department of Neurosurgery, Baylor College of Medicine, 1709 Dryden suite 750, Houston, TX 77030, USA

²Department of Radiology, Baylor College of Medicine, One Baylor Plaza, Houston, TX 77030, USA

³Neurovascular Center, St. Luke's Episcopal Hospital, Houston, TX 77030, USA

Abstract

Background—Cerebral artery dissection remains a significant cause of stroke, and the mainstay of treatment has been medical management with anticoagulation, although flow-diverting stents have been used in some cases of arterial dissection resistant to medical management.

Methods—We present a case report of bilateral vertebral artery stenting using pipeline embolic device flow-diverting stents, after failed medical management of the dissection.

Results—This case demonstrated substantial subsequent vertebral arterial remodeling and good clinical outcome with maintenance of posterior circulation. The patient did not suffer any further strokes or posterior circulation symptoms following vertebral artery remodeling.

Conclusion—In cases where traditional management of arterial dissection has not been efficacious, flow-diverting stents may be useful in treating dissections of the posterior cerebral circulation, even with bilateral involvement.

Keywords

Pipeline embolic device; flow diversion; stent; cranial arterial dissection

Introduction

Traditionally, the treatment for dissection of cerebral blood vessels involves anticoagulation and clinical examination. Although medical management remains the mainstay of treatment in cases of arterial dissection, there are some instances of failure of anticoagulation therapy, and patients may progress or become symptomatic with transient ischemic attacks (TIAs) or even stroke. Recently, in some cases of carotid or vertebral artery dissecting aneurysms, flow-diversion stenting has been employed successfully with long-term reconstruction of the affected vessel [1,2]. We present a case in which a patient presented initially with a dissected vertebral artery, was placed on anticoagulation, failed this therapy (experiencing TIAs and stroke), and had evidence of bilateral vertebral artery dysmorphism associated with arterial dissection. This patient therefore underwent placement of bilateral pipeline embolic device (PED) flow-diverter stents (Covidien/EV3; Ply-

mouth, MN) in both vertebral arteries. Following stenting, we showed evidence of extensive arterial flow remodeling from the fusiform dissecting aneurysms of the vertebral arteries, and clinically remained in good health, with no new neurologic deficits. To our knowledge, this is the first case of bilateral vertebral artery stenting with pipeline flow-diverter stents with evidence of considerable arterial remodeling and maintenance of normal blood flow.

Case presentation

A 47-year-old man with a history of hypertension, otherwise in good health, who suffered a right-sided vertebral artery dissection with resultant left arm and leg weakness. He was initially treated with medical management, and was anticoagulated with warfarin. One year after his initial stroke, he began having dizziness, more left-sided weakness, headache, neck pain, and blurry vision.

Table 1. Summary of dissecting aneurysm sizes, PED sizes, as well as pre- and post-treatment arterial diameters at proximal and distal aspects of the vertebral arteries.

Location	Pre-PED	Post-PED	PED sizes (mm)
Aneurysm (right)	11.4 × 35 mm	4.5 mm	5 × 35 mm, 5 × 35 mm, 5 × 20 mm
Proximal	3.4 mm	4.5 mm	
Distal	2.8 mm	3.7 mm	
Aneurysm (Left)	7.2 × 25 mm	4.8 mm	4.5 × 30 mm, 4.5 × 20 mm, 4.5 × 18 mm
Proximal	4.0 mm	4.3 mm	
Distal	3.1 mm	4.2 mm	

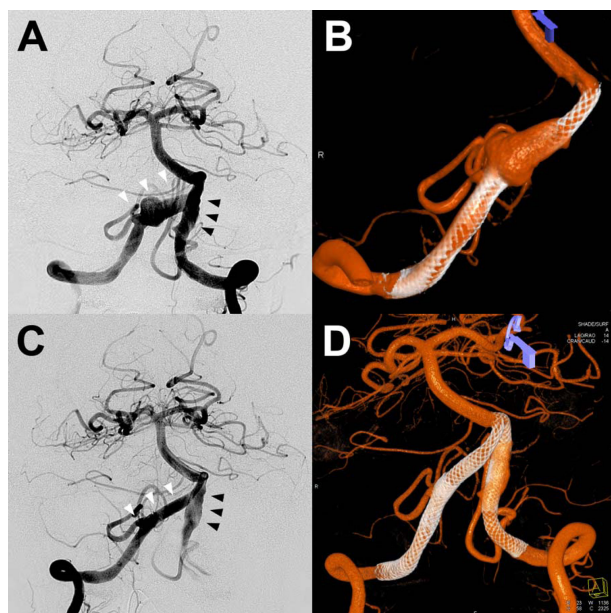


Figure 1. (A) Initial left vertebral arteriogram injection showing bilateral fusiform aneurysms of the vertebral arteries, indicated by arrowheads (white on right, black on left). (B) Three-dimensional reconstruction of the right vertebral artery immediately following placement of three pipeline stents across the fusiform aneurysm area. (C) Arteriogram of the vertebral system 4 days after placement of the right-sided PED, showing initial arterial flow remodeling on the right (white arrowheads), with continued fusiform dilation of the left side (black arrowheads). (D) Three-dimensional reconstruction showing the vertebral arteries after placement of three PEDs across the left fusiform aneurysm.

Angiogram demonstrated a new left-sided vertebral artery dissection (7.2 × 25 mm), with worsening right-sided vertebral artery dissection measuring 11.4 × 35 mm (Figure 1).

Given this patient's failure of anticoagulation therapy and the extent of dissection with fusiform dilation of both vertebral arteries with worsening of his previous condition, the decision was made to utilize endovascular therapy for reconstruction of the vertebral arteries. He underwent preprocedure platelet inhibition using clopidogrel and aspirin, and then during the procedure was

anticoagulated with heparin (100 units/kg IV) to achieve an activated clotting time of 250–300 s. Access to the vertebral arteries was achieved using a 6F Chaperon guide catheter (Microvention; Tustin, CA), followed by a Excelsior XT-27 delivery catheter (Stryker; Kalamazoo, MI) positioned into place over a Terumo 0.018-in guidewire (Terumo; Somerset, NJ). He then received placement of PEDs (Covidien/EV3, Plymouth, MN) within the vertebral arteries, with three PEDs telescopically placed first in the right vertebral artery in a distal-to-proximal fashion and similarly had three PEDs placed in the left vertebral artery later in a separate treatment session (4 days following stenting of the right vertebral artery). Table 1 summarizes the arterial and aneurysmal sizes as well as the sizes of PEDs placed in each vertebral artery.

The patient tolerated these procedures well, with no complications, and was maintained on clopidogrel (75 mg daily) and aspirin (325 mg daily). At his 8-month followup, angiogram demonstrated extensive remodeling of the bilateral vertebral arteries, with maintenance of patency in both vertebral arteries (Figure 2). He had no further recurrence of his previous stroke or transient ischemic attack symptoms while on dual antiplatelet therapy.

Discussion

Cranial artery dissection represents a potential source for stroke, especially in younger adults [3,4], and oral anticoagulation or antiplatelet therapy have been the mainstays of treatment to prevent further strokes and promote recanalization. Although there is some debate currently regarding the efficacy of oral anticoagulation versus antiplatelet therapy [5,6], there are nevertheless incidents of further stroke and failure of the dissected vessels to recanalize properly. Anticoagulation therapy has been shown to be superior to antiplatelet therapy in cases of atrial fibrillation [7]; however, one should be cautious in extrapolating this data to strokes caused by cervical artery dissection, as the populations tend to be different in both age and mechanism. The issue of anticoagulation versus aspirin therapy has been specifically evaluated in cases of arterial origin strokes [8], with no definitive advantage of one over the other overall.

Strokes in the vertebral artery or basilar artery distribution can be particularly devastating, and in this case in particular, both vertebral arteries were affected simultaneously, which presents an even more ominous danger. Use of the PED has been previously described in the vertebral artery in a case of dissection [9] or with fusiform aneurysms [10]; however, this is the first instance of bilateral vertebral artery stenting using the PED, with prevention of further stroke/TIA symptoms. This case illustrates both the need for imaging followup after vertebral artery dissection as well as the understanding that in the face of failed medical therapy, endovascular therapy represents a viable alternative treatment option. In this case, there was extensive arterial remodeling demonstrated, along with arterial patency and no evidence of subsequent strokes.

There are several other factors that are unaccounted for, however, including the degree of lumen narrowing caused by the dissection, as well as the presence of an intraluminal clot, which could have significant effects on the decision to attempt endovascular therapy in these cases. Passing a stent across an already narrowed and damaged artery could be potentially devastating, not to

mention technically difficult or impossible. Furthermore, the act of passing any endovascular device across a dissected region of artery could dislodge an adherent clot, sending it downstream precipitating an infarct. Delayed occlusion of the stented regions is not simply a theoretical concern either, and certainly represented another potential catastrophic pitfall in this case involving bilateral vertebral arteries. The stents chosen were slightly oversized in comparison with the diameters of the parent vessels (Table 1), with the goal of maintaining adequate stent apposition to the vessel wall during placement of the stents in a distal-to-proximal manner and allowing for eventual vessel remodeling with maintenance of sufficient flow through the reconstructed areas. Care was taken to place the stents as distally as possible within each vertebral artery, while not overlapping the stents at the vertebrobasilar junction so that there would be no distortion from stent-on-stent contact.

Considering the risks involved with placing any endovascular device in the event of an arterial dissection, one must carefully weight the risks and benefits. In cases such as this one, with continued evidence of cerebral vascular compromise along with imaging evidence of failure of medical therapy, it was felt that the risk was outweighed by the potential benefits, and the patient did well afterwards, with no further evidence of stroke. This patient remained on dual-antiplatelet therapy after stent placement, which theoretically may have contributed to the positive outcome as well.

Conclusions

There is very little evidence currently for the use of flow-diversion stenting for vertebral artery dissection, and further investigation is needed to determine whether this therapy will provide a consistently stable remodeling of arterial architecture in cases of dissection.

References

1. de Barros Faria M, Castro RN, Lundquist J, et al. 2011;The role of the pipeline embolization device for the treatment of dissecting intracranial aneurysms. *AJNR American Journal of Neuroradiology* 2011 32:2192–5.
2. Yeung TW, Lai V, Lau HY, Poon WL, Tan CB, Wong YC. 2012;Long-term outcome of endovascular reconstruction with the Pipeline embolization device in the management of unruptured dissecting aneurysms of the intracranial vertebral artery. *Journal of Neurosurgery* 2012 116:882–7.
3. Leys D, Bandu L, Henon H, et al. 2002;Clinical outcome in 287 consecutive young adults (15 to 45 years) with ischemic stroke. *Neurology* 2002 59:26–33.
4. Nedeltchev K, der Maur TA, Georgiadis D, et al. 2005;Ischaemic stroke in young adults: predictors of outcome and recurrence. *Journal of Neurology, Neurosurgery, and Psychiatry* 2005 76:191–5.

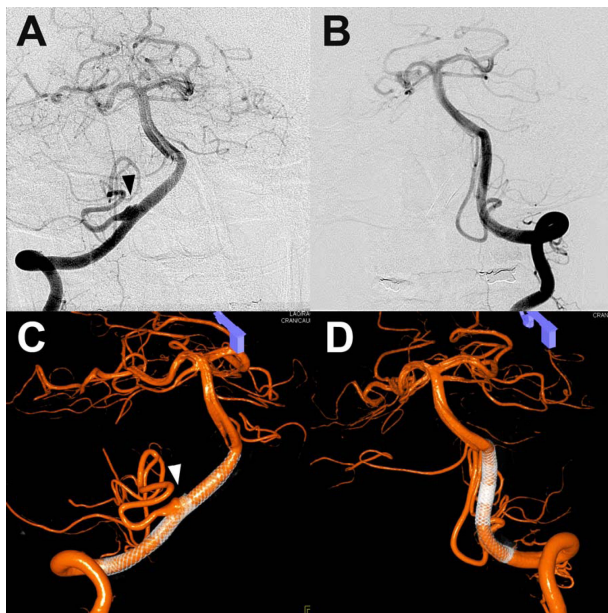


Figure 2. Right (a) and left (B) vertebral artery arteriograms at the 1-year followup, showing extensive arterial flow remodeling. Three-dimensional reconstructions showing arterial blood flow and the PEDs on the right (C) and left (D) vertebral arteries. There is some minor residual arterial dilation of the right vertebral artery at the PICA origin (C, arrowhead), which will require further monitoring.

5. Arauz A, Ruiz A, Pacheco G, et al. 2013; Aspirin versus anticoagulation in intra- and extracranial vertebral artery dissection. *European Journal of Neurology : The official journal of the European Federation of Neurological Societies* 2013 20:167–72.
6. Engelter ST, Brandt T, DeBette S, et al. 2007; Antiplatelets versus anticoagulation in cervical artery dissection. *Stroke; A Journal of Cerebral Circulation* 2007 38:2605–11.
7. Hart RG, Benavente O, McBride R, Pearce LA. 1999; Antithrombotic therapy to prevent stroke in patients with atrial fibrillation: a meta-analysis. *Annals of Internal Medicine* 1999 131:492–501.
8. Mohr JP, Thompson JL, Lazar RM, et al. 2001; A comparison of warfarin and aspirin for the prevention of recurrent ischemic stroke. *The New England Journal of Medicine* 2001 345:1444–51.
9. Ducruet AF, Crowley RW, Albuquerque FC, McDougall CG. 2013; Reconstructive endovascular treatment of a ruptured vertebral artery dissecting aneurysm using the Pipeline embolization device. *Journal of Neurointerventional Surgery* 2013 5:e20.
10. Fiorella D, Woo HH, Albuquerque FC, Nelson PK. 2008; Definitive reconstruction of circumferential, fusiform intracranial aneurysms with the pipeline embolization device. *Neurosurgery* 2008 62:1115–20.discussion 20-1