

Utility of diagnostic cerebral angiogram in a patient with fluctuating aphasia and presumed left atretic transverse sinus on noninvasive imaging modalities

Haitham Dababneh, MD^{*†}, Mohammed Hussain, MD[†], Mohammad Moussavi, MD, and Jawad F Kirmani, MD

Stroke & Neurovascular Center at JFK Neuroscience Institute, Edison, NJ 08818, USA.

[†]Contributed equally to this work.

Drs. Dababneh and Hussain, drafted and edited the manuscript.

Dr. Moussavi edited the article.

Dr. Kirmani has edited and revised the article.

Case summary

A 46-year-old female presented with headache and fluctuating aphasia. CT head/angiogram and magnetic resonance image/venogram were nonconfirmatory for vascular pathology, although suggestive of left atretic transverse sinus. Diagnostic angiogram showed left temporal venous congestion with delayed drainage of vein of Labbe into the left transverse sinus. This territory of venous drainage overlaps with the temporal branches of middle cerebral artery; therefore, occlusion of the temporal venous branches causes infarction in the Wernicke's area causing aphasia [1]. Hypoplasia or atresia of cerebral sinuses may lead to inconclusive results on MRV or CT and hence the venous phase of cerebral angiography would serve to provide a higher clinical yield in such cases [2].

References

1. Jones BV. 2003;Case 62: lobar hemorrhage from thrombosis of the vein of Labbé. *Radiology* Sep;2003 228:693.
2. Saposnik G, Barinagarrementeria F, Brown RD Jr, Bushnell CD, Cucchiara B, Cushman M, DeVeber G, Ferro JM. 2011;Diagnosis and management of cerebral venous thrombosis. *Stroke* 42:1158–92.

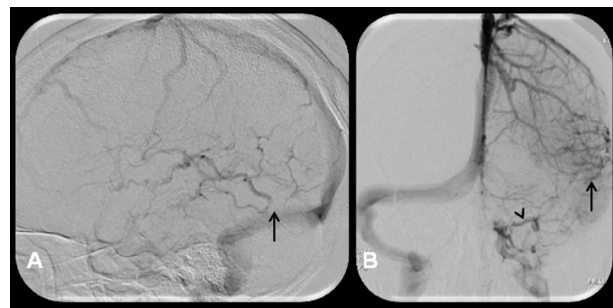


Figure 1. (A) Early venous phase showing most of the superficial veins draining into superior sagittal sinus, there is an evidence of retrograde-flow of sphenoparietal and superior petrosal into cavernous sinus instead of left transverse sinus; and inferior petrosal directly into sigmoid sinus. (B) Late venous phase showing evidence of delayed filling in vein of Labbe with occlusion at the junction of left transverse sinus. (C) Absence of left transverse sinus.

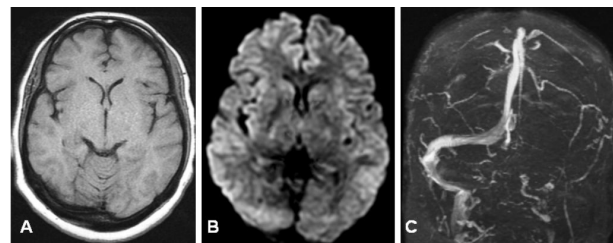


Figure 2. Normal T1 (a) and diffusion weighed (B) MRI with evidence of absent left transverse sinus (C) on MRV.

Published November, 2014.

All Rights Reserved by JVIN. Unauthorized reproduction of this article is prohibited

*Correspondence to: Haitham Dababneh, Stroke & Neurovascular Center at JFK Neuroscience Institute, Edison, NJ 08818, USA, Haitham82@gmail.com