

Intravenous thrombolysis in a patient using factor Xa inhibitor

Daniel Korya, MD[†], Haitham Dababneh, MD[†], Mohammad Moussavi, MD[†], Spozhmy Panezai, MD, Emad Noor, MD, and Jawad F Kirmani, MD

Stroke & Neurovascular Center at JFK Neuroscience Institute, Edison, NJ 08818, USA

**Contributed equally to this work.*

Abstract

Until recently, only warfarin was approved for the prevention of stroke in patients with AF. Patients on warfarin with ischemic stroke were considered candidates for IV tPA as long as their PT/INR was not prolonged. Now, there are several new agents approved for stroke prevention in patients with non-valvular AF. The newer agents include direct thrombin inhibitors, like dabigatran, and factor Xa inhibitors, like rivaroxaban and apixaban. The coagulation profile of patients on direct thrombin inhibitors is more predictable than that of patients on factor Xa inhibitors, and the usage of IV tPA in patients on dabigatran has been previously reported. To our knowledge, there are no prior reports of IV tPA in a patient on a factor Xa inhibitor. We report a case of a 71-year-old man on rivaroxaban who improved with IV tPA after presenting with acute onset of aphasia and right-sided weakness.

AF	Atrial fibrillation
IV tPA	Intravenous tissue plasminogen activator
INR	International normalized ratio
PTT	Partial thromboplastin time
NIH	National Institute of Health
PT	Prothrombin time
CT	Computed tomography
MCA	Middle cerebral artery
MRI	Magnetic resonance imaging

Background

Warfarin has been used for the primary prevention of ischemic stroke in patients with atrial fibrillation since the early 1990s [1]. For nearly 30 years, warfarin was the gold standard and only oral treatment available. Recently, the ROCKET-AF trial demonstrated the non-inferiority of rivaroxaban, a factor Xa inhibitor, compared with warfarin for the prevention of stroke and systemic embolism [2]. When compared with warfarin, rivaroxaban was able to reduce the rate of stroke or systemic embolism to 2.12% per year [2]. The treatment for patients who suffer an acute ischemic stroke while taking rivaroxaban is not well established.

The only currently approved treatment for acute stroke with a class I recommendation and level A evidence is IV tPA [3]. Patients with ischemic stroke while taking warfarin may be treated with IV tPA as long as their INR and PTT are not elevated [4]. However, INR is not an effective way of determining the level of anticoagulation in patients taking factor Xa inhibitors [5]. Tests that measure the level of factor Xa inhibition are commercially available but are not widely used [5]. Therefore, the safety of thrombolysis in patients taking factor Xa inhibitors is yet to be determined.

Published September, 2014.

All Rights Reserved by JVIN. Unauthorized reproduction of this article is prohibited

[†]Correspondence to: Dr. Haitham Dababneh, Stroke & Neurovascular Center at JFK Neuroscience Institute, Edison, NJ 08818, USA, Haitham82@gmail.com

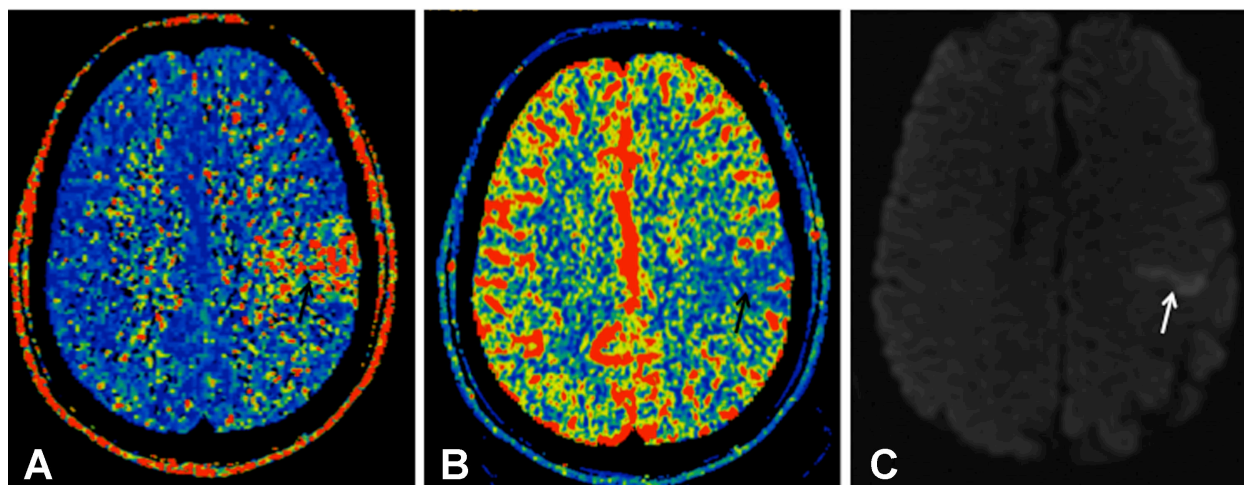


Figure 1.

Case Report

A 71-year-old man with a past medical history of atrial fibrillation, hypertension, and dyslipidemia reported to the emergency department with complaints of mild right-sided weakness, right facial droop, and moderate-to-severe aphasia. His initial NIH stroke scale was determined to be 7. Serum laboratory tests demonstrated normal complete blood counts and metabolic panels with an initial PT of 15.1 s (normal 12.5–14.8 s), INR of 1.2, and PTT of 31.6 s (normal 24.4–36.5 s). A CT scan of the head did not show any hemorrhage. CT perfusion was subsequently performed and showed prolongation of the mean transit time (Figure 1A) in the left MCA territory, with small area of decrease in cerebral blood volume (Figure 1B). CT angiogram showed a cutoff in the distal branch of the left MCA black arrow (Figure 2A).

The patient was treated with 0.9 mg/kg of IV tPA with an initial 10% bolus per protocol. Prior to the infusion, the patient was aphasic and the family was unavailable. After the completion of the infusion, contact with the family was achieved. The family was questioned about home medications, and it was discovered that he has been taking rivaroxaban for the past several months for atrial fibrillation and was compliant, last dose received 4 h prior to presentation.

MRI of the brain was performed and demonstrated an area of restricted diffusion in the left posterior frontal lobe (Figure 1C). On the second day of hospitalization, the patient was able to name all objects on the NIH stroke scale and became more fluent in speech. He denied any sensory deficits but continued to have a

slight facial droop with some mild dysarthria and right-sided weakness. A 24-h CT scan of the head was performed and showed a small linear area of decreased attenuation in the left frontal parietal lobe and no evidence of hemorrhage was noted. After managing the patient's blood pressure and adjusting other risk factors, the patient in good condition was discharged home. Next day, CT angiogram showed an evidence of recanalization of previously occluded distal branch of the left MCA black arrow (Figure 2B).

Discussion

Patients with atrial fibrillation who are receiving factor Xa inhibitors create a unique problem for the management of acute stroke. There are currently no published studies to base recommendations on for the use of tPA in patients taking factor Xa inhibitors. Recently, recommendations about the use of tPA in patients receiving dabigatran, a direct thrombin inhibitor, were published in *Stroke* [6]. However, the same study also made a point to say that these recommendations cannot be made to encompass the factor Xa inhibitors. Several other articles have been published describing the incidence of complications and recommended discontinuing direct thrombin inhibitors preprocedural [7,8]. To our knowledge, there are no case reports describing the inadvertent use of tPA in a patient taking rivaroxaban.

The patient in the case described did not have any complications from the concomitant use of IV tPA and rivaroxaban. However, it is difficult to suggest a reason or make recommendations based on this case alone. The patient's coagulation profile was essentially normal, but

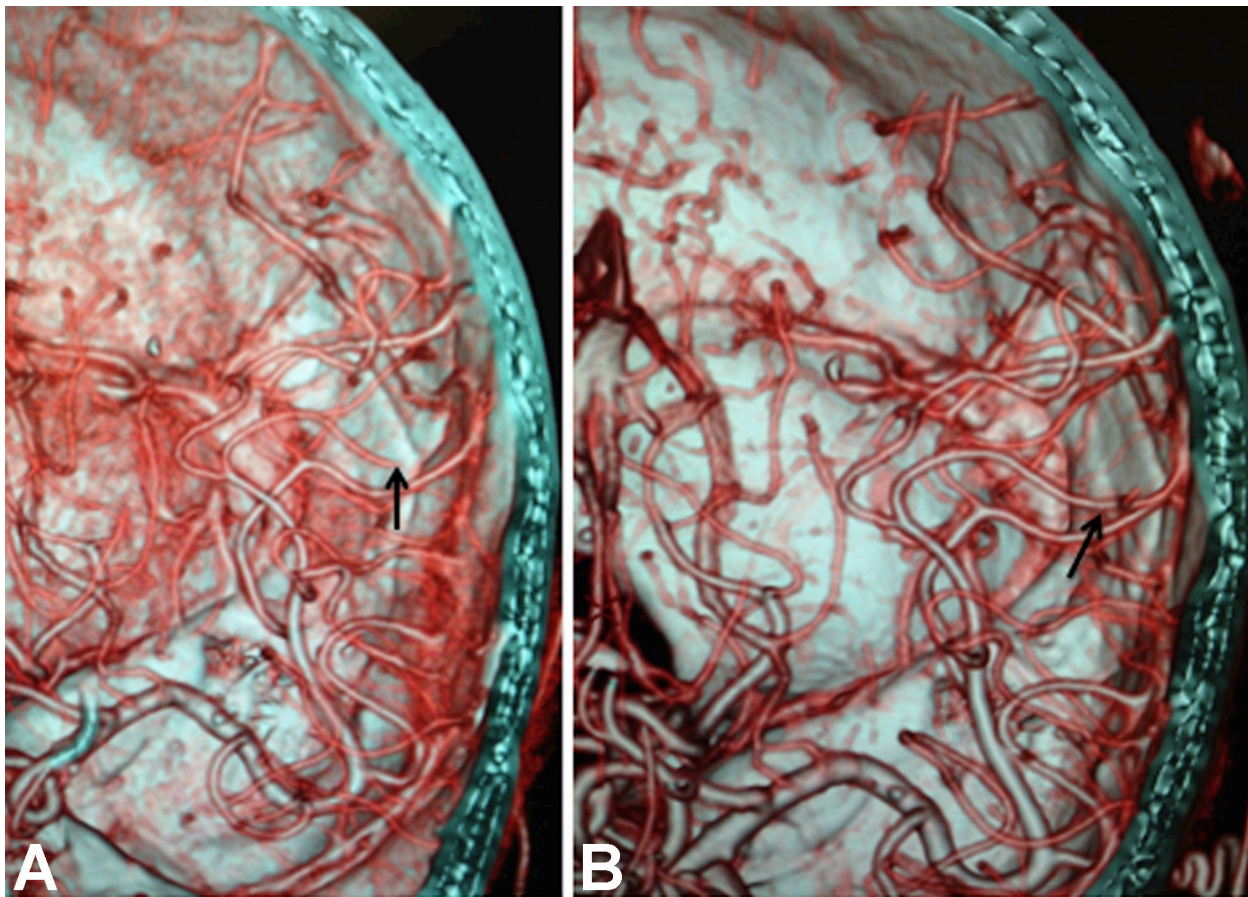


Figure 2.

Table 1.

Case No.	Age (years), Sex	Admission H & H	Admission mFisher	Initial GCS	TCD baseline	TCD at Day 5	TCD at Day 10	Discharge mRS	mRS at 90 days
1	38, F	3	3	14	51	77	102	0	0
2	53, F	4	4	7	67	53	84	0	0

H & H: Hess and Hunt, GCS: Glasgow coma scale, TCD: transcranial Doppler, mRS: modified Rankin scale, mFisher: modified Fisher.

this is not easily correlated with drug level or therapeutic benefit of rivaroxaban [9]. A small number of prior case reports have suggested that the use of IV tPA for acute stroke in patients taking dabigatran may be safe in the setting of normal PT/INR and PTT, but the same recommendation cannot be made for patient's taking factor Xa inhibitors since their effect on coagulation testing is not as predictable [6]. The patient in the case described was able to receive IV tPA safely despite being on a factor Xa inhibitor, but the safety and efficacy in other patients needs to be further evaluated.

References

1. Besson G, Bogousslavsky J. Secondary prevention with anticoagulants and aspirin in patients with non-valvular atrial fibrillation having suffered a transient ischemic attack or a regressive vascular accident. 1991;*Rev Med Suisse Romande* 111:49–55. European atrial fibrillation trial (EAFT).
2. Patel MR, Mahaffey KW, Califf RM, et al. 2011;Rivaroxaban versus warfarin in nonvalvular atrial fibrillation. *N Engl J Med* 365:883–91. and the ROCKET AF Steering Committee for the ROCKET AF Investigators.
3. Adams HP, del Zoppo G, Alberts MJ, et al. 2007;American Heart Association; American Stroke Association Stroke Council; Clinical Cardiology Council; Cardiovascular Radiology and Intervention Council; Atherosclerotic Peripheral Vascular Disease and Quality of Care Outcomes in Research Interdisciplinary Working Groups. Guidelines for the early management of adults with ischemic stroke: a guideline from the American Heart Association/American Stroke Association Stroke Council, Clinical Cardiology Council, Cardiovascular Radiology and Intervention Council, and the Atheroscler-

- otic Peripheral Vascular Disease and Quality of Care Outcomes in Research Interdisciplinary Working Groups: the American Academy of Neurology affirms the value of this guideline as an educational tool for neurologists. *Stroke* 38:1655–711.
4. The National Institute of Neurological Disorders and Stroke rt-PA Stroke Study Group. 1995;Tissue plasminogen activator for acute ischemic stroke. *NEJM* 333:1581–2.
 5. Barrett YC, Wang Z, Shenker A, et al. 2010;Clinical laboratory measurement of direct factor Xa inhibitors: Anti-Xa assay is preferable to prothrombin time assay. *Thrombosis and Haemostasis* 104:1083–289.
 6. Alberts MJ, Bernstein RA, Garcia DA, et al. 2012;Using dabigatran in patients with stroke, a clinicians guide to therapy. *Stroke* 43:271–9.
 7. Watanabe M, Qureshi AI, Siddiqui FM. 2011;Periprocedural management of patients on dabigatran etexilate treatment. *AJNR* 32:E166.
 8. Watanabe M, Siddiqui FM.; Qureshi, AI. 2012;Incidence and management of ischemic stroke and intracerebral hemorrhage in patients on dabigatran etexilate treatment. *Neurocrit Care* 16:203–9.
 9. Baglin T, Keeling D, Kitchen S. 2012;Effects on routine coagulation screens and assessment of anticoagulant intensity in patients taking oral dabigatran or rivaroxaban: Guidance from the British Committee for Standards in Haematology. *British Journal of Haematology* 159:427–29.