

Duplex ultrasound assisted endovascular revascularization of chronic internal carotid artery occlusion: technical note

Nassir Rostambeigi, MD MPH¹, Rakesh Khatri, MD¹, Ameer E. Hassan, DO¹, and Adnan I. Qureshi, MD^{1,*}

¹ Zeenat Qureshi Stroke Research Center, University of Minnesota, Minneapolis, MN 55455 USA

Abstract

Carotid artery occlusion is a major risk factor for ischemic stroke. Endovascular treatment of carotid artery occlusion in high-risk patients offers a therapeutic option to reduce subsequent ischemic events. The technical success and avoidance of complications of the endovascular recanalization of occluded carotid artery is contingent on proper visualization of the vessel wall. To highlight the value of duplex ultrasound guidance, we herein described the procedural details of the use of ultrasound guidance for characterization and visualization of the endovascular devices as well as the vessel wall during endovascular revascularization. Patient was a 54-year-old woman, diagnosed with carotid occlusion with recurrent symptomatic episodes. Endovascular revascularization was successfully performed by ultrasound assistance upon traversing the occluded segment and accurate deployment of stent. The patient was followed for 3 months and has not experienced any ischemic symptoms. Duplex ultrasound guidance helps preventing the vessel wall injury and dissection during revascularization of chronically occluded carotid artery. Ultrasound guidance may improve the outcomes of the endovascular procedures in high-risk patients with carotid occlusion.

Keywords

carotid occlusion; duplex ultrasound guidance; dissection

Introduction

Internal carotid artery (ICA) occlusion has an adjusted incidence rate of 6 per 100,000 persons and may account for 15,000 to 20,000 ischemic events in the United States [1]. The annual risk of non-fatal stroke was reported to be as high as 3% to 10% in adults older than 60 years with carotid occlusion [2]. Recurrent ischemic events are seen in 25% of patients with symptomatic carotid occlusion [3–5]. Percutaneous transarterial endovascular interventions are increasingly used for the treatment of carotid artery occlusion [6] with revascularization success rates of greater than 70% [7]. Nonetheless, a 6% complication rate associated with the endovascular approach has been reported including dissection and pseudoaneurysm formation [8] due to lack of visualization and inability to distinguish between lumen and arterial wall in occlusive lesion. Successful traversing without incurring additional arterial injury remains technically challenging and yet critically important for successful revascularization.

We herein report the initial experience with the use of external Doppler ultrasound imaging for the endovascular treatment of the carotid artery occlusion.

Methods

Medical history

The patient was a 54-year-old woman, who presented with transient but recurrent episodes of right side weakness, aphasia, right limb shaking, and amaurosis fugax in left eye. The frequency of these episodes was almost twice a week for 4 weeks. Her past medical history was significant for type II diabetes mellitus, hypertension, and hypertrophic cardiomyopathy with implanted defibrillator. She had previously undergone a right ICA angioplasty and stent placement. A cerebral angiogram demonstrated complete occlusion of the cervical section of the left ICA with collateral filling as described later in this paper. Computerized tomography (CT) perfusion

Published December, 2013.

All Rights Reserved by JVIN. Unauthorized reproduction of this article is prohibited

*Correspondence to: AI Qureshi, Tel.: +1-612-626-8221, Fax: +1-612-625-7950, aqureshi@hotmail.com

images acquired before and after intravascular (IV) acetazolamide (1 g) demonstrated no vasodilatory reserve in the left hemisphere. Due to significant impairment in quality of life and high risk of major stroke and death, we decided to attempt endovascular recanalization of the left ICA occlusion. Patient was on aspirin (325 mg daily) and clopidogrel (75 mg daily) for the last 5 months for prevention of ischemic events.

The patient was not considered a candidate for superficial temporal to middle cerebral artery bypass. This was decided on the basis of findings from the multi-center randomized trial comparing medical therapy alone with extracranial-intracranial (EC-IC) bypass surgery added to best medical therapy [9,10] and Carotid Occlusion Surgery Study (COSS) trial that was stopped prematurely as a result of lack of superiority of the EC-IC bypass procedure compared to the best medical therapy [11].

Upon explanation of the purpose of the study and the risks and benefits of the procedure, an informed consent was obtained from the patient.

Ultrasound guidance

For traversing the lesion, the ultrasound probe was kept in place in the neck near the angle of jaw. It was manually positioned to allow adequate visualization of both circumferential and longitudinal views. A 9-3 MHz broadband linear transducer (iU22®, Philips, USA) was used in this procedure. First, the magnification was turned off and the bifurcation was located to distinguish the internal and external carotid artery. A transverse sweep began at the base of the neck in the low common carotid and traveled up through the bulb into the internal and external bifurcation. This took ~5 s. The transverse scan was done with the field of view set at a depth of 4 cm and probe frequency at 9 MHz. To locate the peak velocity, a 2-mm Doppler sample gate was placed at the center of the distal common carotid artery. The ICA image was then centered on the initial 1 cm segment distal to the flow divider and magnification was turned on. Simultaneous display of the near- and far-wall interfaces of the artery ensured the probe was placed exactly over the center of the vessel at its horizontal plane. Images were captured at several critical times of the procedure as close to 45° as possible maintaining optimal display of wall interfaces.

Revascularization procedure

The procedure was performed via the percutaneous transfemoral route under conscious sedation. Cerebral angiogram demonstrated a left ICA occlusion immedi-

ately distal to bifurcation of the common carotid artery. Left external carotid artery and its branches were patent. Intracranial ICA was reconstituted in retrograde manner from external carotid artery via ophthalmic artery and from contralateral ICA via a patent anterior communicating artery. There was also occlusion of left vertebral artery at its origin with distal reconstitution from deep cervical and ascending cervical arteries. In addition, right ICA stent was patent without any significant in-stent stenosis.

After placement of 5 French introducer sheath in the common femoral artery, heparin bolus was administered intravenously to increase the ACT > 200 s. A 5 French Simmons 2 catheter (Cordis Europa®, Roden, Netherlands) was used for performing diagnostic angiogram. The diagnostic catheter was exchanged for a 6 French Cook shuttle (Cook Medical®, Indianapolis, IN) using an exchange length guidewire (Amplatz superstiff 0.038 inch). The Cook shuttle was placed in the distal left common carotid artery proximal to the occlusion. We placed a 125 cm VERT catheter (Beacon® Tip Torcon NB® Advantage Catheters, IN) through 6 French cook shuttle and advanced it to the origin of occluded left ICA.

We unsuccessfully attempted to traverse the occluded left ICA with All-star wire 0.014 microwire (ACS, Temecula, CA) and then a 0.016 inches microwire (Terumo GT, Somerset, NJ). We subsequently were able to traverse the occlusion using a 0.035 inches exchange length guidewire (Boston Scientific, Natick, MA). We manipulated the guidewire under ultrasound guidance ensuring that the distal end of the guidewire remained within the circumferential confines of the cross section of the artery (Figure 1c). Tip of the guidewire was successfully placed distally near the petrous segment of left ICA past the occluded segment. We were unsuccessful in advancing the VERT catheter over the guidewire. The VERT catheter was exchanged for a distal access catheter (DAC) 3.9 French (Concentric Medical, Mountain View, CA). The catheter was manipulated and advanced over the guidewire under ultrasound guidance. Distal access catheter was placed in the petrous segment. A follow-up biplane angiography was performed by injecting contrast through DAC (Figure 2). The angiographic images demonstrated filling of ICA and left anterior cerebral artery (ACA) and middle cerebral artery (MCA). Cavernous segment of left ICA appeared irregular and hypoplastic especially in the proximal cavernous segment.

Balloon angioplasty Through DAC, a 0.014 inches exchange length microwire was advanced and placed in

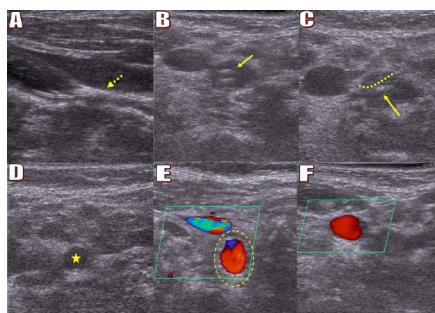


Figure 1. Ultrasound images before, during, and after the CAS procedure. **a** Longitudinal view: pre-procedure occlusion (dotted arrow) of the ICA. **b** and **c** Transverse view: pre-procedure occlusion of the lumen of artery, the tip of the VERT catheter is seen (solid arrows) in the middle of distal common carotid artery before bifurcation (dotted line shows part of the plaque). **d** patent artery (asterisk) higher than the site of closure showing the patency of the lumen and distinguishing the occlusion and patent segment. **e** and **f** Color Doppler ultrasound after stent placement showing the patency of the lumen of the ICA (red area). The internal jugular vein is shown in blue (dotted yellow circle shows the stent).

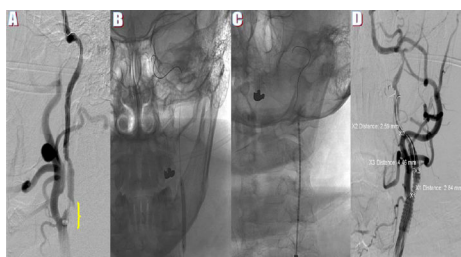


Figure 2. **a** 6-French cook shuttle is placed within the common carotid artery at the origin of left ICA, with common carotid artery injection demonstrating complete occlusion, with 0.014 inches microwire crossing the lesion and its tip placed intracranially. **b** Balloon angioplasty of left ICA (Maverick balloon 3 mm × 30 mm). **c** Stent placement across the proximal left ICA occlusion. **d** Common carotid artery injection demonstrating patent left internal carotid artery after stent deployment at the origin of left ICA covering the plaque in the left common carotid artery and left ICA.

the petrous segment. Then, DAC was withdrawn and a rapid exchange Maverick balloon 3 mm × 30 mm (Maverick® PTCA Balloon Catheters, MA) was advanced into the proximal ICA across the lesion and position was confirmed by ultrasound to ensure that the balloon remained within the circumferential confines of the cross section of the artery. The balloon was inflated to the nominal pressure. The balloon and stent were visualized during the procedure as echogenic materials within the artery with the stent being in the periphery of the artery forming a specific shape (Figure 1e). The balloon during inflation appeared as hypoechogenic globoid structure compared with the echogenicity of vessel wall. The surrounding arterial wall expansion was also identified during the procedure. Post-angioplasty images dem-

onstrated antegrade flow with irregular cervical ICA lumen and severe stenosis and calcified plaque at the origin of left ICA. Using the same Maverick balloon (3 mm × 30 mm), a second angioplasty was performed under angiographic and ultrasound guidance. Images subsequently demonstrated antegrade flow into the intracranial left ICA and left middle cerebral artery (MCA) as well as left A1 segment of anterior cerebral artery. The patient developed a transient episode of aphasia, left side gaze deviation during the second angioplasty which spontaneously resolved after balloon deflation.

Stent placement: The balloon catheter was removed over the existing 0.014 inches exchange length microwire, and replaced by a precise self-expanding stent 7 mm × 40 mm (Cordis PRECISE® PRO RX® Carotid Stent System, Bridgewater, NJ). The stent delivery catheter was placed across the lesion and position was confirmed by both angiographic and ultrasound images. The stent was deployed at the origin of left internal carotid covering the plaque in the left common carotid artery and left ICA using standard techniques (Figure 2). The procedure was completed without any complications with ~35% residual stenosis across the site of occlusion. The fluoroscopy time for the procedure was 62.8 min, and the volume of contrast medium used was 175 mL of Optiray 240 (Ioversol injection, Covidien, Mansfield, MA). Upon completion of the procedure, the 6 French sheath was removed and hemostasis was obtained with a vascular closure device.

A detailed neurological examination by a board-certified neurologist after completion of the procedure did not demonstrate any neurological deficits. The patient remained in the hospital intensive care unit (ICU) for overnight observation and was discharged home the next day. The patient was evaluated in the stroke clinic after 3 months following the procedure. A detailed interview and neurological examination by a board-certified neurologist did not identify any new ischemic symptoms or any neurological deficits.

Discussion

This report is one of the first carotid intervention procedures under duplex US guidance for the treatment of carotid occlusion. Arterial dissection and/or perforation during endovascular revascularization is one of the concerning complications of the procedure [12–14]. Such complications may occur at rates reaching up to 18% [15] necessitating further medical or interventional treatment [16,17]. The need for real time ancillary imaging

to guide revascularization of chronically occluded arteries with no flow has been previously recognized [18]. The relative inability of contrast-enhanced angiography in visualizing the arterial segment within and distal to the occluded vessel due to lack of flow is well known. The arterial wall does not produce a distinct radio-opaque signal and thus is not useful in visualizing the outer margins of the arterial wall. Identifying the relative position of endovascular devices in relation to outer wall of the artery is paramount in avoiding manipulation that can lead to local vascular injury. Stone et al reported use of a guidewire equipped with an optical coherence reflectometry that warns the operator when the wire tip reaches to a certain distance from the vessel wall for successful recanalization of chronically occluded coronary arteries [19]. However, the cost and technical complexities associated with optical coherence reflectometry have prevented broad application of this technique. Ascher et al reported carotid stent placement under duplex US in procedures involving stenosis can reduce the amount of contrast used in the procedure [18]. Our report demonstrates the use of a routinely available method that can be used at no major cost under conditions where there is no arterial flow (occlusion).

The benefits of the use of US guidance for revascularization procedure involving cervical carotid arteries are severalfolds. The view of the circumferential confines of the cross section of the artery which appear as hyperechoic signal, and the angiographic devices which appear as hyperechoic cross section in the view will facilitate the procedure. Moreover, the trajectory of guidewire movement which can be visualized by ultrasound cannot be seen by angiography and fluoroscopy. The visualization of the cross section of artery and the distal end of occlusion are also very useful markers. The site of calcification in the occlusive disease seen as a hyperechoic lesion defines the segment (particularly distal segment) for angioplasty. The hyperechoic signal of calcified plaque is easily differentiated from the echodensity of the surrounding tissue and the tissue beneath the plaque appears hypoechoic due to optical shadowing.

US guidance can be utilized for other procedures such as peripheral vascular or subclavian artery occlusions which can be visualized by an external US. Procedures with higher risk of arterial perforation such as occlusions secondary to arterial dissection require a higher level of ancillary monitoring during carotid stent placement. Similarly, patients with underlying connective tissue diseases such as Marfan syndrome may require a higher level of intraluminal monitoring and thus benefit from ancillary real time imaging.

In conclusion, this report demonstrates safe application of US guidance during the endovascular revascularization of chronic ICA occlusion. Further studies reporting on utilization of US in the interventional management of chronic carotid artery occlusion will be required to confirm the reproducibility of this technique.

Acknowledgment

We would like to thank Mrs. Jennifer Fox for her technical support in ultrasonography during the procedure.

References

1. Flaherty ML, Flemming KD, McClelland R, Jorgensen NW, Brown RD Jr. Population-based study of symptomatic internal carotid artery occlusion: incidence and long-term follow-up. *Stroke* 2004;35:e349–e52.
2. Pierce GE, Keushkerian SM, Hermreck AS, Iliopoulos JI, Thomas JH. The risk of stroke with occlusion of the internal carotid artery. *J Vasc Surg* 1989;9:74–80.
3. Cote R, Barnett HJ, Taylor DW. Internal carotid occlusion: a prospective study. *Stroke* 1983;14:898–902.
4. Nicholls SC, Bergelin R, Strandness DE. Neurologic sequelae of unilateral carotid artery occlusion: immediate and late. *J Vasc Surg* 1989;10:542–7. 547–8. discussion
5. Nicholls SC, Kohler TR, Bergelin RO, Primozych JF, Lawrence RL, Strandness DE Jr. Carotid artery occlusion: natural history. *J Vasc Surg* 1986;4:479–85.
6. Wholey MH, Wholey M, Mathias K, Roubin GS, Diethrich EB, Henry M, et al. Global experience in cervical carotid artery stent placement. *Catheter Cardiovasc Interv* 2000;50:160–7.
7. Kao HL, Lin MS, Wang CS, Lin YH, Lin LC, Chao CL, et al. Feasibility of endovascular recanalization for symptomatic cervical internal carotid artery occlusion. *J Am Coll Cardiol* 2007;49:765–71.
8. Lin MS, Lin LC, Li HY, Lin CH, Chao CC, Hsu CN, et al. Procedural safety and potential vascular complication of endovascular recanalization for chronic cervical internal carotid artery occlusion. *Circ Cardiovasc Interv* 2008;1:119–25.
9. The EC/IC Bypass Study Group. Failure of extracranial-intracranial arterial bypass to reduce the risk of ischemic stroke. Results of an international randomized trial. *N Engl J Med* 1985;313:1191–1200.
10. Powers WJ, Clarke WR, Grubb RL Jr, Videen TO, Adams HP Jr, Derdeyn CP. Extracranial-intracranial bypass surgery for stroke prevention in hemodynamic cerebral ischemia: the Carotid Occlusion Surgery Study randomized trial. *JAMA* 2011;306:1983–92.
11. Klijn CJ, Kappelle LJ. Haemodynamic stroke: clinical features, prognosis, and management. *Lancet Neurol* 2010;9:1008–17.
12. Kadkhodayan Y, Jeck DT, Moran CJ, Derdeyn CP, Cross DT 3rd. Angioplasty and stenting in carotid dissection with or without associated pseudoaneurysm. *AJNR Am J Neuroradiol* 2005;26:2328–35.
13. Sullivan TM, Gray BH, Bacharach JM, Perl J 2nd, Childs MB, Modzelewski L, et al. Angioplasty and primary stenting of the subclavian, innominate, and common carotid arteries in 83 patients. *J Vasc Surg* 1998;28:1059–65.
14. Vijayvergiya R, Otaal PS, Bagga S, Modi M. Symptomatic carotid vasospasm caused by a distal-protection device during stent angioplasty of the right internal carotid artery. *Tex Heart Inst J* 2010;37:226–9.

15. Donas KP, Mayer D, Guber I, Baumgartner R, Genoni M, Lachat M. Endovascular repair of extracranial carotid artery dissection: current status and level of evidence. *J Vasc Interv Radiol* 2008;19:1693–8.
16. Cohen JE, Gomori JM, Itshayek E. The application of subintimal flap fenestration in iatrogenic carotid artery dissection – finding light through the darkness. *J Clin Neuroscience* in press
17. Menon R, Kerry S, Norris JW, Markus HS. Treatment of cervical artery dissection: a systematic review and meta-analysis. *J Neurol Neurosurg Psychiatry* 2008;79:1122–7.
18. Ascher E, Hingorani AP, Marks N. Duplex-assisted internal carotid artery balloon angioplasty and stent placement. *Perspect Vasc Surg Endovasc Ther* 2007;19:41–47.
19. Stone GW, Colombo A, Teirstein PS, Moses JW, Leon MB, Reifart NJ, et al. Percutaneous recanalization of chronically occluded coronary arteries: procedural techniques, devices, and results. *Catheter Cardiovasc Interv* 2005;66:217–36.