

Bilateral Tri-Arterial Embolization for the Treatment of Epistaxis

Abstract

Background: Intractable epistaxis is treated by ipsilateral trans-arterial embolization of the internal maxillary artery, but there is 13-26% recurrence of bleeding. Preemptive embolization of both internal maxillary arteries along with the ipsilateral facial artery could provide maximal protection against recurrent epistaxis. We report our experience with 8 patients treated with bilateral tri-arterial embolization.

Methods: We performed a retrospective review of the patients who were treated with bilateral internal maxillary artery and ipsilateral facial artery embolization from January 2005 to January 2007. All patients had bleeding that was refractory to nasal packing.

Results: Eight patients were treated with bilateral tri-arterial embolization. The median age was 65 years (range, 35-90 years). Risk factors included hypertension (n=4), smoking (n=2), alcohol (n=2), and use of anticoagulation (n=2). All but 2 of the patients were treated under local anesthesia. All patients had complete obliteration of bleeding during the procedure, with no residual vascular blush. No major peri- or post-procedural complications were noted. Patients stayed in the hospital for 2-4 days (average 2.6 days). One patient developed ipsilateral temporofacial pain which resolved during hospitalization. Another patient had minor recurrent epistaxis on post operative day 2 which resolved with temporary repacking and the patient was discharged the next day.

Conclusion: In our experience with 8 cases, bilateral internal maxillary artery and/or ipsilateral facial artery embolization was achieved without complication and was associated with complete obliteration of vascular blush and no significant recurrent epistaxis.

Keywords: Epistaxis, arterial embolization, internal maxillary artery, polyvinyl alcohol particles

Journal of Vascular and Interventional Neurology 2008; 1(4):102-105

Qaisar A Shah, MD

Address correspondence to:
Qaisar A Shah, MD, Division of Neurosurgery,
Neurosciences Institute
Abington Memorial Hospital, 1200 Old York Rd,
Abington, PA 19001

qshah@amh.org

Epistaxis is one of the most common ear, nose, and throat emergencies. About 60% of the adult population suffers from epistaxis and 6% require emergent medical attention.¹ About 70% of epistaxis is idiopathic,²⁻⁴ although hypertension, hypercholesterolemia, alcohol abuse, acetylsalicylic acid, and other anti-inflammatory analgesic medications (NSAIDs), and anatomic defects of the nasal septum are predisposing factors.^{5,6} Structural causes include trauma, tumor, vascular abnormalities, and bleeding diathesis.⁷ Medical management consists of either anterior or posterior nasal packing and the use of local vasoconstrictors. For refractory epistaxis, surgical or endovascular procedures may be indicated. Sokoloff et al⁸ first described superselective embolization of the internal maxillary artery (IMAX) in 1974. In 13-26% of patients ipsilateral embolization of the internal maxillary artery is associated with recurrent bleeding episodes. Our study was aimed towards evaluating the safety and efficacy of bilateral IMAX and ipsilateral facial artery embolization.

Methods

We performed a retrospective review of the patients who were treated from January 2005 to January 2007 for epistaxis at our center. The medical records were reviewed to obtain information on demographics, risk factors, treatment technique, and materials used. Complications, outcome at discharge, and follow-up were also recorded.

Each patient identified for this study was treated under our standard protocols. The procedure was performed preferably under local anesthesia, but if it was difficult to maintain patency of the airway due to excessive bleeding in the oropharyngeal airway, general anesthesia was provided. A 19-gauge needle was used to gain access to the common femoral artery and a 6-French sheath was placed. A 6-French Envoy™ guide catheter (Cordis Corp, Miami Lakes, Florida) was then introduced and positioned in the proximal segment of the external carotid artery (ECA). If there was excessive aortic arch and proximal cerebral vessel tortuosity, a 6-French Simmons II™ (Cordis Corp., Johnson and Johnson, Miami Lakes, FL) guide catheter was used. The IMAX was selectively catheterized with the

From the Division of Neurosurgery, Abington Memorial Hospital, Abington, PA

use of a Prowler™ 10 or 14 (Cordis Corp) microcatheter over a Transcend™ (Boston Scientific/Target Therapeutics, Fremont, California) 0.010" or 0.014" microwire.

Trisacryl gelatin microspheres (Embosphere®; BioSphere Medical Inc., Rockland, Massachusetts) in particle sizes ranging from 300-700 microns, or polyvinyl alcohol (PVA) particles (Interventional Therapeutics Corp., San Francisco, California) in sizes ranging from 50-350 microns, were mixed with contrast for dilution and were injected through the microcatheter under fluoroscopy. Following embolization, the microcatheter was removed and positioned in the ipsilateral facial artery. Embolization of the facial artery was performed if there was contribution to the nasal vasculature. The guide catheter and the microcatheter were then positioned in the contralateral IMAX and embolization was repeated. Angiography was performed at the end of the procedure to evaluate the extent of vascular obliteration (Figure 1, A-E). Patients were admitted to the hospital and nasal packing was removed at the earliest possible time. Patients were then discharged if there was no recurrent bleeding or hemodynamic instability.

Results

A total of 8 patients were treated. A summary of demograph-

ics, history, and treatment is provided in Table 1. The median age was 65 years (range, 35-90 years). Twenty one vessels were embolized. All patients had idiopathic recurrent epistaxis. Hypertension (n=4), smoking (n=2), alcohol (n=2), and use of warfarin (n=2) were noted as risk factors for epistaxis. Complete obliteration of the vascular blush was noted in all patients. There were no peri-procedural and post-procedural complications. One patient had minor recurrent epistaxis on the 2nd day which responded to temporary repacking. That patient was discharged the following day with no further incident. One patient complained of transient left temporofacial pain which resolved during the hospital course. One patient was extubated but then required re-intubation for airway protection. No major complications were noted from the 21 embolizations. In two patients (Table 1), the facial artery was not contributing to the nasal vasculature and was therefore not embolized. In one patient, the contralateral IMAX was not embolized because it was atrophied from prior surgical treatment for meningioma of the greater wing of the sphenoid bone.

Discussion

There have been multiple published reports for embolization for recurrent and intractable epistaxis. The success rates re-

Table 1. Demographic, clinical and treatment characteristics of the study patients.

Age/ Gender	Past medical history	Bleeding side	Embolized arteries	Embolized material (size in µm)	Complications	Length of hospital stay in days
35/M	None	Left	Bilateral IMAX, left facial	Embospheres (300-500) PVA (150-250)	Transient left temporofacial pain	2
48/F	None	Right	Bilateral IMAX, right facial	Embospheres (300-500, 500-700)	Transfusion of pRBCs required Minor rebleeding on post- op day 1, packing on day 2	3
73/F	HTN, smoking, alcohol abuse	Right	Bilateral IMAX	Embospheres (100-300, 300-500)	None	4
90/M	DM, HTN, CAD, AFIB, treatment with coumadin	Left	Bilateral IMAX, left facial	Embospheres (300-500)	None	2
43/M	Stroke, PFO, treatment with coumadin	Left	Bilateral IMAX, left facial	Embospheres (150-300)	None	2
73/M	DM, HTN, ESRD	Left	Bilateral IMAX	Embospheres (300-500) PVA (250-350)	None	2
57/M	HTN, stroke	Left	Left IMAX, left facial	PVA (50-250, 350-500, 500-700)	None	2
80/M	Hyperlipidemia, seizures, smoking, alcohol abuse	Left	Left IMAX, Left facial	PVA (150-250)	None	4

Abbreviations used: M, male; F, female; IMAX, internal maxillary artery; PVA, polyvinyl alcohol; pRBCs, packed red blood cells; HTN, hypertension; DM, diabetes mellitus; CAD, coronary artery disease; AFIB, atrial fibrillation; PFO, patent foramen ovale; ESRD, end-stage renal disease

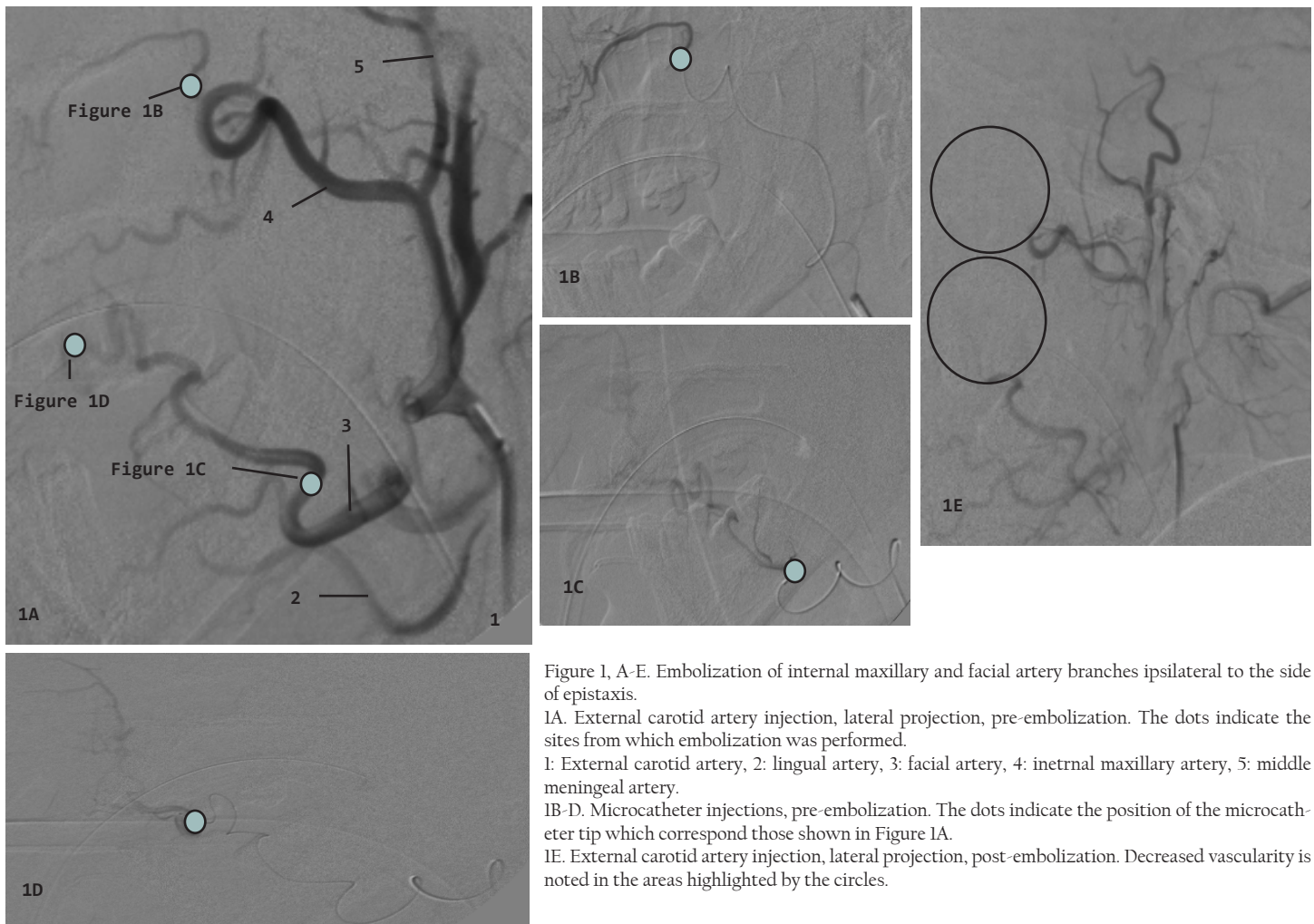


Figure 1, A-E. Embolization of internal maxillary and facial artery branches ipsilateral to the side of epistaxis.

1A. External carotid artery injection, lateral projection, pre-embolization. The dots indicate the sites from which embolization was performed.

1: External carotid artery, 2: lingual artery, 3: facial artery, 4: internal maxillary artery, 5: middle meningeal artery.

1B-D. Microcatheter injections, pre-embolization. The dots indicate the position of the microcatheter tip which correspond those shown in Figure 1A.

1E. External carotid artery injection, lateral projection, post-embolization. Decreased vascularity is noted in the areas highlighted by the circles.

ported in literature for ipsilateral IMAX embolization range from 74% to 87%.^{2,3,9,10} When this procedure fails and the ipsilateral facial and contralateral IMAX are embolized too, the success rate increases to 88%-97%.^{1,3,11,12} Moreau et al.¹, have reported 32 patients with embolization of bilateral IMAX, and in 2 patients ipsilateral facial artery. The success rate was above 95%. Oguni et al.¹² reported a series of 37 patients, 10 of whom underwent tri-arterial embolization. Recurrent epistaxis occurred in 2 patients in which the ipsilateral facial artery was not treated. Epistaxis was controlled after the tri-arterial embolization. It is presumed that, once the ipsilateral IMAX is embolized there is redistribution of blood supply through the contralateral IMAX and ipsilateral facial artery to the vascular bed leading to rebleeding episodes.⁷ Thus some authors have suggested embolizing these arteries once the rebleeding occurs.¹² Our approach was to embolize at least three arteries during the initial treatment in order to preempt any rebleeding episodes. In our case series only one patient had minor rebleeding during the hospital course which was easily and effectively treated by temporary repacking. No other risks were evident. The complication rates reported in the literature are variable, ranging from 0-50% (including minor and major complications).²⁻⁴ Minor complications include headache, pain in the temporal area, facial pain, paraesthesias, jaw pain, groin pain, numbness, and facial edema. Major complications include

hemiplegia, blindness, ophthalmoplegia, facial nerve palsy, seizures, and soft tissue necrosis.¹³⁻¹⁵ In our study, one patient developed temporofacial pain ipsilateral to the treatment which resolved during the hospital course. Although the number of treated patients is small, the findings of only one minor complication, no major complication, and only one minor rebleeding episode are encouraging.

Conclusion

Our experience with 8 cases suggests that embolization of the bilateral IMAX along with the ipsilateral facial artery in selected patients is a safe and effective procedure for treatment of refractory epistaxis and prevention of recurrence.

References

1. Moreau S, De Rugy MG, Babin E, Courtheoux P, Valdazo A. Supraselective embolization in intractable epistaxis: review of 45 cases. *Laryngoscope* 1998;108:887-8.
2. Elahi MM, Parnes LS, Fox AJ, Pelz DM, Lee DH. Therapeutic embolization in the treatment of intractable epistaxis. *Arch Otolaryngol Head Neck Surg* 1995;121:65-69.
3. Elden I, Montanera W, Terbrugge K, Willinsky R, Lasjuanias P, Charles D. Angiographic embolization for the treatment of epistaxis: a review of 108 cases. *Otolaryngol Head Neck Surg* 1994;111:44-50.
4. Vitek J. Idiopathic intractable epistaxis: endovascular therapy. *Radiol-*

- ogy 1991;181: 113-6.
5. Jackson KR, Jackson RT. Factors associated with active, refractory epistaxis. *Arch Otolaryngol Head Neck Surg* 1988;114:862-5.
 6. Pollice PA, Yoder MG. Epistaxis: a retrospective review of hospitalized patients. *Otolaryngol Head Neck Surg* 1997;117:49-53.
 7. Lasjaunias P, Berenstein A. *Surgical Neuroangiography*, Springer Berlin Heidelberg New York 1987;1: 383-387
 8. Sokoloff J, Wickbom I, McDonald D, Brahme F, Goergen TC, Goldberger LE. Therapeutic percutaneous embolization in intractable epistaxis. *Radiology* 1974;111:285-7.
 9. Strong EB, Bell DA, Johnson LP, Jacobs JM. Intractable epistaxis: transantral ligation vs. embolization: efficacy review and cost analysis. *Otolaryngol Head Neck Surg* 1995;113:674-8.
 10. Cullen MM, Tami TA. Comparison of internal maxillary artery ligation versus embolization for refractory posterior epistaxis. *Otolaryngol Head Neck Surg* 1998;118:636-42.
 11. Tseng EY, Narducci CA, Willing SJ, Sillers MJ. Angiographic embolization for epistaxis: a review of 114 cases. *Laryngoscope* 1998;108:615-9.
 12. Oguni T, Korogi Y, Yasunaga T, et al. Superselective embolisation for intractable idiopathic epistaxis. *Br J Radiol* 2000;73:1148-53.
 13. Siniluoto TM, Leinonen AS, Karttunen AI, Karjalainen HK, Jokinen KE. Embolization for the treatment of posterior epistaxis. An analysis of 31 cases. *Arch Otolaryngol Head Neck Surg* 1993;119: 837-41.
 14. Wehrli M, Lieberherr U, Valavanis A. Superselective embolization for intractable epistaxis: experiences with 19 patients. *Clin Otolaryngol Allied Sci* 1998;13:415-20.
 15. della Faille D, Schmelzer B, Vidts G, et al. Posterior epistaxis: our experience with transantral ligation and embolisation. *Acta Otorhinolaryngol Belg* 1997;51:167-71.