

Treatment of unruptured intracranial aneurysms using internally expanding coils

M. Fareed K. Suri, MD; Muhammad Zeeshan Memon, MD; Adnan I. Qureshi, MD

Zeenat Qureshi Stroke Research Center, Department of Neurology,
University of Minnesota.

Abstract

Background and Purpose: The International Subarachnoid Aneurysm Trial (ISAT) showed that patients with intracranial aneurysms treated with coil embolization have better clinical outcomes than those undergoing neurosurgical clipping. However some patients treated endovascularly have recurrence of aneurysms. Low packing density is often cited as a reason for recurrence. Coiling with hydrogel covered coils significantly improves the packing density. We report our initial experience in using a newly introduced design of hydrogel coils.

Methods: Three consecutive patients with unruptured aneurysms were treated with hydrogel coated coils. During embolization, a stable framework was first established with bare metal coils, and gel coated coils were used subsequently to increase the packing density. After the procedure, packing density was estimated by calculating the compaction ratio using an online calculator.

Results: Successful coil embolization was achieved in all 3 patients. Hydrogel coated coils comprised 11, 63 and 72% of the total coils deployed. One patient had coil herniation that required stent deployment. All patients remained neurologically intact during and after the procedure. Follow-up angiography in 2 patients at 6 months revealed aneurysm stability without any residual neck remnant.

Conclusions: The softness of the hydrogel allowed us to deploy coated coils with good packing density. A slight expansion of these coils at the neck can be expected to reduce any neck remnant and potentially inhibit recurrence.

Key words: intracranial aneurysm, coil embolization, hydrogel covered coil.

J Vasc Interv Neurol 2008; 1(2):42-45

Abbreviations, in the order used in this report.

ISAT: International Subarachnoid Aneurysm Trial

Commercial products, in the order referenced in this report.

HydroCoil®	MicroVention, Aliso Viejo, California, USA
HydroSoft™	MicroVention, Aliso Viejo, California, USA
HyperSoft™	MicroVention, Aliso Viejo, California, USA
Envoy®	Cordis Corp., Miami Lakes, Florida, USA
Excelsior®	Boston Scientific, Natick, Massachusetts, USA
Transend®	Boston Scientific, Natick, Massachusetts, USA
MicroPlex™	MicroVention, Aliso Viejo, California, USA
Neuroform®	Boston Scientific, Natick, Massachusetts, USA
MicroPlex Compass™	MicroVention, Aliso Viejo, California, USA

Introduction

Endovascular coil embolization has become the treatment of choice for many patients with intracranial aneurysms since publication of the ISAT results.¹ However, some of these same patients require repeat treatment for recurrence of an aneurysm.² Recurrence rates of 13-33% have been reported with different coils.^{3,4} Low initial packing density of coils is proposed as one of the main reasons for recurrence.^{4,5}

To improve coil packing density, hydrogel covered platinum coils were introduced (*HydroCoil* system; Figure 1). Expansion of the hydrogel after deployment of the coil significantly improves packing density in the aneurysm^{6,7} and has been demonstrated to reduce recurrence rates.⁷ These coils are slightly stiffer than the bare metal coils, which causes an in-

Correspondent: Fareed Suri, MD; Neurology, MMC 295; 420 Delaware St. SE; Minneapolis, MN 55455; USA; fareedsuri@gmail.com

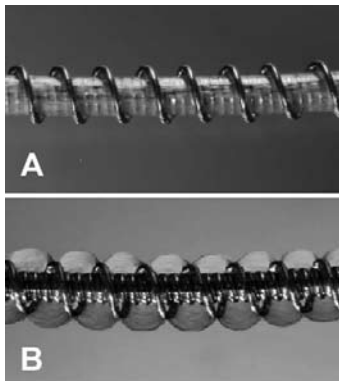


Figure 1. Pre- and post-expansion states of Hydro-Coil system (MicroVenture, Aliso Viejo, CA) coil. The stent is constructed as an inner platinum core with an outer layer of hydrogel.

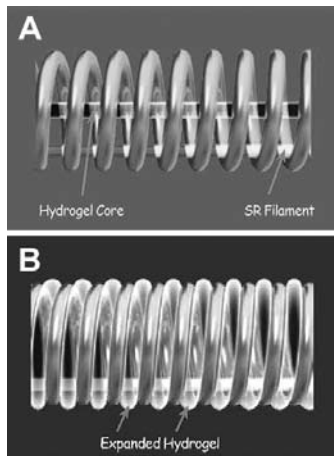


Figure 2. Pre- and post-expansion states of the *HydroSoft* coil. The stent is constructed as an inner hydrogel core with an outer platinum coil.

crease in working time and requires stable positioning of the microcatheter within the aneurysm.⁸ The expansion time for these coils is 20 minutes, also limiting the time available for adequate positioning or retraction during deployment.

Recently a new design of hydrogel coated coils has become available. The *HydroSoft* coil is constructed as a platinum coil with an inner core of hydrogel and a stretch resistant filament (Figure 2). The outer diameter of the platinum coil is 0.012 inches. When exposed to blood, the hydrogel in these coils swells to its maximum diameter of 0.013 inches in approximately 20 minutes (Figure 2 B). The idea behind the *HydroSoft* coil is to improve upon the limitations of the *HydroCoils*; that is, to provide a coil that expands to improve packing density yet has relatively low stiffness.

We report our initial experience in three consecutive patients using *HydroSoft* coils at our center.

Methods

We used *HydroSoft* coils for embolization of three consecutive patients, each with an unruptured aneurysm. The main utility for the *HydroSoft* coils (compared to *HydroCoils*) is that their softness allows filling of smaller spaces or packing near the neck. Since the *HydroSoft* coils are not designed for initial framing of the coil mass, the maximum diameter available from the manufacturer is 6 mm. Therefore, we used a three-dimensional bare platinum coil to establish a stable framework. Then we proceeded to use the hydrogel coils for packing. *Hy-*

droSoft coils were preferentially used, and *HydroCoils* were used if the desired size of *HydroSoft* coils were not available. Aneurysm packing was finished with soft, flexible bare platinum coils (*HyperSoft*).

Compaction ratio, defined as percentage volume of aneurysm filled with coil mass, was calculated using software “AngioCalc” from a website sponsored by the manufacturer of the coils.⁹ The calculator requires the dimensions of the aneurysm, the brand and diameter of the coil used, and the length of coil inserted into the aneurysm for packing density calculation.

In each case, we positioned a 6-French *Envoy* guide catheter in the distal cervical internal carotid artery. Each aneurysm was catheterized with an *Excelsior* SL-10 microcatheter over a *Transend*-14 floppy guidewire.

Results

Coil embolization was successful in all 3 patients (Table 1). *HydroSoft* coils formed 11, 63, and 72% of the total length of the coils deployed in the 3 aneurysms, respectively. The compaction ratios were 35, 45, and 72%. A neck remnant was not seen in any patient. Coil herniation occurred in one patient and required stent deployment. All patients remained neurologically intact and were discharged home within 24 hours of the procedure.

Case 1

A 52 year old female was incidentally discovered to have a left paraclinoid aneurysm that was detected during evalu-

Table 1. Angiographic and coiling characteristics of aneurysms in 3 cases.

Age/Sex	Aneurysm Location	Dimensions/ Neck Size	Bare Metal (% of Total Length)	<i>HydroCoil</i> (% of Total Length)	<i>HydroSoft</i> (% of Total Length)	Packing Density	Remnant
52/F	Left paraclinoid	8 x 7 mm/ 4 mm	36%	53%	11%	72%	0%
35/F	Right paraclinoid	8 x 7 mm/ 4 mm	37%	0%	63%	35%	< 5%
44/F	Right middle cerebral artery bifurcation	10 x 8 mm/ 4 mm	16%	12%	72%	45%	< 5%

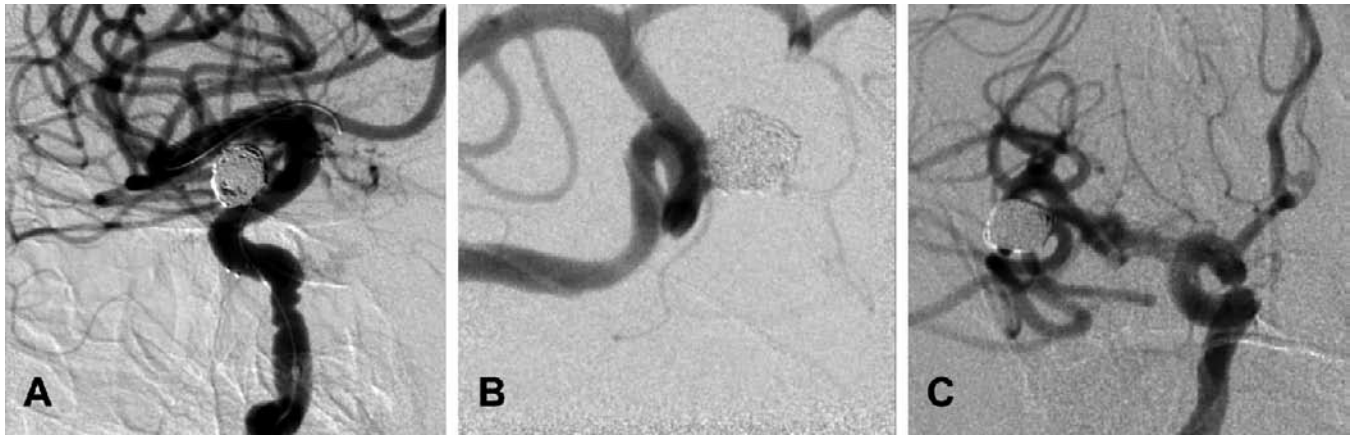


Figure 3. Post-procedure angiographic imaging of the 3 cases. **A.** Case 1, with no remnant. **B.** Case 2, with a minimal neck remnant. **C.** Case 3, also with a minimal remnant.

ation for an episode of clumsiness. The sac of the aneurysm measured 6 x 8 mm in its widest dimensions, and the neck was 4 mm. To establish a stable framework, a complex shape bare metal 7 mm x 21 cm coil (*MicroPlex*) was deployed within the aneurysm sac. This was followed by 3 *HydroCoils* (6 mm x 15 cm, 5 mm x 15 cm, and 4 mm x 10 cm). A *HydroSoft* 4 mm x 8 cm coil was then deployed. At this point the aneurysm was almost completely packed (Figure 3 A) and minor resistance was noted with the *HydroSoft* coil. A softer, smaller bare metal coil (*HyperSoft*), 3 mm x 6 cm, was then deployed. Some protrusion of the coil meshwork into the parent vessel was noted and a *Neuroform* 4.5 x 20 mm stent was then deployed across the origin of the aneurysm.

After the procedure, the patient remained neurologically intact and was discharged home the next morning. At 6 months follow-up, an angiogram showed that the aneurysm was stable without any residual neck or contrast opacification.

Case 2

A 35 year old female was found to have an incidental right paraclinoid aneurysm which measured 7 x 8 mm in its widest dimensions, with a 4 mm neck. To establish a framework, spherical bare metal coils (7 mm x 21 cm and 6 mm x 18 cm, *MicroPlex Compass*) were initially attempted but could not be deployed due to herniation in the parent vessel. A complex shape bare metal coil, 7 mm x 18 cm, (*MicroPlex*) was then advanced and deployed successfully. This was followed by 13 *HydroSoft* coils ranging 2-6 mm in diameter and 4 *HyperSoft* coils 2-3 mm diameter. In the end a 3 mm x 4 cm *HyperSoft* coil could not be advanced and was withdrawn (Figure 3 B). The patient remained neurologically stable and was discharged home the same day. At 6 months, angiography was declined by the patient but she remained clinically uneventful in the follow-up period.

Case 3

A 44 year old female with chronic headaches had an incidental finding of a right middle cerebral artery bifurcation aneurysm. The aneurysm measured 8 x 6 mm at its widest point, with a 4 mm neck. A framework was established with a complex shape bare metal coil measuring 8 mm x 20 cm (*MicroPlex*). Subsequently, a *HydroCoil* measuring 7 mm x 15 cm was deployed. This was followed by 13 *HydroSoft* coils ranging in size from 3-6 mm. There was some resistance with deployment of the last coil, and considering there was no remnant (Figure 3 C), no further coiling was attempted. The patient developed

moderate headache about 4 hours after the procedure, which was similar in character to her chronic headaches. However, the patient remained neurologically stable, the headaches subsided next morning, and she was discharged home. On the follow-up angiogram done at 6 months after coil embolization, there was no evidence of a residual neck at the site of the coil mass.

Discussion

We report our initial experience with hydrogel coated coils in three patients. *HydroSoft* coils were used as the primary packing for aneurysms in all three cases. A good packing density (35-72%) was achieved.

HydroSoft is a new brand of coils that were introduced to take advantage of the expansion properties of hydrogel without compromising the ease of use of bare metal coils. The precedent *HydroCoil* has a covering of hydrogel outside the coil, which is covered by an additional metal 'overcoil' (Figure 1). The expansion of the hydrogel allows this coil to expand during a period of about 20 minutes after coming in contact with blood. This design increases stiffness, which occasionally limits its utility if the microcatheter position is not stable within the aneurysm. The *HydroSoft* design (Figure 2) is a platinum coil with hydrogel inside the coil (as opposed to outside). This eliminates the need for the 'overcoil' and reduces the stiffness. Although the expansion of this coil is less than the *HydroCoil* (0.013 versus 0.022 inches), it can complement the *HydroCoil* system when there are problems with resistance or microcatheter instability. This is especially applicable to small aneurysms or coiling near the neck of an aneurysm. The *HydroSoft* coils do not require pre-hydration for softening and because the expansion is less than the *HydroCoil*, there is no time limitation for deployment after the coil is exposed to blood.

The packing density achieved in our cases (35-72%) was somewhat lower than previously reported in studies using hydrogel coils (45-85%)^{6,8,10} and higher than what has been achieved with other coils (30-32%).^{5,8} We expected relatively low packing densities in our cases because the *HydroCoils*, which expand more than *HydroSoft* coils, were used in lesser proportions.

All of the three aneurysms coiled in this series had necks of 4 mm and, if bare platinum coils had been used, may have required stent placement to achieve good packing density, es-

pecially near the neck. Because of the large neck dimensions of these aneurysms, the microcatheter positions were not very stable and deployment of regular *HydroCoils* could have been difficult. We believe that the softness of *HydroSoft* coils allowed us to achieve good packing which was enhanced by expansion of the hydrogel. We consider this a successful experience.

Conclusion

In our limited experience, the hydrogel coated coils can be used as both filling and finishing coils, especially if there are catheter stability issues. The slight expansion of these soft coils at the neck can be expected to reduce any neck remnant and potentially help prevent recurrence of the aneurysm.

References

1. Molyneux A, Kerr R, Stratton I, et al. International Subarachnoid Aneurysm Trial (ISAT) of neurosurgical clipping versus endovascular coiling in 2143 patients with ruptured intracranial aneurysms: a randomised trial. *Lancet* 2002; 360:1267-1274.
2. Campi A, Ramzi N, Molyneux AJ, et al. Retreatment of ruptured cerebral aneurysms in patients randomized by coiling or clipping in the International Subarachnoid Aneurysm Trial (ISAT). *Stroke* 2007; 38:1538-1544.
3. Raymond J, Guilbert F, Weill A, et al. Long-term angiographic recurrences after selective endovascular treatment of aneurysms with detachable coils. *Stroke* 2003; 34:1398-1403.
4. Wakhloo AK, Gounis MJ, Sandhu JS, Akkawi N, Schenck AE, Linfante I. Complex-shaped platinum coils for brain aneurysms: higher packing density, improved biomechanical stability, and midterm angiographic outcome. *AJNR Am J Neuroradiol* 2007; 28:1395-1400.
5. Sluzewski M, van Rooij WJ, Slob MJ, Bescos JO, Slump CH, Wijnalda D. Relation between aneurysm volume, packing, and compaction in 145 cerebral aneurysms treated with coils. *Radiology* 2004; 231:653-658.
6. Cloft HJ, Kallmes DF. Aneurysm packing with HydroCoil embolic system versus platinum coils: Initial clinical experience. *AJNR Am J Neuroradiol* 2004; 25:60-62.
7. Gaba RC, Ansari SA, Roy SS, Marden FA, Viana MAG, Malisch TW. Embolization of intracranial aneurysms with hydrogel-coated coils versus inert platinum coils: Effects on packing density, coil length and quantity, procedure performance, cost, length of hospital stay, and durability of therapy. *Stroke* 2006; 37:1443-1450.
8. Arthur AS, Wilson SA, Dixit S, Barr JD. Hydrogel-coated coils for the treatment of cerebral aneurysms: Preliminary results. *Neurosurg Focus* 2005; 18:E1.
9. AngioCalc Cerebral Aneurysm Calculator. 2006. (Accessed 6/5/08, at <http://www.angiocalc.com/index.aspx>.)
- 10 Cloft HJ. HydroCoil for Endovascular Aneurysm Occlusion (HEAL) study: 3-6 month angiographic follow-up results. *AJNR Am J Neuroradiol* 2007; 28:152-154.