

Anterior cerebral artery angioplasty for intracranial atherosclerosis

Nazli Janjua, MD; Afshin A. Divani, PhD; Adnan I. Qureshi, MD

Zeenat Qureshi Stroke Research Center, Department of Neurology and Neurosciences,
University of Medicine and Dentistry of New Jersey

Abstract

Background: Angioplasty of the intracranial vasculature has been well described for the middle cerebral artery and carotid terminus, primarily in the setting of vasospasm following subarachnoid hemorrhage. Endovascular therapy for anterior cerebral artery stenosis has not heretofore been described.

Case Report: We report the case of A1 segment angioplasty in a 77 year old man with presumed intracranial atherosclerosis.

Discussion: The proximal anterior cerebral artery serves the anterior caudate and lenticular nuclei; blockade produces motor symptoms. The anterior cerebral artery is smaller than the middle, making angioplasty more difficult. Anatomical variants are common.

Key words: anterior cerebral artery, atherosclerosis, angioplasty

J Vasc Interv Neurol 2008; 1(1):16-18

Abbreviations, in the order used in this report.

ACA:	anterior cerebral artery
MCA:	middle cerebral artery
ICA:	internal carotid artery
TCD:	transcranial Doppler
AcomA:	anterior communicating artery
SAH:	subarachnoid hemorrhage

Commercial products, in the order referenced in this report.

Envoy®	Cordis Corp, Miami Lakes, Florida, USA
Maverick®	Boston Scientific, Natick, Massachusetts, USA
Transend® EX	Boston Scientific, Natick, Massachusetts, USA

Correspondent: Nazli Janjua, MD; Department of Neurology, Long Island College Hospital, 339 Hicks St., Brooklyn, NY 11201; USA; sophiaj786@gmail.com

Introduction

Intracranial atherosclerosis of the anterior cerebral artery (ACA) is often overlooked in the context of atherosclerosis or thromboembolic disease involving the middle cerebral artery (MCA) or internal carotid artery (ICA). As the etiology of ACA atherosclerosis is often due to more widespread cerebrovascular pathology, this lack of specific attention has little implication on management. However, as endovascular therapy advances, with the possibility of direct amelioration of ACA stenosis, understanding of the presentations and risks of intervention of ACA specific disease become important.

We relate a case of A1 segment angioplasty on a patient with intracranial atherosclerosis and ACA territory infarction and we discuss the existing literature of this pathology.

Case Report

A 77 year old man presented with worsened left hemiparesis and dysarthria, occurring in the setting of preexisting left hemiparesis resulting from a stroke of three years prior. His past medical history was otherwise notable for hypertension, managed with amlodipine and hydrochlorothiazide. His other medications included aspirin 325 mg daily and clopidogrel 75 mg daily.

Computed tomography at the time of admission showed evidence of small vessel disease and an old right frontal stroke but was unrevealing of new ischemic disease. A subsequent magnetic resonance image demonstrated a new lesion on both diffusion weighted imaging (DWI, Figure 1A) within a circumscribed area of fluid attenuated inversion recovery imaging (FLAIR; Figure 1B) signal abnormality involving the mesial orbitofrontal region and caudate nucleus. Transcranial Doppler (TCD) evaluation of the intracranial circulation showed mean velocities of the right ACA twice that of the left side. An initial angiogram showed evidence of severe A1 segment stenosis (Figures 2A).

Given the patient's history of recurrent ischemic events despite double antiplatelet therapy, his new infarct in the ACA territory, and angiographic evidence of A1 stenosis found to be hemodynamically significant by TCD imaging, endovascular intervention was planned with the intention of preventing ischemic challenge to the thus far uninfarcted

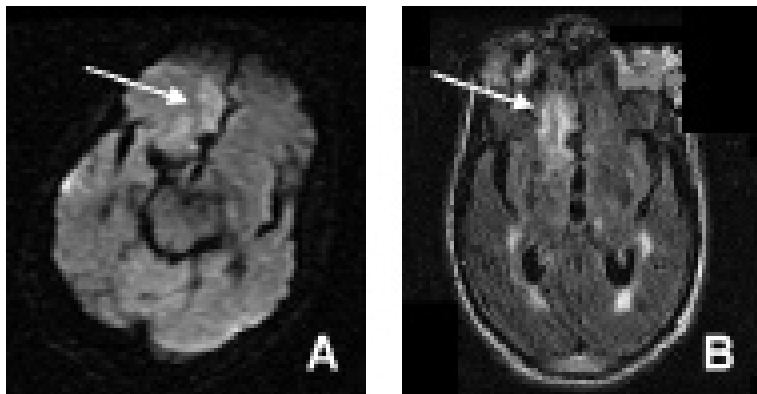


Figure 1. Axial magnetic resonance imaging showing area of acute on chronic infarction appearing as high signal on diffusion weighted imaging (A) as fluid attenuated inversion recovery image (B) indicated by arrows.

right ACA territory.

Cerebral angiography and angioplasty of the proximal A1 segment of the right ACA was performed under general anesthesia. Femoral access was established by means of a 6-French introducer sheath and heparin (5500 U) was administered to raise the activated coagulation time to 250 seconds. A 6-French *Envoy* Simmons II guide catheter was advanced to the right ICA. Digital subtraction angiographic images were taken before and after balloon inflation, with markers in place to serve as a reference guide for vessel measurement. A *Maverick* 2.0x9 mm balloon was advanced over a *Transend EX* 0.014 inch microwire to the right A1 segment and inflated at six atmospheres. As the first post-angioplasty image still showed moderate residual stenosis, an additional angioplasty to 10 atmospheres was performed and then a second *Maverick* 2.5x9 mm balloon was positioned more proximally in the A1 stem and inflated at four atmospheres. The final angiographic run showed significant resolution of the stenosis (Figure 2B).

Discussion

Discussion of ACA atherosclerosis and its treatment must first include a brief description of the anatomical divisions of the ACA and its major branches. The A1 segment arises directly from the ICA at its terminal bifurcation, and gives way to the long, post-communicating segment after its juncture with the anterior communicating artery (AcomA), which adjoins the contralateral A1 segment, completing the circle of Willis. This portion is further divided into an ascending, A2 and A3 segment and a horizontal A4 and A5 segment.¹ The important recurrent artery of Huebner typically arises just at the level of the AcomA. This branch serves the caudate head, a portion of the anterior capsule, the anterior globus pallidus, and the putamen;¹ thus, vascular pathology involving this segment and branch commonly results in contralateral hemiparesis. Many individuals possess no AcomA, have a single azygous ACA, or may have aberrant origination of two ACAs from a single unilateral robust A1 which bears importance during intervention, as inadvertent injury in such a

circumstance could lead to profound abulia, bilateral leg weakness or other aspects of a bifrontal syndrome.

The ACA differs in size from the MCA, ranging from 0.9-4.0 mm, with an average diameter of 2.6 mm,¹ in contrast to the MCA which ranges from 2.5-4.9 mm, with an average diameter of 3 mm in most individuals.² The smaller caliber of the ACA renders endovascular manipulation of it more complicated, with greater risk of vessel rupture. One of the more common clinicopathologic conditions in which ACA stenosis warrants specific intervention is the case of vasospasm following aneurysmal subarachnoid hemorrhage (SAH).³⁻⁶ However, even in many experienced centers having on-site endovascular expertise, intra-arterial instillation of vasodilators is performed in preference to angioplasty, despite the recurrence rate of the former treatment, in light of the perceived danger of angioplasty of the ACA, whereas moderate to severe MCA angioplasty is performed as routine standard of care in the setting of SAH induced vasospasm.⁷

The technical notes which deserve special emphasis and reiteration are the small sized balloon chosen for the procedure and the staged, gradual balloon inflations, routine for all cases of intracranial angioplasty. In this case a distal vessel diameter of 2.5 mm allowed the use of a coronary balloon commonly employed for cerebral angioplasty, whereas in circumstances involving diameters of 1.5 mm less, adequately sized balloons may not be as readily available.

Given the potential risks involved in this disease, knowledge of the natural history of ACA stenosis is also warranted. Retrospective studies have shown that while ICA stenosis remains stable over serial angiographic examinations, ACA as well as MCA disease is more likely to progress.⁸ Given the increased association of intracranial atherosclerosis and mortality, subsequent strokes, and myocardial events, and the failure of extracranial to intracranial bypass to achieve a success rate greater than medical therapy alone, another treatment alternative is needed.⁸⁻¹⁰

References

1. Brust JCM, Chamorro A. Anterior cerebral artery disease. In Mohr JP, Choi DW, Grotta JC, Weir B, Wolf PA, eds. *Stroke: Pathophysiology, Diagnosis and Management*, 4th Ed. London, UK: Churchill Livingstone 2004; 101-122.

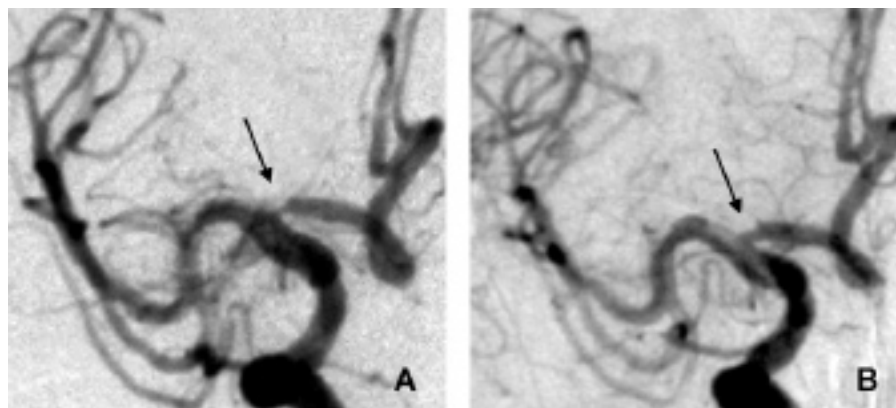


Figure 2. Anteroposterior right internal carotid artery angiogram showing area of severe A1 segment stenosis (A) and significant resolution of stenosis post angioplasty (B) indicated by arrows.

2. Mohr JP, Lazar RM, Marshall RS, Hier DB. Middle cerebral artery disease. In Mohr JP, Choi DW, Grotta JC, Weir B, Wolf PA, eds. *Stroke: Pathophysiology, Diagnosis and Management*, 4th Ed. London, UK: Churchill Livingstone 2004; 123-166.
3. Schuknecht B, Fandino J, Yuksel C, Yonekawa Y, Valavanis A. Endovascular treatment of cerebral vasospasm: Assessment of treatment effect by cerebral angiography and transcranial colour Doppler sonography. *Neuroradiology* 1999; 41:453-462.
4. Eskridge JM, Song JK, Elliott JP, Newell DW, Grady MS, Winn HR. Balloon angioplasty of the A1 segment of the anterior cerebral artery narrowed by vasospasm. Technical note. *J Neurosurg* 1999; 91:153-156.
5. Bejjani GK, Bank WO, Olan WJ, Sekhar LN. The efficacy and safety of angioplasty for cerebral vasospasm after subarachnoid hemorrhage. *Neurosurgery* 1998; 42:979-986.
6. Coyne TJ, Montanera WJ, Macdonald RL, Wallace MC. Percutaneous transluminal angioplasty for cerebral vasospasm after subarachnoid hemorrhage. *Can J Surg* 1994; 37:391-396.
7. Eskridge JM, McAuliffe W, Song JK, Deliganis AV, Newell DW, Lewis DH, Mayberg MR, Winn HR. Balloon angioplasty for the treatment of vasospasm: Results of first 50 cases. *Neurosurgery* 1998; 42:510-516.
8. Akins PT, Pilgram TK, Cross DT 3rd, Moran CJ. Natural history of stenosis from intracranial atherosclerosis by serial angiography. *Stroke* 1998; 29:433-438.
9. The EC/IC Bypass Study Group. Failure of extracranial-intracranial arterial bypass to reduce the risk of ischemic stroke: Results of an international randomized trial. *N Engl J Med* 1985; 313:1191-2000.
10. Chimowitz MI, Kokkinos J, Strong J, Brown MD, Levine SR, Silliman S, Pessin MS, Weichel E, Sila CA, Furlan AJ, Kargman DE, Sacco RL, Wityk RJ, Ford G, Fayad PB for the Warfarin-Aspirin Symptomatic Intracranial Disease Study Group. The Warfarin-Aspirin Symptomatic Intracranial Disease Study. *Neurology* 1995; 45:1488-1493.

