



Journal Homepage: - www.journalijar.com

INTERNATIONAL JOURNAL OF ADVANCED RESEARCH (IJAR)

Article DOI: 10.21474/IJAR01/17626

DOI URL: <http://dx.doi.org/10.21474/IJAR01/17626>



RESEARCH ARTICLE

A PROSPECTIVE STUDY OF FUNCTIONAL OUTCOMES FOR CLOSED FRACTURE PROXIMAL HUMERUS TREATED WITH EXTERNAL FIXATOR

Dr. Sanjeev Banerjee, Dr. Chinmaya Kumar Pradhan, Dr. H.S. Varma and Dr. Sparsh Naik

Manuscript Info

Manuscript History

Received: 28 July 2023

Final Accepted: 31 August 2023

Published: September 2023

Abstract

Background: In the aging population, the proximal humerus fracture is the third most common osteoporotic fracture type after hip and distal radius fractures, accounting for 4% of all fractures. More than 70% of the patients that present with proximal humerus fracture are over 60 years of age and 75% are women. The mechanism of low-energy injury in elderly patients is usually falling from standing height.

Aims And Objective: To study the functional outcomes for closed fracture proximal humerus treated with external fixator.

Materials And Methods: A prospective study using a clinical and X-ray assessment of 86 two- and three-part fracture of the humerus in patients that underwent external fixation.

Result: Mean scores of points were obtained using the DASH SCORE, with 80% satisfactory results. The following variables did not influence results: sex ($p > 0.05$), age ($p > 0.05$), laterality ($p > 0.05$), nor type of fracture ($p > 0.05$). Union was obtained in all cases. Reduction was considered good in 70 (81%) cases, there were 11 cases of union in varus and 4 in valgus.

Conclusion: This procedure makes it possible to obtain early satisfactory functional results and helps rehabilitation as it limits postoperative mobility to a lesser degree than other techniques; it is also less aggressive than open reduction and internal fixation and has a low complication rate.

Copy Right, IJAR, 2023.. All rights reserved.

Introduction:-

Proximal humerus fracture accounts for 4-5% of all fractures and 76% of all fractures in patients over 75 years of age with male to female ratio 1:4. About 85% of these fractures are minimally displaced or nondisplaced which respond effectively to simple conservative treatment with slings and early mobilisation.⁽¹⁾

Displaced and severely comminuted fractures and fracture with dislocation need surgical intervention. Near described classical study of fracture of proximal humerus and methods of classification and outcome evaluation scale.^(2,3)

There has been a great controversy to the management of fractures with severe displacement. Comminuted fractures affecting the joint surface, partial or total replacement is currently accepted treatment.

Closed reduction, percutaneous fixation with Kirschnerwires⁽⁴⁾ or external fixator⁽¹⁾, open osteosynthesis with plates and wiring^(5,6) rigid or flexible endomedullary nailing and inter-fragment suture⁽⁷⁾ have all been satisfactory in 50-70% of cases, depending on the specific series.

The use of open techniques may aggravate a lesion over a vascular component already affected by trauma. To prevent this, the use of percutaneous techniques has been proposed. The purpose of this study is to present the clinical and X-ray results seen with the use of external fixation technique for the treatment of 2-part and 3-part displaced fractures of the proximal humerus.

Aims And Objective:-

To study the functional outcomes for closed fracture proximal humerus treated with external fixator.

Inclusion-Exclusion Criteria

Two parts fracture through surgical or anatomical neck

Three parts fracture involving greater tuberosity where GT is undisplaced or reducible percutaneously

Two parts fracture dislocations where dislocation is reducible percutaneously

Materials And Methods:-

This is a prospective study carried out on 86 patients with fracture proximal humerus treated surgically from January 2016 to January 2021. The distribution according to sex was 61 females and 25 males with mean age of 68 years and range of 32-86 years. 52 fractures were right side humerus and 34 of them are left sided. Most of the cause was accidental fall followed by road traffic accident.

Of the total number of fractures 55 were 2 part and 31 were 3 part fracture according to Neer classification of proximal humerus fracture. And according to AO classification 56 type A, 20 type B and 10 type C fractures. Mean follow up was for 1 year. X-ray controls were carried out taking anteroposterior and axial views during the postoperative period, at 4 and 6 weeks and at 3 and 6 months and 1 year. For clinical assessment the DASH SCORE was used, it was used for assessment one year after treatment. Fracture reduction was assessed by X-rays according to Neer criteria.

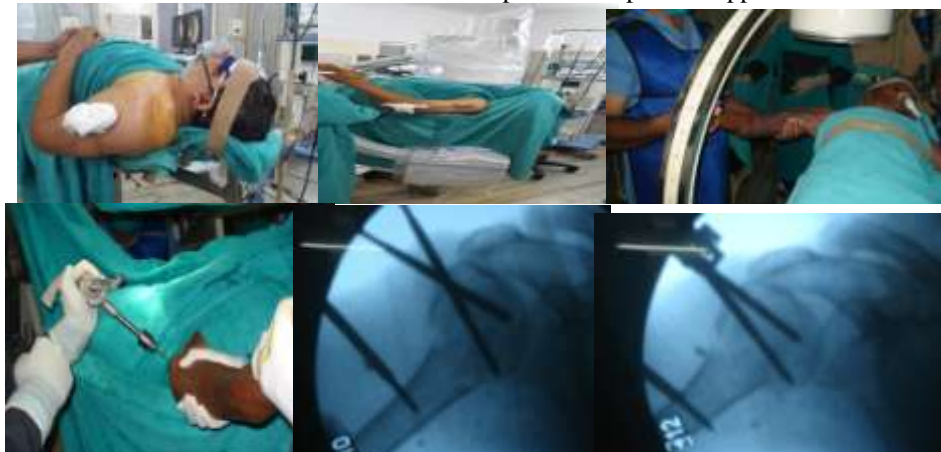Statistical analysis of the data was done using the SPSS program, chi square for the qualitative variables and Student's 't' test and variance analysis to compare mean values. Values of p less than 0.05 were considered significant.

Surgical Technique

A special head rest was attached to the operation table with clamps.

1. This head rest allows the limb to be draped free of table and perfect AP and Axillary imaging is possible by rotating the C arm like in hip fracture
2. The first step was to reduce the fracture under AP imaging.
3. Reduction was then adjusted and confirmed in the axillary view – C arm positioning was like in hip lateral view.
4. Passage of first shanz pin in head- direct slow tapping of pin using a hand drill -from anterolateral to posteromedial direction- no predrilling required- long threaded shanz pin was used.
5. Second pin was passed from posterolateral to anteromedial direction.
6. The two pins were placed at an angle of 90° to each other to get a global 360° purchase in the head and the third was usually also passed if needed.
7. Shanz pin in shaft was also inserted by direct slow tapping with hand drill- no predrilling was needed.
8. Transverse rod connected the two head pins and this was connected to the vertical rod fixing the shaft pin making a T construct. Final maneuvering and adjustment of reduction can be done and clamps tightened.
9. Two more pins were then added in the shaft and connected to the vertical rod for final fixation
10. Reduction was confirmed in the axillary view.
11. In fractures through anatomical neck approach was slightly different. The shanz pins were passed like IFS from the shaft into the head somewhat like multiple screws in neck humerus. Little difficult situation where severe displacement and shaft buttonholing through deltoid occurred and closed reduction was not possible on table

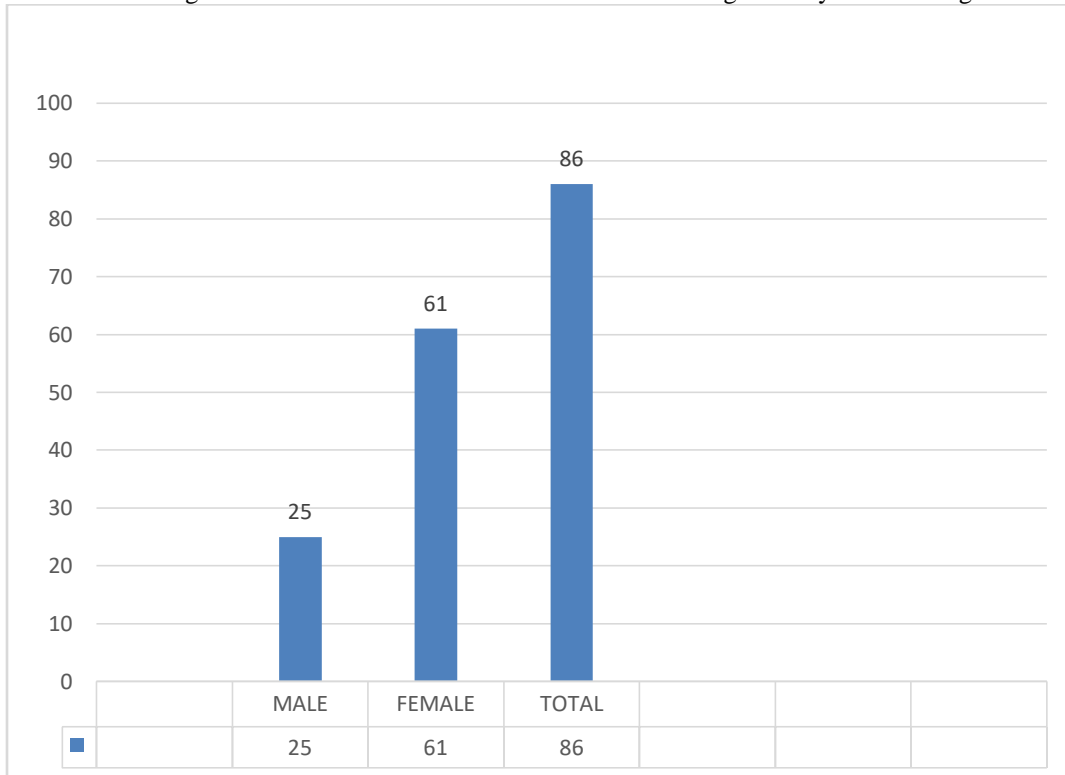
images. We aligned the fracture in AP view by marking the proximal end of shaft and made a small incision and inserted a bone spike and lever the shaft fragment and an excellent percutaneous reduction was achieved and 2 K wires were passed to hold this reduction. External fixator was then applied whenever using K wires it is essential to include them in the frame or as in this case separate clamps were applied.



Observations And Results:-

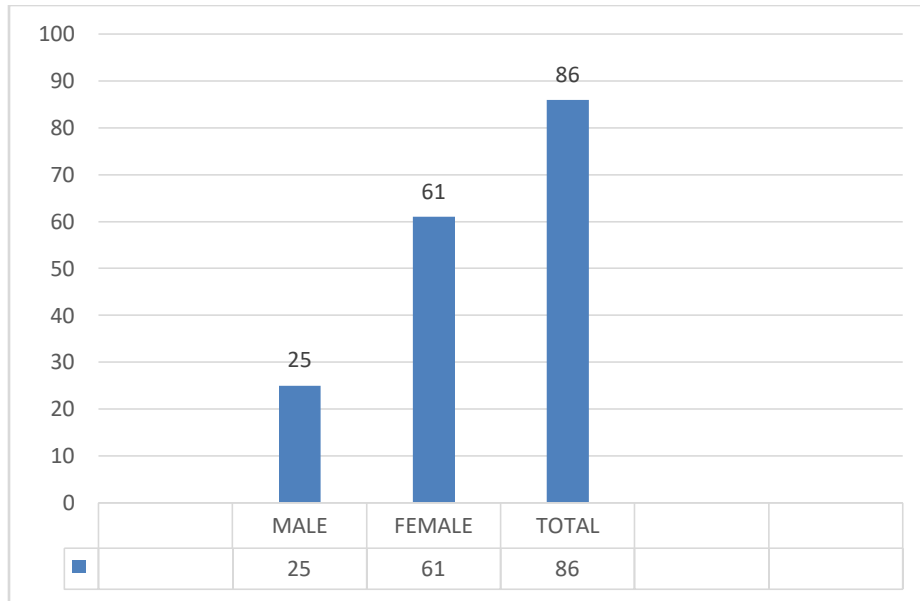
Distribution Of Study Group According To Sex

The distribution according to sex was 61 females and 25 males with mean age of 68 years and range of 32-86 years.



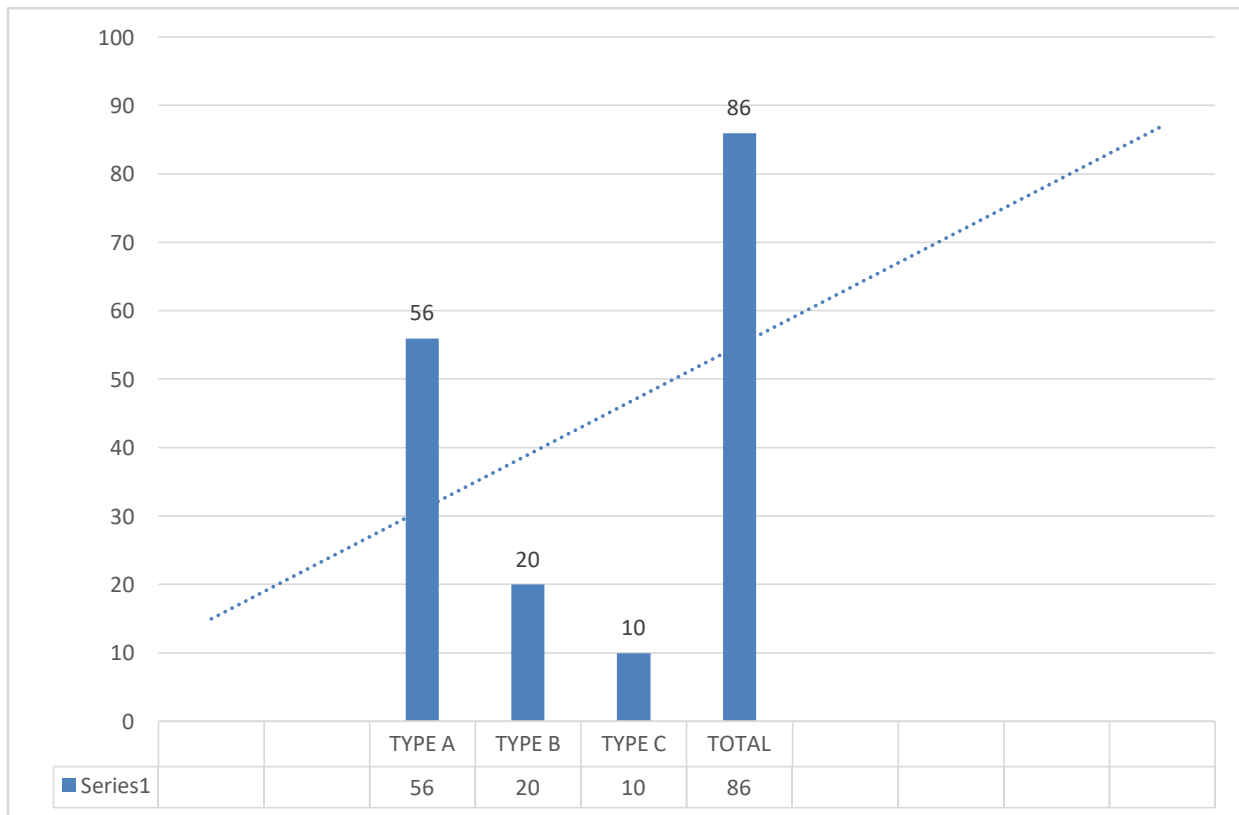
Distribution Of Study Group According To Laterality

52 fractures were right side humerus and 34 of them are left sided.



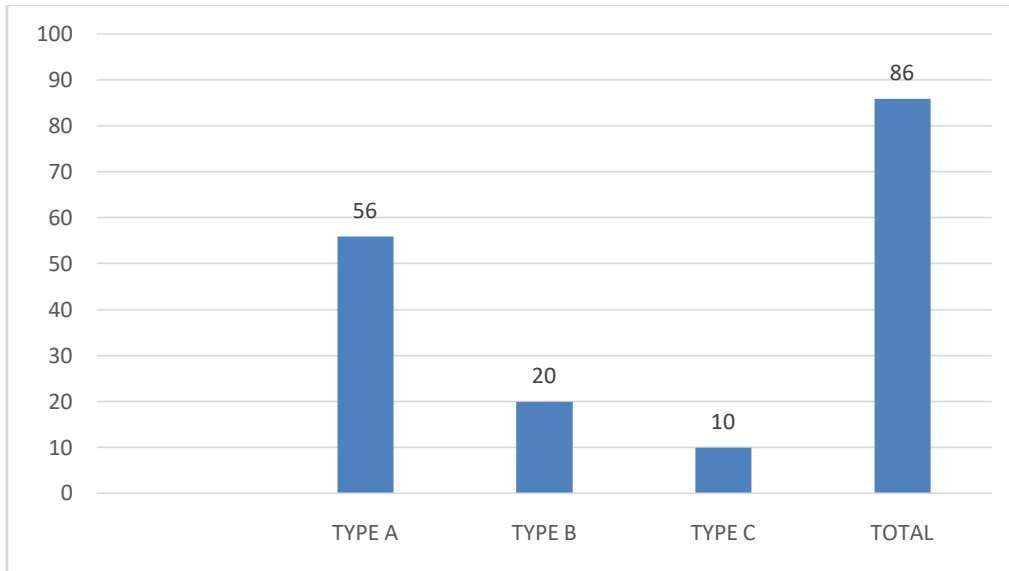
Distribution Of Study Group According To Fracture Classification (Neer Classification)

Of the total number of fractures 55 were 2part and 31 were 3part fracture according to Neer classification of proximal humerus fracture.

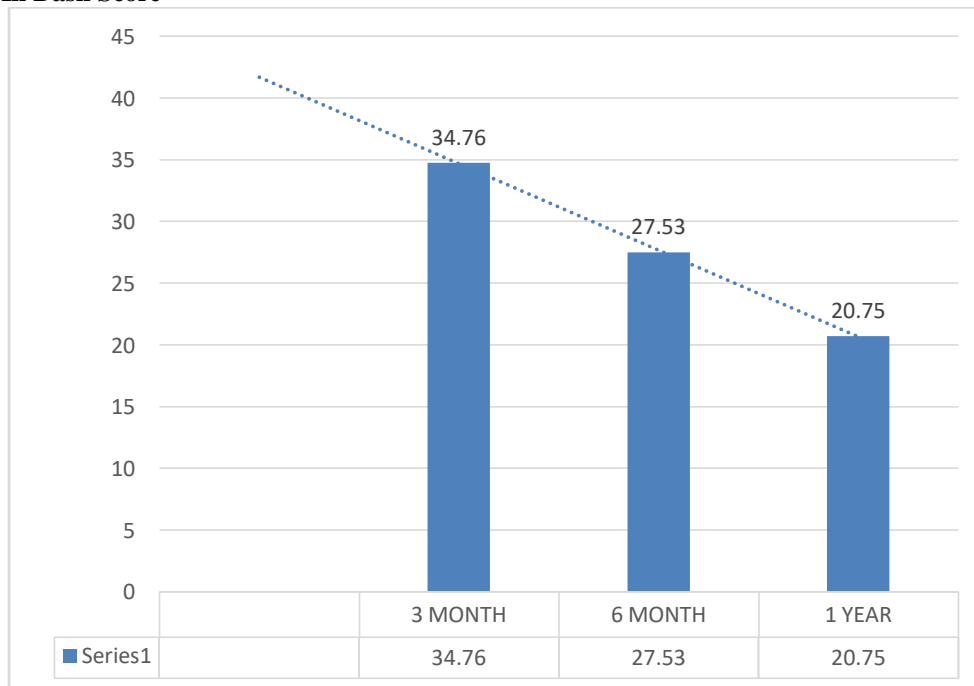


Distribution Of Study Group According To Fracture Classification (Ao Classification)

According to AO classification 56 type A ,20 type B and 10 type C fractures



Variations In Dash Score

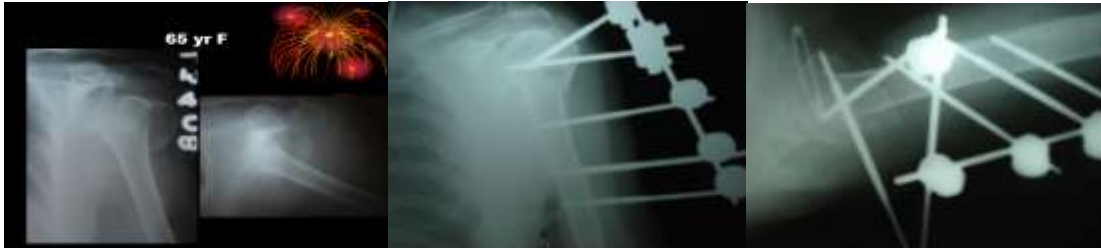

The mean score on the DASH SCORE was 20.75 points in the affected shoulder at one year, with 80% of satisfactory results (69 cases). Mean abduction achieved was 130°(50-180°), with a mean abductor force of 6.2 kg (1-9) that was 65% of the contralateral shoulder. The results were not influenced by the variables: sex (p>0.05), age (p>0.05), laterality (p >0.05), nor type of fracture (p >0.05). All cases healed.

On X-ray, reduction was considered good incase 70(81%), 11cases (12.7%) healed in varus with a mean of 20° (7-35°), and 4 cases (4%) in valgus with a mean of 23° (10-30°). Healing with lesser tuberosity ascent was not seen in any of the cases.

As early complications we can mention that 2 patients (2.3%) suffered secondary displacement with pin penetration, after another fall; this was resolved by re-intervention and repositioning of the fixator. Two cases (2.3%) presented soft tissue infection around the pins, without bone involvement. The organism isolated was S. epidermidis, and the

infection resolved with treatment with an oral antibiotic. There were no complications such as neurovascular lesions, head necrosis or non-unions.



Post Operative X Rays



X Rays After Fixator Removal

X Ray After One

Full functions at 1 year



Discussion:-

The treatment of Neer 3-part and 4-part fractures is controversial. Treatment of choice in 4-part fractures especially in elderly patients with marked osteoporosis^(2,8,6) is hemiarthroplasty. A great number of techniques are currently used for 2-part and 3-part fractures with large displacements. The aim of treatment is to achieve complete anatomical reduction and functional re-establishment of the shoulder. The greatest disadvantages of closed methods in the treatment of displaced fractures of the proximal humerus are inadequate or non-satisfactory reduction and lack of stability of the mounting that may lead to secondary displacement and a prolonged immobilization and therefore prolonged rehabilitation⁽¹⁷⁾.

Percutaneous osteosynthesis limits the risk of infection and ischemic necrosis but provides precarious stability that requires more prolonged immobilization^(6,9). Open reduction and osteosynthesis offers satisfactory stability but there is a high risk of damaging the blood supply to the head^(8,18) and therefore a risk of necrosis and also infection.

The technique used in our study avoids several of the problems associated with both methods. The reduction is done by traction and rotation of the fragments by means of the pins and is maintained preventing secondary displacements

by the fixator⁽¹⁹⁾. The probability of vascular damage and with it the risk of necrosis is minimized in this manner a primary stabilization is obtained that allows immediate rehabilitation with sufficient arc of movement.

The possible immediate complications of this technique may be prevented by using a more evolved technique. To avoid damage to the axillary nerve the proximal pins must be placed in an area near to the humeral head following the 'safe passages' described by Green⁽²⁰⁾. To prevent radial nerve damage, it is necessary to avoid positioning the distal pins beyond the deltoid V and to carry out maneuvers that direct them towards the posterior aspect of the humerus. Daily cleaning of the pins must be done to minimize risk of infection.

In conclusion, this procedure allows early satisfactory functional results to be obtained, makes rehabilitation easier by limiting postoperative movement to a lesser degree than other techniques, is less aggressive than open reduction and osteosynthesis and has a low complication rate. And a new reduction can be carried out if there is fracture displacement. For all these reasons, we consider that it is a useful technique for the treatment of 2-part and 3-part displaced fractures of the proximal humerus.

References:-

- 1-C. Martín-Hernández, M. Guillén-Soriano, J.J. Ballester-Giménez, G. López Acevedo-Medina and F. Fernández-Esteve (Treatment by External Fixation of 2-part and 3-part Proximal Humeral Fractures)
- 2-Neer CS 2nd. Displaced proximal humeral fractures: I. Classification and evaluation. *J Bone Joint Surg Am.* 1970;52A: 1077-89.
- 3-Neer CS 2nd. Displaced proximal humeral fractures: II. Treatment of three-part and four-part displacement. *J Bone Joint Surg Am.* 1970;52A:1090-103.
- 4-Herscovici D, Saunders DT, Johnson MP, Sanders R, DiPasquale T. Fijación percutánea de fracturas del segmento proximal del húmero. *Clin Orthop (esp).* 2000;4:233-40.
- 5-Herscovici D, Saunders DT, Johnson MP, Sanders R, DiPasquale T. Fijación percutánea de fracturas del segmento proximal del húmero. *Clin Orthop (esp).* 2000;4:233-40.
- 6-Gerber C, Werner CM, Vienne P. Internal fixation of complex fractures of the proximal humerus. *J Bone Joint Surg Br.* 2004;86B:848-55.
- 7-Park MC, Murthi AM, Roth NS, Blaine TA, Levine WN, Bigliani LU. Two-part and three-part fractures of the proximal humerus treated with suture fixation. *J Orthop Trauma.* 2003; 17:319-25.
- 8- Kristiansen B, Kofoed H. Transcutaneous reduction and external fixation of displaced fractures of the proximal humerus. A controlled clinical trial. *J Bone Joint Surg Br.* 1988; 70B:821-4.
- 9- Kristiansen B. External fixation of proximal humerus fracture. Clinical and cadaver study of pinning technique. *Acta Orthop Scand.* 1987;58:645-8.
10. Kristiansen B, Christensen SW. Proximal humeral fractures. Late results in relation to classification and treatment. *Acta Orthop Scand.* 1987;58:124-7.
11. Kristiansen B, Kofoed H. External fixation of displaced fractures of the proximal humerus. Technique and preliminary results. *J Bone Joint Surg Br.* 1987;69B:643-6.
12. Constant CR, Murley AH. A clinical method of functional assessment of the shoulder. *Clin Orthop.* 1987;214:160-4.
13. Rees J, Hicks J, Ribbans W. Assessment and management of three and four-part proximal humeral fractures. *Clin Orthop Relat Res.* 1998;353:18-29.
14. Kristiansen B, Angermann P, Larsen TK. Functional result following fractures of the proximal humerus. A controlled clinical study comparing two periods of immobilization. *Acta Orthop Trauma Surg.* 1989;108:339-41.
15. Gerber C, Hersche O, Berberat C. The clinical relevance of post-traumatic avascular necrosis of the humeral head. *J Shoulder Elbow Surg.* 1998;7:586-90.
16. Kristiansen B, Borgwardt A. Fracture healing monitored with strain gauges. External fixation of 7 humeral neck fractures. *Acta Orthop Scand.* 1992;6:612-4.
17. Green SA. Complications of external skeletal fixation. *Clin Orthop.* 1983;180:109-16.