

**BJMHR**British Journal of Medical and Health Research
Journal home page: www.bjmhr.com

Pneumonitis and Encephalitis Linked to Advancing Neoplastic Tumor In A Patient - A Case Report

Sudhinder Singh Chowhan^{1*}, Tarun Saxena², Prashant Kumar Singh³, Pramod Dadhich⁴

1. Department of Pharmaceutical Management, IIMR University, Jaipur (Rajasthan), India.

2. Department of Medicine, Keshavam Health Care Hospital Ajmer Rajasthan and Ex. Consultant Internal Medicine, Mittal Hospital & Research Centre, Ajmer India.

3. Department of Neurology, Prashant's Neurology Center Jaipur, Consultant Shalby Hospital, Jaipur, India.

4. Department of Pulmonology, Dadhich Chest Center and Senior Consultant, Mittal Hospital & Research Center, Ajmer India.

ABSTRACT

This case report presents a computational analysis of hemorheology in a patient diagnosed with diabetes who experienced encephalitis subsequent to pneumonitis. Hemorheology pertains to the study of blood flow characteristics and plays a critical role in comprehending and addressing various medical ailments. Employing a computational hemorheology model, the outcomes revealed noteworthy irregularities in hemorheology, which potentially contributed to the development of encephalitis following pneumonitis. Moreover, the pre-existing diabetes condition of the patient likely further complicated the hemorheological changes. These findings indicate that computational modeling of hemorheology offers valuable insights into the underlying mechanisms of diabetes-related complications and may have significant clinical implications for predicting and managing such complications. Consequently, this case report emphasizes the significance of comprehending hemorheological alterations in individuals with diabetes and underscores the potential of computational hemorheology in forecasting and addressing complications associated with this condition. The study observed abnormal hemorheology in the patient, including alterations in red blood cell deformability, aggregation, and viscosity. The findings suggest that computational modeling of hemorheology provides valuable insights into the mechanisms behind encephalitis subsequent to pneumonitis and holds potential clinical applications in predicting and managing complications associated with these conditions.

Keywords: Hemorheology, Diabetes Mellitus, Encephalitis, Pneumonitis, Drug Management

*Corresponding Author Email: sudhichowhan@yahoo.com

Received 26 June 2023, Accepted 30 July 2023

Please cite this article as: Chowhan SS *et al.*, Pneumonitis and Encephalitis Linked to Advancing Neoplastic Tumor In A Patient - A Case Report. British Journal of Medical and Health Research 2023.

INTRODUCTION

Diabetes is a chronic disorder which is characterized by high blood sugar level due to insufficiencies the secretion of insulin, insulin action or combined action. Personages with diabetes face a high risk of developing varied complications that includes cardiovascular disease, neuropathy, and nephropathy(Agrawal et al. 2014)¹.

Encephalitis, although rare, can be a potentially life-threatening complication of diabetes. It involves inflammation of the brain, leading to a range of neurological symptoms like altered consciousness, seizures, and movement disorders(Goenka et al. 2014)². Pneumonitis, another inflammatory condition, can also manifest in individuals with diabetes and further complicate the progression of the disease(Kim et al. 2023)(Taylor 2002)^{3,4}.

Understanding and managing various medical conditions, particularly diabetes-related complications, require a comprehensive understanding of hemorheology - the study of blood flow properties. Abnormal hemorheology, encompassing changes in red blood cell deformability, aggregation, and viscosity, has been implicated in the pathogenesis of several medical conditions(Ergun-Cagli et al. 2011)⁵.

Computational modeling of hemorheology holds the potential to offer valuable insights into the underlying mechanisms of different medical conditions, including complications associated with diabetes(Yesudasan and Averett 2019)⁶. By employing computational models to analyze blood flow properties, researchers can identify alterations that may influence the development of obstacles and enable to formulation of preventive measures or effective management strategies(Rychik et al. 2019)⁷.

Diabetes mellitus is a pervasive and intricate metabolic syndrome that involves lots of individuals worldwide. DM is accompanying with an assortment of complications, containing cardiovascular disease, neuropathy, and nephropathy(Mezil and Abed 2021)⁸. Among these complications, diabetes-related encephalitis emerges as a rare yet potentially life-threatening condition. Encephalitis is characterized by inflammation of the brain, leading to a broad range of neurological symptoms that can result in permanent brain damage or even mortality. Pneumonitis, another inflammatory condition, can also arise in individuals with diabetes, further complicating the disease trajectory(Cullinan and Seymour 2013)⁹.

Hemorheology, which encompasses the study of blood flow properties, plays a pivotal role in comprehending and managing various medical conditions, including complications related to diabetes(Baskurt 2007)¹⁰. This case report endeavors to present a computational characterization of hemorheology in a patient diagnosed with diabetes who experienced encephalitis subsequent to pneumonitis. Employing a computational hemorheology model, the study analyzed the patient's blood flow properties, focusing on red blood cell

deformability, aggregation, and viscosity(Yousuf et al. 2013)¹¹. The findings revealed substantial abnormalities in hemorheology, which likely contributed to the development of encephalitis following pneumonitis(Saad et al. 2023)¹². Furthermore, the existing diabetes condition of the patient possibly further complicated the changes in hemorheology(Navaneetharaja et al. 2016)¹³.

Recognizing the significance of understanding hemorheology in the context of diabetes-related complications is of utmost importance(Landon et al. 2020)¹⁴. By enhancing our understanding of the underlying mechanisms, computational hemorheology holds promising clinical applications in predicting and managing complications associated with these conditions. Consequently, this case report underscores the necessity for further research in this field and emphasizes the integration of hemorheology into the clinical management of patients with diabetes and its related complications(Lumsden and Rice 2006)¹⁵.

CASE PRESENTATION

A 69-year-old woman, previously in good health, was admitted to private Hospital, Ajmer on January 29, 2022, after experiencing illness for one week. She presented with symptoms such as poorly controlled diabetes, low-grade fever, restlessness in breathing, chest congestion, and signs of upper respiratory infection and pneumonia. The possibility of viral encephalitis was ruled out. Her medical history included a diagnosis of type 2 diabetes mellitus, hypertension, coronary artery disease, and post-percutaneous transluminal coronary angioplasty status.

Upon arrival at the hospital emergency cell, the patient exhibited abnormal body movements, altered sensorium, and increased tone in all limbs. Physical examination revealed a blood pressure of 134/88 mmHg, body temperature of 97.6°F, pulse rate of 106 beats per minute, and respiratory rate of 26 breaths per minute. The patient displayed altered sensorium, abnormal body movements, and increased tone in all limbs. Central nervous system examination indicated altered sensorium with a “Glasgow Coma Scale” (GCS) score of E2, V3, M6, and bilateral non-reactive and non-constricted pupils. She was able to move all four limbs, and no abnormalities were observed in the cranial nerve examination.

During hospitalization, the patient exhibited disorientation and a dull response, but without neck stiffness. On the 8th hour of hospitalization, consultation with a physician, neurologist, and pulmonologist resulted in a diagnosis of central nervous system involvement. Computed tomography of the head revealed subtle cortical hypodensity in the right temporal lobe and gliotic areas in the right cerebellar hemisphere. High-resolution computed tomography of the thorax showed patchy opacities in the posterior segments of the bilateral upper and lower lobes, suggestive of pneumonitis (CO-RADS-2). Magnetic resonance imaging of the head

with contrast revealed T2/FLAIR hypersensitivity in the cortex of the right temporal lobe, mid-cortical hyperintensity in the right basis-frontal region, and a small gliotic area in the right cerebellar hemisphere. Digital chest X-rays also displayed subtle opacities suggestive of pneumonitis. The patient received conservative treatment, including intravenous fluids, antibiotics, neuroprotective agents, and other supportive therapies. Follow-up consultations with a neurologist, chest physician, ophthalmologist, and cardiologist were conducted. On February 4, 2022, the patient was discharged in a conscious and oriented state with stable vital signs.

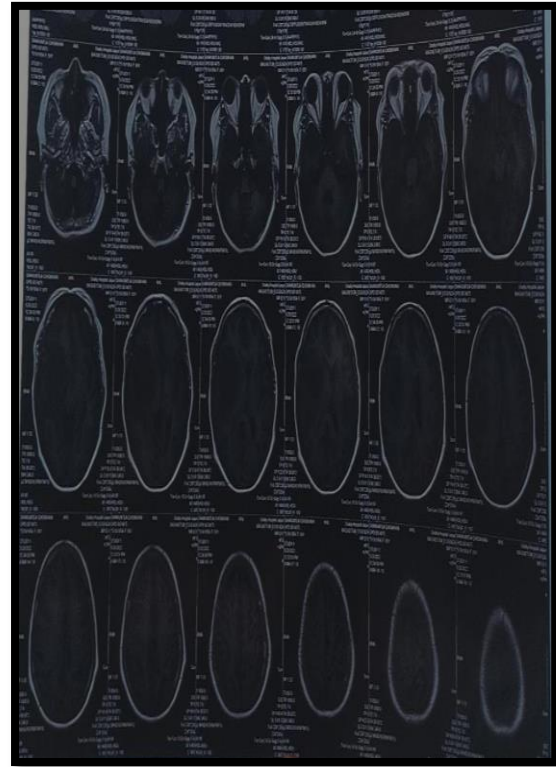
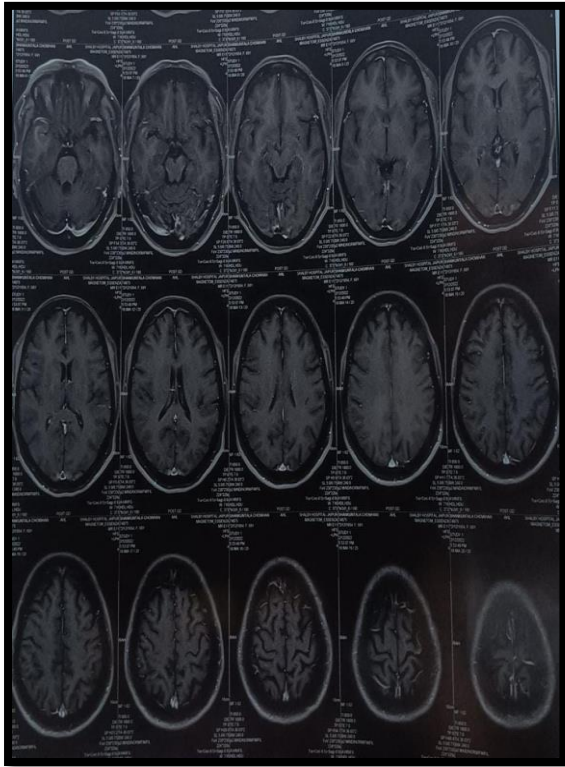


Figure 1: MRI Image Showed mild heterogeneously enhancing, predominantly surrounding edema in the right T2 hyperintense focal mass lesion dated May 20, 2022

Figure 2: MRI Image Showed mild heterogeneously enhancing, predominantly surrounding edema in the right perisylvian frontotemporal region.

May 20, 2022

On May 19, 2023, the patient was readmitted to Private Hospital, Jaipur, under the care of the neurological intensive care unit, complaining of headache, vertigo, and difficulties in maintaining body balance. Physical examination and brain magnetic resonance imaging revealed a heterogeneously enhancing, predominantly T2 hyperintense focal mass lesion measuring 4.7x4.2x5.8 cm, with mild surrounding edema in the right perisylvian frontotemporal region. The mass exhibited multiple hemorrhagic foci showing blooming on corresponding gradient echo/susceptibility-weighted images and received prominent arterial blood supply through the right middle cerebral artery branches. The mass effect resulted in partial effacement and displacement of the right lateral ventricle, causing a midline shift

measuring approximately 7-8 mm toward the left side. Additionally, small focal T2 hyperintense areas were observed in the right cerebellum, likely representing chronic infarcts with gliotic/encephalomalacia changes due to old infarcts. Based on radiological findings, a high-grade neoplastic tumor of primary astrocytic/glial origin or metastatic etiology. Later on, the patient deteriorated and on June 05, 2023, the patient passed away eventually.

DISCUSSION

The computational analysis of hemorheology in a patient with diabetes who developed encephalitis following pneumonitis, as presented in this case report, emphasizes the clinical value of this approach. The study's findings reveal significant abnormalities in hemorheology, including decreased deformability of red blood cells and increased aggregation and viscosity(Szapary et al. 2004)¹⁶. These abnormalities may have played a role in the development of encephalitis in the patient, with pre-existing diabetes potentially exacerbating the observed hemorheological changes(Biller and Love 2004)(Sharma and Chowhan 2013b)^{17,18}

The utilization of computational hemorheology models in this study provides important insights into the underlying mechanisms of diabetes-related complications. By analyzing blood flow properties, researchers can identify changes that contribute to the development of complications and devise strategies to prevent or manage them. For instance, interventions aimed at improving blood flow properties, such as exercise or pharmacological agents, may hold promise in preventing or managing complications associated with diabetes-related encephalitis(Kumar et al. 2021)(Sharma and Chowhan 2013a)(Gorelick et al. 2011)¹⁹⁻²¹.

Furthermore, the findings suggest that computational hemorheology holds potential clinical applications in predicting and managing diabetes-related complications. The ability to predict changes in hemorheology using computational models in response to various interventions can aid in the development of personalized treatment plans for individuals with diabetes and related conditions. Additionally, incorporating hemorheology into routine clinical assessments will help in identifying the patient's high risk for any complications, enabling early interventions.

This case report underscores the importance of comprehending hemorheology in diabetes-related complications and highlights the potential clinical value of computational hemorheology in predicting and managing these complications(Chowhan 2019)²². In near future it is necessary to validate these results and determine the clinical implications of hemorheological changes in diabetes-related complications(Mishra et al. 2019)²³.

CONCLUSION

This case report highlights the significance of understanding hemorheological changes in

diabetes-related complications, particularly in the context of encephalitis following pneumonitis(Kim et al. 2023)³. The study's findings reveal notable abnormalities in hemorheology in a patient with diabetes who experienced encephalitis after pneumonitis. It is worth noting that pre-existing diabetes likely contributed to the observed hemorheological changes, emphasizing the importance of effective management strategies. The utilization of computational hemorheology, in this case, the report offers valuable insights into the underlying mechanisms of diabetes-related complications. This approach shows potential clinical applications in predicting and managing complications associated with diabetes-related encephalitis. Interventions aimed at improving blood flow properties, such as exercise or pharmacological agents, may prove beneficial in preventing or managing these complications. The findings of this case report explain and suggest that computational hemorheology holds potential clinical utility in predicting and managing diabetes-related complications. Nonetheless, this case report provides important insights into the role of hemorheology in diabetes-related encephalitis and emphasizes the importance of managing hemorheological changes in individuals with diabetes.

ACKNOWLEDGMENT

We would like to thank IIHMR University, Jaipur, Keshavam Health Care Hospital, Dr. Prashant's Neurology Center, Dadhich Clinic, Mittal Hospital & Research Centre, and Abhay Anchal Research Foundation Ajmer for support in data tabulating.

CONTRIBUTIONS OF THE AUTHOR

The final manuscript was read and approved by the author.

Funding

This research received no outside support.

Availability of Data and Materials

This published paper contains all of the data generated or analyzed during this investigation.

Approval for Ethics and Consent to Participate

This page contains no research involving human or animal subjects conducted by any of the writers.

Permission for Publication

The manuscript's publishing has been approved by all of the authors.

Competing Interests Declaration

The authors declare that they are unaware of any competing financial interests or personal relationships that may have appeared to influence the work reported in the paper, and that we do not have any commercial or associative interest that would represent a conflict of interest in connection with the work submitted.

REFERENCES

1. Agrawal, R., Ola, V., Bishnoi, P., Gothwal, S., Sirohi, P., & Agrawal, R. (2014). Prevalence of micro and macrovascular complications and their risk factors in type-2 diabetes mellitus. *JAPI*, 62, 505.
2. Goenka, A., Michael, B. D., Ledger, E., Hart, I. J., Absoud, M., Chow, G., ... & Kneen, R. (2014). Neurological manifestations of influenza infection in children and adults: results of a National British Surveillance Study. *Clinical Infectious Diseases*, 58(6), 775-784.
3. Kim, H. J., Lee, S. J., Sa, S., Bae, J. H., Song, G., Lee, C. W., & Han, H. W. (2023). Safety of COVID-19 vaccines among patients with type 2 diabetes mellitus: real-world data analysis. *Diabetes & Metabolism Journal*, 47(3), 356-365.
4. Taylor, G. W. (2002). Periodontal health and systemic disorders. *J Can Dent Assoc*, 68(3), 188-92.
5. Ergun-Cagli, K., Ileri-Gurel, E., Ozeke, O., Seringec, N., Yalcinkaya, A., Kocabeyoglu, S., ... & Dikmenoglu, N. (2011). Blood viscosity changes in slow coronary flow patients. *Clinical hemorheology and microcirculation*, 47(1), 27-35.
6. Yesudasan, S., & Averett, R. D. (2019). Recent advances in computational modeling of fibrin clot formation: A review. *Computational biology and chemistry*, 83, 107148.
7. Rychik, J., Atz, A. M., Celermajer, D. S., Deal, B. J., Gatzoulis, M. A., Gewillig, M. H., & American Heart Association Council on Cardiovascular Disease in the Young and Council on Cardiovascular and Stroke Nursing. (2019). Evaluation and management of the child and adult with Fontan circulation: a scientific statement from the American Heart Association. *Circulation*, 140(6), e234-e284.
8. Mezil, S. A., & Abed, B. A. (2021). Complication of diabetes mellitus. *Annals of the Romanian Society for Cell Biology*, 1546-1556.
9. Cullinan MP, Seymour GJ. Periodontal disease and systemic illness: Will the evidence ever be enough?. *Periodontology*. 2000;62(1):271-286.
10. Baskurt, O. (2007). Clinical significance of hemorheological alterations. *Handbook of hemorheology and hemodynamics*, 69, 392.
11. Yousuf, O., Mohanty, B. D., Martin, S. S., Joshi, P. H., Blaha, M. J., Nasir, K., ... & Budoff, M. J. (2013). High-sensitivity C-reactive protein and cardiovascular disease: a resolute belief or an elusive link?. *Journal of the American College of Cardiology*, 62(5), 397-408.
12. Saad H, Soliman HA, Mahmoud B, Moneim AA, Zaky MY. The Pathogenic Role of Oxidative Stress, Cytokine Expression, and Impaired Hematological Indices in

Diabetic Cardiovascular Diseases. *Inflammation*. 2023;46(1):146-160.

13. Navaneetharaja, N., Griffiths, V., Wileman, T., & Carding, S. R. (2016). A role for the intestinal microbiota and virome in myalgic encephalomyelitis/chronic fatigue syndrome (ME/CFS)?. *Journal of clinical medicine*, 5(6), 55.
14. Landon, R., Gueguen, V., Petite, H., Letourneur, D., Pavon-Djavid, G., & Anagnostou, F. (2020). Impact of astaxanthin on diabetes pathogenesis and chronic complications. *Marine drugs*, 18(7), 357.
15. Lumsden AB, Rice TW. Medical management of peripheral arterial disease: a therapeutic algorithm. *Journal of Endovascular Therapy*. 2006;13(2_suppl):II-19.
16. Szapary, L., Horvath, B., Marton, Z., Alexy, T., Demeter, N., Szots, M., ... & Toth, K. (2004). Hemorheological disturbances in patients with chronic cerebrovascular diseases. *Clinical hemorheology and microcirculation*, 31(1), 1-9.
17. Biller, J., & Love, B. B. (2004). Ischemic cerebrovascular disease. *Neurology in clinical practice*, 3, 1125-1166.
18. Sharma, S. K., & Chowhan, S. S. (2013). Patient survey to measure the quality of care provided by health care providers in OPD of tertiary care hospitals. *Indian J Research*, 2(2), 208-9.
19. Kumar, S., Behl, T., Sachdeva, M., Sehgal, A., Kumari, S., Kumar, A., & Bungau, S. (2021). Implicating the effect of ketogenic diet as a preventive measure to obesity and diabetes mellitus. *Life sciences*, 264, 118661.
20. Gorelick, P. B., Scuteri, A., Black, S. E., DeCarli, C., Greenberg, S. M., Iadecola, C., & Seshadri, S. (2011). Vascular contributions to cognitive impairment and dementia: a statement for healthcare professionals from the American Heart Association/American Stroke Association. *stroke*, 42(9), 2672-2713.
21. Sharma, S. K., & Chowhan, S. S. (2013). Patient Waiting Time: It's Impact on Hospital Outpatient Department. *International J Scientific Research*, 2(3), 253-254.
22. Chowhan, S. S. (2019). To Study the Doctor's Perception Prescribing practice for Cefpodoxime. *Think India Journal*, 22(35), 997-1001.
23. Mishra, S. K., Chowhan, S. S., Shah, R., Jha, N., Shankar, P. R., Bhandary, S., & Gorkhaly, A. P. (2019). Knowledge, attitude and practice regarding eye health and eye health services in Nepal.

BJMHR is

- **Peer reviewed**
- **Monthly**
- **Rapid publication**
- **Submit your next manuscript at**

editor@bjmhr.com

