

**BJMHR**British Journal of Medical and Health Research  
Journal home page: [www.bjmhr.com](http://www.bjmhr.com)

## Parotid Cyst: A Rare Case Report

Priti S Hajare<sup>\*</sup>, A Sanikop, Shilpa D Mallapur, Akash Rai, A.S. Harugop, Vinita Metgudmath  
*JNMC, KLE University Belagavi*

### ABSTRACT

Major salivary gland swellings frequently lead to a differential diagnosis that are frequently linked to cystic degeneration or are totally cystic in character. Retention cysts are real cysts that infrequently affect the major salivary glands. Only 2-5% of the swellings of the major salivary glands are non-neoplastic in nature, and 6–9% of them present as cystic lesions.<sup>1</sup> The parotid gland cysts are equally common in both men and women, and they often manifest as a single, painless swelling in the parotid region that does not involve the skin or facial nerve below. The majority of reported instances have acquired origins and are blamed on obstructive processes. They exhibit a great deal of heterogeneity in epithelial lining type.<sup>2</sup> Any area of the parotid gland can develop a cystic lesion, although the lips, buccal mucosa, and mouth floor are the most frequent locations. They are typically unilateral, which prompts a parotid tumour.<sup>2</sup>

**Keywords:** Salivary swelling Parotid cyst Benign swelling

\*Corresponding Author Email: [pratihajare987@gmail.com](mailto:pratihajare987@gmail.com)

Received 22 July 2023, Accepted 07 August 2023

Please cite this article as: Hajare PS *et al.*, Parotid Cyst: A Rare Case Report. British Journal of Medical and Health Research 2023.

## INTRODUCTION

Simple intraparotid retention cysts can form in patients who occasionally have duct obstruction brought on by strictures, calculi, mucus plugs, neoplasms, or trauma. Retention cysts can develop as a result of secretion retention; their epithelial lining distinguishes them from pseudocysts, which are covered in granulation tissue.<sup>3</sup>

They signify mucus extravasation into the parenchyma of the salivary glands. First brachial cleft cysts or lymphoepithelial cysts are uncommon intraparotid cysts. Compared to neck branchial cysts that originate from the cervical sinus, they are less common.

Careful clinical examination is necessary for the management of a patient who has a swelling of the parotid area. For a definitive diagnosis, USG guided FNAC or biopsy are always necessary, though USG and CT scan may also be helpful.<sup>4</sup> Here, we report a rare instance of a retention cyst affecting a 42-year-old man's left parotid gland.

## CASE REPORT:

A 42-year-old male patient has been experiencing gradual, insidious swelling in the left parotid region for the past three years. was at first smaller in size but has grown to its present size of roughly 3\*4 cm

On Examination- The swelling was approximately 3x3 cm, non tender, no local rise in temperature, firm, non reducible with limited mobility and well defined margins. CT Neck (plain)- show a well defined hypodense cystic area in the superficial lobe of the left parotid gland, approximately measuring 2.5(antero-posterior)x 2.1(medio-lateral) x 2(cc) cm with few isodense tiny eccentric mural nodules within it, largest cavity measuring 6x5 mm. No evidence of extension noted into the deep parotid gland.

FNAC of the swelling demonstrated, pus like material, microscopy revealed numerous cyst macrophages and few epithelial cells in a proteinaceous and necrotic background, features suggestive of cystic lesion of the parotid.

The patient then underwent enucleation of the parotid cyst and specimen was sent for histopathological evaluation.

Gross examination revealed a globular soft tissue piece with attached fatty tissue piece measuring. On cut section a cystic cavity identified measuring 4x2 cms.

Microscopy revealed a cyst lined by benign epithelial cells with a lymph node which shows reactive changes. Impression was of a benign cyst of parotid gland with a reactive lymph node. Post operatively the patient was doing well and was discharged with antibiotics and analgesics.

## DISCUSSION:

Minor salivary glands are the ones that are most frequently affected by retention cysts, while major salivary glands are rarely affected. However, compared to any of the other major salivary glands, the parotid gland is more frequently affected by cysts and congenital lesions when they do occur.

About 5% of salivary gland tumours are cystic lesions of the parotid gland, many of which are cystic components of neoplasms.<sup>5</sup>

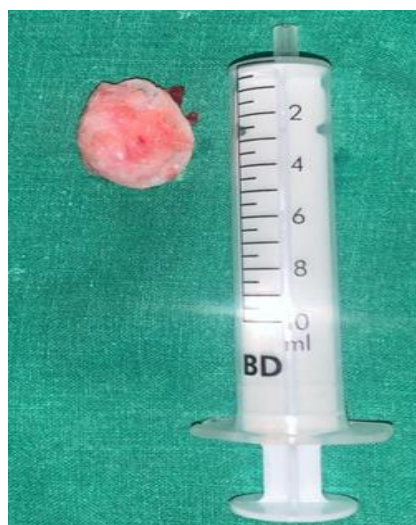Histologically, the most common types of cysts are:

- 1) Simple cyst
- 2) Lymphoepithelial cysts
- 3) Parotid polycystic disease
- 4) Tumours with cysts. In 183 cases,

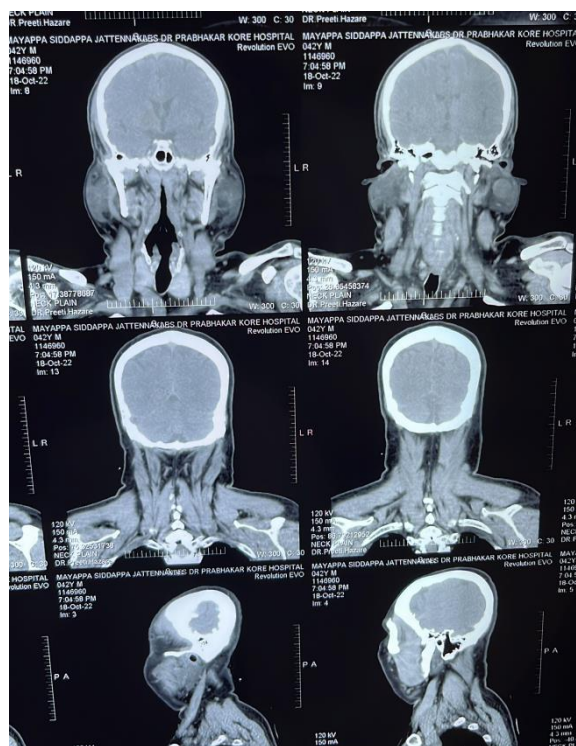
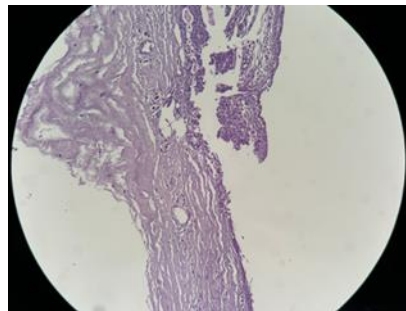
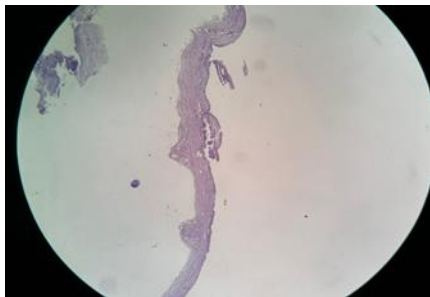
Pieterse et al. reported 16 intraparotid cysts (8.7%), of which 9 (4.9%) had parotid neoplasms while the other 7 (3.8%) were unrelated to tumours.<sup>6</sup> In order to remove the parotid cyst as safely as possible, Brennan et al. recommended a conservative approach.<sup>7</sup>

In their study examining the fluid on aspirate of parotid cysts, Wong et al. came to the conclusion that a thorough work-up should be performed as with other non-cystic lesions because the physical characteristics of the fluid aspirate communicate little to no relevant information for clinical decision making.<sup>7</sup> A parotid cyst may be challenging to diagnose, especially if it is close to the facial nerve and may unilaterally trigger a parotid tumour. Many writers have also hypothesized that a salivary gland cyst could be a precursor to a salivary gland tumour. The clinician, radiologist and pathologist all have a major role to arrive at confirmatory diagnosis. It takes a multidisciplinary approach to come forth the diagnosis of a parotid cyst because it is a rare finding.

The following are gross specimens of the parotid cyst



The following are histopathological slides of the specimen, 20x and 100x respectively



## CONCLUSION

Retention cysts of the parotid gland origin are very uncommon and difficult to diagnose, but they should nevertheless be taken into consideration as a differential diagnosis in situations of painless, persistent parotid gland enlargement to rule out malignant tumours.

## REFERENCES

1. Klijanienko J, Vielh P, Batsakis JG. (Eds.). Salivary gland tumours. 15ed. Karger Medical and Scientific Publishers; 2000
2. Antoniadis K, Karakasis D, Tzarou V, Skordalaki A. Benign cysts of the parotid gland. International journal of oral and maxillofacial surgery. 1990 Jun 1;19(3):139-40
3. Qannam A, Bello IO, Al-Kindi M, Al-Hindi M. Unicystic mucoepidermoid carcinoma presenting as a salivary duct cyst. International journal of surgical pathology. 2013 Apr;21(2):181-5.
4. Batsakis JG. Tumors of head and Neck. Baltimore, MD: Williams & Wilkins, 1974: 63.

5. Holliday RA et al. Benign lymphoepithelial parotid cysts and hyperplastic cervical adenopathy in AIDS- risks patients: a new CT appearance. Radiology 1988: 168: 439-41.
6. Brennan MF et al. Simple Parotid cysts. Aust N Z J Surg 1970: 40: 15-19.
7. DS et al. The role of fine needle aspiration cytology in the management of parotid tumors: a critical clinical appraisal Head Neck. 2000: 22:467-73

**BJMHR is**

- **Peer reviewed**
- **Monthly**
- **Rapid publication**
- **Submit your next manuscript at**

**editor@bjmhr.com**

