

# Determining Entrance-Exit Gunshot Holes on Skulls: A Real Time and *In situ* Measurement Method

John Z Wang\*

Forensic Studies Program, School of Criminology, Criminal Justice and Emergency Management, California State University-Long Beach, California

\*Corresponding author: John Z Wang, Forensic Studies Program, School of Criminology, Criminal Justice and Emergency Management, California State University-Long Beach, California, Tel: +1 562-985-4741; E-mail: [zwang2@csulb.edu](mailto:zwang2@csulb.edu)

Received date: October 17, 2018; Accepted date: November 01, 2018; Published date: November 07, 2018

Copyright: ©2018 Wang JZ. This is an open-access article distributed under the terms of the Creative Commons Attribution License, which permits unrestricted use, distribution, and reproduction in any medium, provided the original author and source are credited.

## Abstract

Currently, determination of an entrance or exit hole/wound on a skull is largely based on the word description issued by a medical examiner or a forensic pathologist in an autopsy report. Such description is an approximate dimension with rulers (plastic or paper) placed next to the bullet holes, lacking specific quantitative measurements due to the small size of bullet holes and available devices. In this study, a novel technique, namely a digital viewer, is utilized to measure the common characteristics of the entrance/exit holes, providing a more objective description. Using a quasi-experimental design, a simulated skull with an entrance and an exit hole is used to perform the linear, triangular, and circular measurements, producing real time measurements and near 3D images of gunshot holes on a skull at an *in situ* position. As a result, a more objective and accurate image is obtained for a more scientific entrance-exit gunshot holes determination.

**Keywords:** Forensic science; Forensic medicine; Forensic pathology; Gunshot wounds; Entrance/Exit holes; Chipping; Beveling; Keyhole phenomenon; Crime scene investigation; Shooting scene reconstruction

## Introduction

One of the toughest decisions in a gunshot skull is to determine which one is the entrance hole and which is an exit hole. Currently, these determinations are provided with the morphological characteristics by an examiner or a pathologist. Specifically, an autopsy report at the present stage presents findings using word descriptions based on an approximate dimension with rulers (plastic or paper) placed next to the bullet holes. Such findings lack specific quantitative measurement due to the small size of bullet holes and also due to lack of capable devices for a better description. However, due to the recent reports by NCS, PCAST, and court challenges, a quantitative description of entry/exit holes is needed for a more scientific and accurate approach. Although a 3D image approach was conducted to describe gunshot wounds on skulls, the method did not provide any actual measurements of gunshot holes on skulls [1]. Therefore, in this quasi-experimental study, four types of gunshot morphology on a flat skull are measured using a hand-held digital viewer, the clean hole, the chipping effect on the entrance hole, the beveling effect and the keyhole phenomena on the exit hole.

For the sake of discussion, the term “gunshot holes” is used instead of “gunshot wound” since this study focuses on a skull in a stage where all muscular tissues are gone due to the decomposition. However, the principle for a determination of the entrance/exit holes between the two is quite similar.

Human bone, including skulls, is a specialized form of densely connected tissues composed of calcium salts embedded in a matrix of collagenous fibers [2]. The morphology of gunshot holes on skull usually results from several factors, such as the shooting distance,

velocity of the bullet, the angle of the shooting, the making of the bullets (FMJ, SMJ, lead, or steel), the weight of the bullet, the types of bone (long, flat), and the thickness of the bone [3,4]. Therefore, a human skull is a cranial vault/cavity that is classified under the flat bone category, and its related gunshot holes/wounds should be analyzed accordingly [5].

## Existing Criteria

Since this study focuses on providing a better description of the entrance/exit gunshot holes that penetrate the skull, the following are four practical criteria commonly accepted to determine the entrance/exit holes [2]. First, the size of an entrance hole is usually smaller than the exit hole in diameter with a round to oval shape. Second, the chipping effect refers to the perforating edge by the bullet's striking or impacting around the entrance hole on skulls. The phenomenon is largely due to an angle between the muzzle (the shooting direction) and the surface of the skull. It also can indicate a close range or contact shot. Depending on the distance, it may show several concentric detachments of small superficial bone fragments with irregular shapes. Third, the effect is the ballistic feature on the exit hole. It usually appears to be a cone-like or funnel shape, presenting slanted missing defects on the outer table when the bullet passes from the entrance through the bone to the exit surface. Usually, the beveling hole is larger than the entrance hole because of the impact force that expands at the exterior layer [6]. Finally, a key-hole shaped wound of bone may be seen when a bullet strikes the skull from an angle, producing a sharp semi-circle edge at one end (similar to an entrance hole), and the beveling or cone-shape edge at the other end (similar to an exit hole). In other words, when a bullet hits the skull, a characteristic “keyhole” is formed a defect that is circular at one end and some fractures at the opposite end (Figure 5, the lower end of the exit hole), radiating outwards in parallel. The keyhole phenomenon was first introduced by Dixon [7]. It is the largest bone lesion among the four, resulting in tongue-shaped bone loss due to the physical force by the bullet at an

angled entrance impact. The bullet usually produces a triangle plate that is leveled out on the cortical bone.

The determination of entrance versus exit holes, however, is usually made based on the following: 1) by visual observation of a linear ruler (plastic or paper) for approximate measurements, which lacks real-time measurements, 2) By description by words, this lacks a close-up image, and 3) By the four conceptual principles mentioned above, which lacks a 3D image, In sum a better method is much needed for the entrance-exit hole determination with near 3D images, real-time measurements, and from an *in situ* position for a more scientific and accurate comparison.

## Materials and Methods

This study followed the purposive sampling method. Due to the policy set up by the Internal Research Review at the University, a real human skull was not available nor is permitted; the author instead purchased a simulated skull with an entrance and an exit holes from a bone clone company that claims its skulls and holes are “virtually indistinguishable from the original”. Since the main purpose of this study is not to test the genuinity of bone structure and morphology, but to provide a quantitative measurement and description of gunshot holes on skulls, the author believes the replica stands the minimum similarities by the material. Thus, no animal bones or real human skulls were used for this study. Based on a close observation it was found that the simulated skull bears a similar structure of a cranial vault: the two layers of cortical bone (inner and outer) with the interposition of a thin layer of spongy bone.

## The Device

The hand-held digital device is a digital viewer with several unique features. First, the device can be connected to a laptop *via* a USB with an extended cord, thus being portable for a crime scene examination, especially, if an *in situ* examination is required. Second, the device takes digital images (JPEG) and provides in a real-time manner ten different measurement modes, such as linear, triangular, circular, and arch quantitative data. Next, the digital image can be ranked as a near 3D image, providing the details, especially on a beveling portion and a keyhole like characteristic of the exit wound for a quantitative description for an entrance-exit hole determination. The digital viewer has four light alternatives: black/white, UV, Infrared, and polarized light sources, each with a magnification of up to 200X. The multiple light sources provide more options when certain residues exist around the two holes, such as gunshot residue, gunpowder residue, bone chips, aged bloodstains, or even possible dry human tissues. Further, since the images can be taken at a scene or in a lab in an *in situ* position with different digital modes, images with the measurements can be transmitted *via* Wi-Fi communication from the scene to the lab as well as to evidence storage. Finally, if needed, the digital device can be connected to a projector for a live demonstration analysis at any location, such as crime scenes, police departments, labs, DA's offices or even in courtrooms for an expert's testimony. In sum, the hand-held viewer with micro-digital measurements (mm or inch up to 0.001) is a very practical tool for a medical examination at the scene or in the lab.

## The Quasi-experimental Design

Although an experimental project was conducted to observe the rifle wounds on skins [8], this study employs a quasi-experimental design to provide real-time quantitative measurements and near 3D

images of gunshot holes on skulls for an entrance-exit hole determination. The strength of a quasi-experimental approach allows stimulation of a scenario where a skull was found at a crime scene [9]. First, the purchased skull was buried half-way in a wooded area next to a community (Figure 1) to simulate a crime scene. Second, the skull was picked up and placed on an autopsy table and photographed by a regular digital camera for both the front and rear views (Figures 2 and 4) to simulate preparation for an autopsy examination. Once the basic scenarios are set, and the replica of the skull bears the basic morphology of the gunshot holes on the cranial vault of a real human skull, the hand-held digital viewer was set up in an *in situ* position to take near 3D images for real-time measurements.



Figure 1: The photograph of a human skull taken by a regular digital camera to simulate a crime scene.

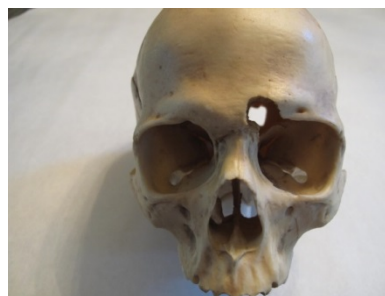

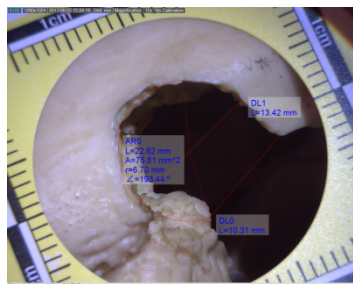
Figure 2: The front view photograph of the gunshot hole taken by a regular digital camera.

## Results

The hand-held digital viewer has several unique features: to take images of gunshot holes in the field and an *in situ* position, meaning the viewer can be adjusted to focus on gunshot holes if the skull cannot be removed to avoid possible damage to the overall skeleton at the scene (Figure 1) or in the lab (Figure 2). These two photographs are offered for two possible scenarios for the study, and the device was calibrated before the image was taken and verified by an actual ruler.

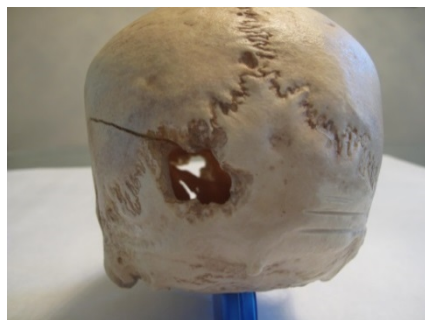
Figure 3 provides a near 3D image of the gunshot hole from the frontal skull, which is a circular hole with an opening at the right eye pocket. Three lines of real-time measurements are shown by the image. First, the diameter of the gunshot hole is measured for 13.42 mm (DL1). This number can be used to associate a diameter of the weapon caliber causing the gunshot hole [10]. However, as a warning the size of the bullet hole does not always directly correlate to an exact bullet caliber due to several factors, such as the bullet shape, jacket material,

stability of the bullet's flight path, shooting distance, and medium the bullet has passed through.



**Figure 3:** The image of the front view of the gunshot hole photographed by the hand-held digital viewer that provides real-time measurements for a near 3D effect at an *in situ* position.

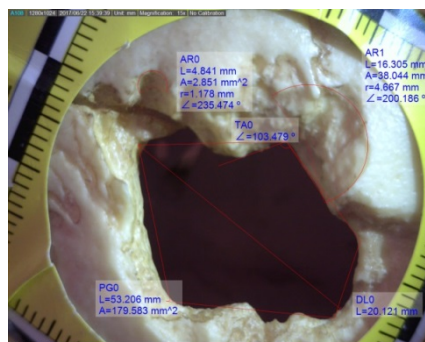
Second, a half circle measurement is made for three different data: 1) the radius, which is the half of the diameter. 2) The maximum area measured at an angle of 193.44° to indicate a round/oval shape, which is a typical shape for an entrance gunshot hole. 3) The measured circle at an angle of 193.44 for an area of 75.81 mm<sup>2</sup> can be used to indicate the chipping effects along the perforated edge. Finally, a linear distance of 10.31 mm (DLO) is determined to indicate the opening of the gunshot hole, or the damage of the entrance gunshot wound. As a result, the real-time and near 3D image can better describe the features of the gunshot entrance hole. If a bullet penetrates the skull perpendicular to the surface, a round defect is formed, often with outward chipping effects extending from the bullet hole.



**Figure 4:** The rear view photograph of the gunshot hole taken by a regular digital camera.

Figure 5 display a near 3D image of the gunshot hole from the rear view, which is a circular hole in the left side of the back skull. Again, three lines of real-time measurements are shown by the image. First, the linear distance of 20.12 mm (DLO) proves that the exit hole does appear bigger than the entrance hole (13.42 mm) because of the impact force that expands at the exterior layer [6]. Second, the two-half circle measurements (AR0 and AR1) show the beveling effect, which is the ballistic feature on an exit gunshot hole with either a cone-like or a funnel shape. The slanted missing defects on the outer table are produced when the bullet passes from the entrance through the bone to the exit surface. Finally, the diamond measurement (PG0) provides a realistic image of a key-hole shaped wound of bone when a bullet strikes the skull from an angle, producing a semi-circle edge at one end

(similar to an entrance hole) and the beveling or cone-shape edge at the other end (similar to an exit hole). Thus, the three unique ballistic features belong to a typical exit gunshot hole with its shooting direction identified. In conclusion, the physical relationship between the two gunshot holes can be summarized as follows: The force of the bullet's entrance increases the intracranial pressure inside the skull, causing the pieces of bone between the radiating fractures to push outwards at the exit.



**Figure 5:** The image of the rear view of the gunshot hole photographed by the hand-held digital viewer that provides real-time measurements for a near 3D effect at an *in situ* position

## Discussion

The morphological analyses of gunshot holes/wounds on skulls remain a key component and unavoidable portion of the medical examination and crime scene investigation. Gunshot wounds on a skull usually have both entrance and exit holes. Medical examiners and forensic pathologists need to determine the entrance-exit holes for both the cause and manner of death. Such a determination using the traditional method is by words and regular ruler, which lacks quantitative and real-time techniques. Crime scene investigators also need to determine which one is the entrance hole and which one is the exit hole for later shooting reconstruction and shooting position determination. The word description for the morphological assessments and autopsy reports by medical examiners, forensic pathologists, and crime scene investigators can be better assisted if there is supplementary descriptions: such as a quantitative measurement in real time from an *in situ* manner.

This quasi-experimental study provides near 3D images with real-time measurements at an *in situ* position. Figure 3 and Figure 5 provides quantitative foundations for entrance-exit hole determination. Of the two holes, exit holes often tend to be much larger than entrance wounds for three reasons: 1) The bullet is misshaped or 'mushroomed' from the initial bone strike, 2) The bullet may no longer be moving along a straight trajectory, 3) The projectile may be tumbling end-over-end. Future studies should measure different variables that affect the type of damage done to the bone, such as (a) The velocity of the bullet, which depends on the type of gun used, (b) the distance between the shooter and the victim, (c) the size/caliber of the bullet on skulls, and (d) the angle of impact. It is hoped that this quasi-experimental study may provide real-time measurements with 3D images and support several earlier landmark projects [11-14].

---

## References

1. Myers JC, Okoye M, Kiple D, Kimmerle E, Reinhard K (1999) Three-dimensional (3-D) imaging in post mortem examinations: Elucidation and identification of cranial and facial fractures in victims of homicide utilizing 3-D computerized imaging reconstruction techniques. *Int J Legal Med* 113: 33–37.
2. Di Maio V (2016) *Gunshot wounds: Practical aspects of firearms, ballistics and forensic techniques* (3rd Ed.) Boca Raton, FL, CRC Press.
3. Quaterhomme G, İşcan MY (1999) Characteristics of gunshot wounds to the skull. *J Forensic Sci* 44: 568–576.
4. Quaterhomme G, İscan MY (1998) Gunshot wounds to the skull: Comparison of entries and exits. *Forensic Sci Int* 94: 141–146.
5. Mohd N, Das S (2012) Gunshot wound in skeletonized human remains with partial adipocere formation. *J Forensic Leg Med* 19: 42–45.
6. Brenner J (2004) *Forensic science: An illustrated dictionary* (1ST Ed). Boca Raton, FL, CRC Press.
7. Dixon DS (1984) Exit keyhole lesion and direction of fire in a gunshot wound of the skull. *J Forensic Science* 29: 336-339.
8. Rainio J, Lalu K, Ranta H, Penttila A (2003) Morphology of experimental assault rifle skin wounds. *Int J Legal Med* 117: 19-26.
9. Wang J (2016) Quantifiable comparison of partial-full fingerprints at scenes using a hand-held digital device: A quasi-experimental design study. *J Forensic Investigation* 4: 6.
10. Berryman H, Smith O, Symes S (1995) Diameter of cranial gunshot wounds as a function of bullet caliber. *J Forensic Sci* 40: 751–754.
11. Dixon D (1982) Keyhole lesions in gunshot wounds of the skull and direction of fire. *J Forensic Sci* 27: 555-566.
12. Coe J (1982) External beveling of entrance wounds by handguns. *Am J Forensic Med Pathol* 3: 215-219.
13. Berryman HE, Kutyla AK, Davis J (2010) Detection of gunshot primer residues on bone in an experimental setting-an unexpected finding. *J Forensic Sci* 55: 488-491.
14. Amadasi A, Mazzarelli D, Merli D, Brandone A, Cattanes C (2017) Characteristics and frequency of chipping effects in near-contact gunshot wounds. *J Forensic Sci*. 62: 786-790.