




Literature Review: Rehabilitation of Ear Congenital Abnormalities

Rama Andreas 

Student of Prosthodontics Specialist Study Program, Faculty of Dentistry Universitas Padjadjaran, Indonesia

Patria Legawa Anggadinata 

Student of Prosthodontics Specialist Study Program, Faculty of Dentistry Universitas Padjadjaran, Indonesia

Bey Johan Arifin 

Student of Prosthodontics Specialist Study Program, Faculty of Dentistry Universitas Padjadjaran, Indonesia

Nuroh Najmi* 

Department of Oral Biology, Faculty of Dentistry Universitas Padjadjaran, Indonesia

Achmad Syawqie

Department of Oral Biology, Faculty of Dentistry Universitas Padjadjaran, Indonesia

Article Information

Suggested Citation:

Andreas, R., Anggadinata, P.L., Arifin, B.J., Najmi, N. & Syawqie, A. (2023). Literature Review: Rehabilitation of Ear Congenital Abnormalities. *European Journal of Theoretical and Applied Sciences*, 1(3), 191-195.

DOI: [10.59324/ejtas.2023.1\(3\).21](https://doi.org/10.59324/ejtas.2023.1(3).21)

* Corresponding author:

Nuroh Najmi, e-mail:
nuroh@unpad.ac.id

Abstract:

Newborn ear deformity can be treated with baby ear correction as a non-surgical treatment to avoid plastic surgery. In the new born period, the auricle and cartilage bones are elastic, and an abnormality the auricle structure can be corrected by medical action. The purpose of this systematic review is to understand the origins and the treatment of ear abnormalities in patients. The results of a systematic review show that microtia is an outer ear disorder whose cause is not clearly known. However, genetic factors, viral infections, chemical poisoning, and teratogenic medicines in young pregnant women are suspected to be the cause. The conclusion is microtia an outer ear condition with skin or cartilage loss forms small, slips off, or only the ear canal is present. Microtia treatment comprises restoring hearing ability and reconstructing the outer ear.

Keywords: ear deformity, microtia, earwell.

Introduction

Auricle or pinna, is one of the most complex shapes in humans because of the position and paired structure. Deformities of the auricle often cause psychological distress that is greater than the size of the defect. The normal shape and proportions of the ear are easily recognized but it is difficult to reconstruct the ear without good surgical technique and a good appreciation of the configuration of the normal ear. The auricle

has a three-dimensional topography that is made up of skin and cartilage. The cartilaginous structure is composed of fibro elastic cartilage that is covered by a thin layer of skin. The auricle collects blood from two major arteries: the posterior branch of the superficial temporal artery (a) and the posterior auricular artery. The retromandibular vein, the superficial temporal vein, and the external jugular vein are all part of the venous drainage system. Lymphatic drainage



through the parotid gland, mastoid, superior cervical and infraclavicular lymph nodes.

The human ear is divided into three parts: the outer ear, the middle ear, and the inner ear. The outer ear is separated into two parts: the auricle and the external auditory canal, which serve as a protective structure for the middle ear's tympanic membrane as well as a fundamental filter for sound stimuli entering the ear. The auricle or earlobe is commonly referred to as the "ear" since it is the most visible feature of the human face and one of the sections that plays a crucial visually for the human face (Schultz et al., 2017). The outer ear nerves are the sensory branches of the four cranial nerves. The auricular nerve major supplies the lower half of the ear and part of the pre-auricular area. The auriculotemporal nerve supplies the anterior surface of the ear and tragus. The occipital nerve minor supplies the upper ear and mastoid area.

The outer ear begins to form embryological at 6 weeks of age from tissues coming from the first and second branching arches. By 13 weeks, the meatal plug has expanded and formed the tympanic membrane. At 18 weeks, the meatus is fully formed, as are all parts of the outer ear (van Nunen et al., 2014). The purpose of this systematic review is to understand the origins and the treatment of ear abnormalities in patients.

Embryology

The development of the outer ear begins at 6 weeks of fetal age. The outer ear develops from the pharyngeal cleft and the first of pouch. At the beginning of the third month of fetal age, the epithelial cells at the bottom of the hole will begin to proliferate, and will form a solid epithelial plate and meatus plug. Auricle development begins from six proliferative portions of mesenchyme located at the dorsal ends of the first and second pharyngeal arches, which surround the first pharyngeal cleft. The six sections will begin to protrude (Hillocks). It is divided into two parts, and there will be 3 pieces on each side.

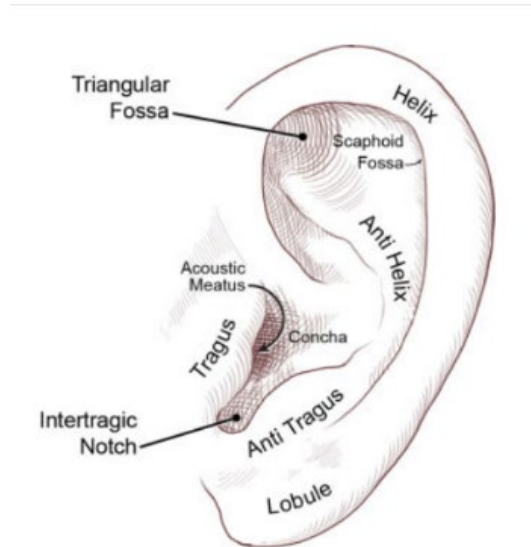


Figure 1. Ear Anatomy

Source: Texas Children's Hospital

The first protuberance forms the tragus; the second cusp forms the crus helices; the third bulge forms a helix; fourth cusp forms the antihelix; the fifth protuberance forms the antitragus; and the sixth cusp forms the ear lobule.

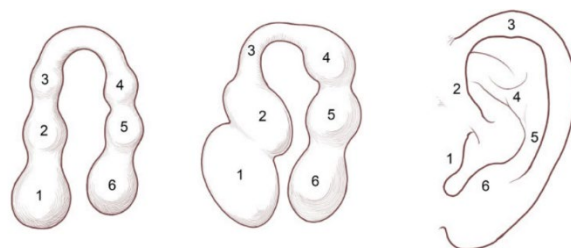


Figure 2. The Development of Ears With 6 Hillocks Appears in the Early Fetal Period Until Adulthood

Source: Texas Children's Hospital

Microtia will occur if the six protuberances are not perfect in their development and do not unite with each other. In general, the more severe the microtia disorder occurs in a patient, the less formed the middle ear will be in that patient.

Epidemiology and Pathophysiology

The exact incidence of ear problems is unknown, however estimates range from 15% to 20% of all

newborns (Bhatti et al., 2021). Microtia and anotia diseases are known to have a global frequency of 2.6 in every 10,000 births (Marfatia et al., 2016). Patients with ear problems such as microtia and anotia have a slim probability of receiving non-surgical treatment. As a result, getting a reference to a professional who can undertake therapy as soon as feasible is strongly recommended. Earlobe deformities can have significant psychological effects on sufferers, including decreased self-confidence, anxiety, depression, and other behavioral problems. These symptoms will considerably improve with reconstruction of the ear abnormality (Bhatti et al., 2021).

Congenital ear abnormalities are caused by the absence or abnormality of the neonatal ear's skin and/or cartilage. Auricular malformations and deformations are two types of auricular anomalies. Malformations are produced by disrupted embryogenesis, which results in inadequate structural growth. Anotia (absence of the outer ear), microtia (underdeveloped, frequently deformed ears), cryptia (ear cartilage partially hidden under the skin), and preauricular sinuses and remnants are examples of abnormalities (Bhatti et al., 2021).

Microtia is a combination of the terms micro (tiny or small) and otia (ear). Microtia is an auricle deformity characterized by mild to severe abnormalities ranging from small to non-existent (anotia). Microtia is a congenital ear disease in which the auricle is smaller than usual in size. Microtia might be bilateral or unilateral, and the external acoustic meatus may be atresia. This congenital condition is caused by a Meckel's cartilage growth deficiency in the I branchial arch. The condition manifests itself as impaired pina growth, resulting in an extremely small and abnormally shaped outer ear (Milyantono & Artono, 2015).

Microtia is still poorly understood since the actual etiology of the disorder has not been identified, despite the fact that there are various irregularities that can be linked to the emergence of microtia and anotia. Brachial arch deficits (36.5%), facial nerve weakening (15.2%), cleft lip (4.3%), urogenital defects (4%), cardiovascular

diseases (2.5%), and macrostomia (2.5%) are the most prevalent anomalies related with microtia (Park, 2012). Microtia and anotia exist independently, while being associated with numerous diseases. The majority of instances are unilateral, with the right side being more frequently affected, while boys are affected at a 30% higher rate than girls. The Andes, Native Americans, Asians, and Hispanics have the highest occurrence (Bly et al., 2017). Microtia risk factors include low birth weight and acute maternal illness, in addition to ethnicity and male gender. Teratogen exposure in utero, such as thalidomide and retinoids, is closely linked to microtia. Increased folate consumption during pregnancy has been shown to lessen the occurrence of microtia (van Nunen et al., 2014). The precise mechanism for the formation of microtia is still being studied.

Microtia reconstruction is one of the most difficult procedures to perform in the field of reconstructive plastics. The results of ear repair with autologous rib cartilage or polyethylene are still not as appealing as auricles with prostheses. Autologous rib cartilage is still the gold standard for ear repair today. Several innovative procedures, such as the utilization of alloplastic implants, prostheses, and tissue expanders, have been created. Ear reconstruction involves four surgeries, with a minimum gap of six months between each, for a total time of two years (Widodo et al., 2018).

Wang et al. (2019) reported that PLEC, USH2A, FREM2, DCHS1, GLI3, POMT1 and GBA genes were found and significantly associated with severe microtia-atresia. This is why that we can prove that microtia can be caused by genetic. At the beginning of the discussion it was mentioned that microtia has many risk factors. Other genetic study from Zhao et al., (2019) about polymorphism, rs3135718-GG mutation was more correlated with the risk of microtia in male but not in female. The rs3135718-G gene in FGFR2 has a certain association with the incidence of congenital microtia with high prevalence and risk. Chen et al (2022) reported that patients with microtia have different metabolites with control. The cell model of microtia had significantly higher levels of TG, PC,

glycerophosphoethanolamine (PE), sphingomyelin, sulfatide, glycerophosphoglycerol, diacylglycerol, and glycosphingolipid.

Microtia Treatments

There are several kinds of treatment to treat ear abnormalities. There are several cases where ear disorders can heal without treatment, but most cases require surgical or non-surgical treatment to restore the shape and function of the affected ear. There are several techniques for treating ear disorders including splinting techniques and ear shaping, and surgery. Some of the techniques above are quite effective in dealing with congenital ear disorders with the main goal being able to restore the aesthetic, psychological and functional functions of the ear (Bhatti et al., 2021). Treatment of ear disorders can be initiated depending on the patient's psychological and physical factors. Ideally treatment is done before the child enters school. However, surgery can only be performed at a minimum age of 6 years, but there are also several sources that suggest surgery at the age of 10 years.

Microtia is the term used for an external ear with absent skin or cartilage that is small, collapsed, or only has an earlobe present. Microtia can occur as an isolated birth defect (the most common presentation), as a part of a spectrum of anomalies, or as a component of a syndrome. Treatment of microtia includes restoration of hearing function and reconstruction of the outer ear. (Schultz et al., 2017). In the treatment required cooperation between doctors between fields. This ear disorder can be detected from the time the baby is born, from the time the baby is born a hearing examination must be carried out immediately. The examination carried out is an examination of the auditory brainstem response. This is done to check the function of the inner ear. If abnormalities are found, it is necessary to consult with a surgeon as soon as possible so that a good cooperation can be obtained between the treating doctor and the patient's family. This surgery is called autologous reconstruction where the material used is

cartilage from the patient's ribs. Apart from surgery, there are techniques in treating ear deformities, especially in babies.

Non-surgical treatment is usually performed on patients who have cryptotia (Hidden Ear) deformity of the outer ear. This non-surgical technique has several advantages such as hematoma, scar tissue, and is usually more affordable. This non-surgical technique can have good results if the treatment is carried out immediately after the baby is born a maximum of 3 days after birth and continues to be used until the baby is 3 months old. This is because on day 3 the hormones estrogen and hyaluronic acid in the connective tissue have the highest levels and decrease with age. So that when the baby is 3 years old, the baby's ears can still be formed and will change according to the pattern made. 2 In babies who are born prematurely, it will take a longer waiting time before this treatment can be carried out.

The treatment that is usually done is to pull the ear of the newborn so that it has a good shape. This technique has been used since 1980. Ear splints generally have to be lightweight, inexpensive, easy to make, can be shaped into the shape needed, easy to install and remove (Schonauer et al., 2011). In general, splinting is done for 4-6 weeks. Complaints that usually occur are quite mild, namely skin irritation around the splint affixed. Apart from splinting, there is also treatment using a rigid mold called the Earwell Infant Corrective System. There are several studies that say treatment using this system has more satisfactory results than treatment using other splinting devices (Byrd et al., 2012).

Conclusion

According to the findings of this literature review, microtia is an outer ear condition in which a little loss of skin or cartilage forms, falls away, or only the ear canal is present. Microtia treatment comprises restoring hearing ability and reconstructing the outer ear.

References

- Bhatti, S.L., Daly, L.T., Mejia, M. & Perlyn, C. (2021a). Ear abnormalities. *Pediatrics in Review*, 42(4), 180-186. <https://doi.org/10.1542/pir.2019-0167>
- Bly, R.A., Bhrany, A.D., Murakami, C.S. & Sie, K.C.Y. (2016). Microtia Reconstruction. *Facial Plastic Surgery Clinics of North America*, 24(4), 577-591. <https://doi.org/10.1016/j.fsc.2016.06.011>
- Byrd, H.S., Langevin, C.J. & Ghidoni, L.A. (2010). Ear molding in newborn infants with auricular deformities. *Plastic and Reconstructive Surgery*, 126(4), 1191-1200. <https://doi.org/10.1097/PRS.0b013e3181e617bb>
- Chen, S.-J., Zhang, H.-S., Huang, X.-P., Li, W.-H., Liu, Y. Fan, C. ... & Zheng, Y.-J. (2022). Metabolomic characterization of congenital microtia: a possible analysis for early diagnosis. *Annals of Translational Medicine's*, 10(24), 1330. <https://dx.doi.org/10.21037/atm-22-5614>
- Marfatia, H., Priya, R., Sathe, N.U. & Shah, K. (2016). Congenital Anomalies Associated with microtia – Anotia: Review of 30 Cases. *Bangladesh Journal of Otorhinolaryngol*, 22(2), 78-83. <https://doi.org/10.3329/bjo.v22i2.45092>
- Milyantono, R.C. & Artono. (2015). Mikrotia. *Jurnal THT – KL*, 8(1), 46-53
- Park, S.S. (2012). Aural Atresia of the External Ear, Updated. Retrieved from <http://emedicine.medscape.com/article/845632-overview> Accessed June 10th 2014.
- Pu, W., Yibei, W., Xinmiao, F., Yaping, L., Yue, F., Tao, L., Chongjian, C., Shuyang, Z. & Xiaowei, C. (2019). Identification of sequence variants associated with severe microtia-astresia by targeted sequencing. *BMC Medical Genomics*. 12, 28. <https://doi.org/10.1186/s12920-019-0475-x>
- Schonauer, F., La Rusca, I. & Molea, G. (2009). Non-surgical correction of deformational auricular anomalies. *Journal of Plastic, Reconstructive & Aesthetic Surgery*, 62(7), 876-83. <https://doi.org/10.1016/j.bjps.2007.11.072>
- Schultz, K., Guillen, D. & Maricevich, R.S. (2017). Newborn Ear Deformities: Early Recognition and Novel Nonoperative Techniques. *Seminars in Plastic Surgery*, 42(2), 141-145. <https://doi.org/10.1055/s-0037-1603958>
- Schultz, K., Guillen, D. & Maricevich, R.S. (2017). Newborn Ear Deformities: Early Recognition and Novel Nonoperative Techniques. *Semin Plast Surgery*, 31, 141-145. <https://doi.org/10.1055/s-0037-1603958>
- van Nunen, D.P., Kolodzynski, M.N. & van den Boogaard, M.J. (2014). Microtia in the Netherlands: clinical characteristics and associated anomalies. *International Journal of Pediatric Otorhinolaryngol*, 78(6), 954-959.
- Widodo, D.W., Priyono, H. & Suryati, I. (2014). Penanganan Mikrotia Bilateral: Laporan Kasus Berbasis Bukti. *ORLI*, 44(1), 63-67. <https://doi.org/10.32637/orli.v44i1.84>
- Zhao, R., Du, P., Sun, H. & Yang, L. (2019). Pingzhen Lin' Fetal microtia and FGFR2 polymorphism. *Experimental and Therapeutic Medicine*, 18(1), 384-388. <https://doi.org/10.3892/etm.2019.7568>