



US and MR Findings in Primary Vaginal Leiomyoma: A Case Report

Paola Cramarossa^{1*}, Leonardo Resta², Arnaldo Scardapane³,
Doriana Scardigno¹, Maria Teresa Achilarré¹, Vera Loizzi¹
and Gennaro Cormio¹

¹Department of Gynecology, Gynecologic Oncology Unit, Obstetrics and Neonatology (DIGON), University of Bari, Bari, Italy. Azienda Consorziale Universitaria Policlinico di Bari, Piazza Giulio Cesare, 11. 70124 Bari BA, Italy.

²Department of Anatomopathology of University of Bari, Bari, Italy. Azienda Consorziale Universitaria Policlinico di Bari, Piazza Giulio Cesare, 11. 70124 Bari BA, Italy.

³Section of Diagnostic per Imaging, Di.M.I.M.P. University of Bari, Bari, Italy. Azienda Consorziale Universitaria Policlinico di Bari, Piazza Giulio Cesare, 11. 70124 Bari BA, Italy.

Authors' contributions

This work was carried out in collaboration between all authors. Author PC analyzed and interpreted the patient data regarding the tumoral disease and the surgical excision and was the major contributor in acquiring all the information needed and writing the manuscript. Author GC revised the manuscript critically for important intellectual content and gave final approval of the version to be published. Author LR performed the histological examination of the tumor. Author AS analysed the data coming from the imaging and selected the MR images. Authors MTA and DS gathered informations and US and CT images from the patient, and performed the follow up. All authors read and approved the final manuscript.

Case Report

Received 12th March 2013
Accepted 23rd April 2013
Published 3rd May 2013

ABSTRACT

Aims: We present this case to improve medical knowledge about unusual presentation of leiomyomas and about the diagnostical findings of examinations settled down per rectal way. We provide images and stress the importance of differential diagnosis based on imaging.

Presentation of the Case: We report a case of a 26 years old nulliparous, with a leiomyoma developed on the posterior upper third of the vagina surgically removed. The patient came to our Unit with dysmenorrhea and menorrhagia and underwent physical

*Corresponding author: Email: dr_cramarossa@gmail.com;

examination and ultrasound scan. Both exams were executed per transrectal way because of her being a virgo. A Computed Tomography scan has been executed too. All the results pointed out the presence of a round-shaped, well delimited, solid mass in posterior vaginal wall. Magnetic Resonance confirmed this diagnosis.

Discussion: We widely discuss the symptomathologic cortege, the diagnostic iter based on imaging we settled down, the possible differential diagnosis, and surgical therapy performed. Concordance of imaging, negativity of tumor markers and general well-being status of the patient led to the diagnostical hypotesis of vaginal benign neoformation. These data excluded other diagnosis as endometriosis, uterine fibroma, primitive vaginal malignant tumor and metastasis of other-site primitive malignant neoplasia. The patient has been treated by surgical transvaginal excission therapy.

Conclusion: US imaging and MR gives us the possibility to recognize a mass and to discern his nature and localization, thus to choose the best therapy in each case. Hystopathology still represent the gold standard in making a diagnosis in gynaecological oncology.

Keywords: Leiomyoma; vaginal tumors; RM imaging; US; rare neoplasias.

ABBREVIATION

US: Ultra Sound; MR: Magnetic Resonance; CT: Computed tomography; 2D: Two Dimension; EE: Ematossilin-Eosin.

1. INTRODUCTION

Leiomyomas are smooth muscle benign tumors developing from monoclonal expansion of a single muscle cell, responsive to steroid hormones. Leiomyomas easily occur in women over 35 years old in uterine wall [1]. We report a case of a 26 years old woman with leiomyoma located in vagina. Since the first report by Denys de Leyden in 1733, approximately 300 cases of vaginal leiomyoma have been reported worldwide [2]. Differential diagnosis in these cases must be done with benign neoplasms such as bladder leiomyoma, rhabdomyoma and benign mixed tumor, endometriosis, malignant primary neoplasms such as squamous cell carcinoma, verrucous and clear cell carcinoma, embryonal rhabdomyosarcoma, melanoma, leiomyosarcoma and mixed tumors, secondary neoplasms, cervical fibroid and uterine prolapsed [2]. Similar cases are reported in literature. In 2008 Costantini managed a patient with symptoms like dyspareunia, dysmenorrhea and foul-smelling vaginal discharge [3]. In 2009, Hubert defined MR standard to suspect a leiomyoma in a vaginal mass [4]. Levens, Elsayes and Scialpi analysed MR role in the diagnostical iter of vaginal masses and pointed out superiority of MR respect US scan to define all aspects of the pathology [5,6,7]. Sørensen and Torreggiani underline the importance of translabial US and MR scan [8,9]. We present this case for its clinical peculiarities: anomalous location of the tumor, diagnostic process settled down in a virgo, importance of a proper imaging data set to come to a clear diagnosis.

2. PRESENTATION OF CASE

A 26 years-old woman, nulliparous and virgo, came to our Unit complaining dysmenorrhea and menorrhagia. Symptoms started with post-menstruational spotting progressively gravescent till frank vaginal bleeding associated with dysmenorrhea. She had not

dyschezia , urinary symptoms and pelvic pain. Her previous medical history was negative. Physical examination and ultrasound scan were performed per rectal way because of her being a virgo. The patient strongly refused to undergo digital examination per vaginal way. Only rectal physical examination was performed. The patient was referred to us by an outside general physician. She arrived to our attention with a CT scan performed in a private Centre. We performed a MR scan. Rectal examination allowed palpation at third mid of vagina of a 3 cm-diameter, fixed, stretched-elastic tumefaction. Palpation induced moderate vaginal bleeding. To US scan, uterus appears antiversus of normal dimension and shape and position. Homogeneous echo structure. Secretive endometrium. Both ovaries appear normal for site, dimension and echostructure, in accordance to the age of the patient. No free fluid in Douglas pouch. By transrectal and transabdominal way, in the upper third of vagina, we detect a regular walled, solid neoformation; dimensions: 44x40 mm; inhomogeneous echostructure. Color Doppler examination indicates modest periferic vascularization. To probe-induced movement, the mass results fixed to posterior vaginal wall, but mobile respect bladder and rectal walls. This echographic panel strongly suggests a lesion of vaginal origin. Fig. 1. A-B.

CT (with and without m.o.c.) reported a 44mm, round, regular-margin formation opposite to uterine cervix, hyperdense with sovrafluid central density, adhere to uterus and bladder, without infiltration of these organs and none clivage plan.

Tyroids echostructure and functionality were tested and resulted normal. Tumor markers were negative.

MR confirmed what reported with ultrasound scan and pointed out the presence of a round-shaped solid neoformation, 55mm diameter, at postero-lateral vaginal wall, discreetly vascularized. The lesion dislocates anteriorly the posterior wall of urinary bladder and keeps contact with rectum anterior wall. No other pelvic abnormalities had been detected, slight pelvic effusion in Douglas pouch. Fig. 2. (a,b,c,d).

All data indicated an operable vaginal mass that caused genital bleeding and no clues of uterine involvement or dysfunction.

The preoperative diagnosis was settled as "paravaginal tumefaction". The patient underwent surgical procedure to enucleate the swelling. The surgical procedure included hymenectomy and biopsy of the specimen with intraoperative impromptu hystological examination and enucleation of the neoformation. High attention was paid to ureters and bladder wall; there was no infiltration of these structures. The mass was so well delimited from near organs to be enucleated completely without injuring other tissues. No post-surgical complications occurred.

Intraoperative examination showed a mesenchimal neoformation of the third middle of the vagina consisting in monomorpe round elements with finely dispersed cromatin and micronucleola, with no evidence of mytotic figures. The specimen was then sent to our Department of Hystopathology that described macroscopically an irregular -shaped, pseudocapsulated, whitish neoformation of 4,5x4,5x3 cm, partially covered by ulcerated mucosa.

FIG. 1A.

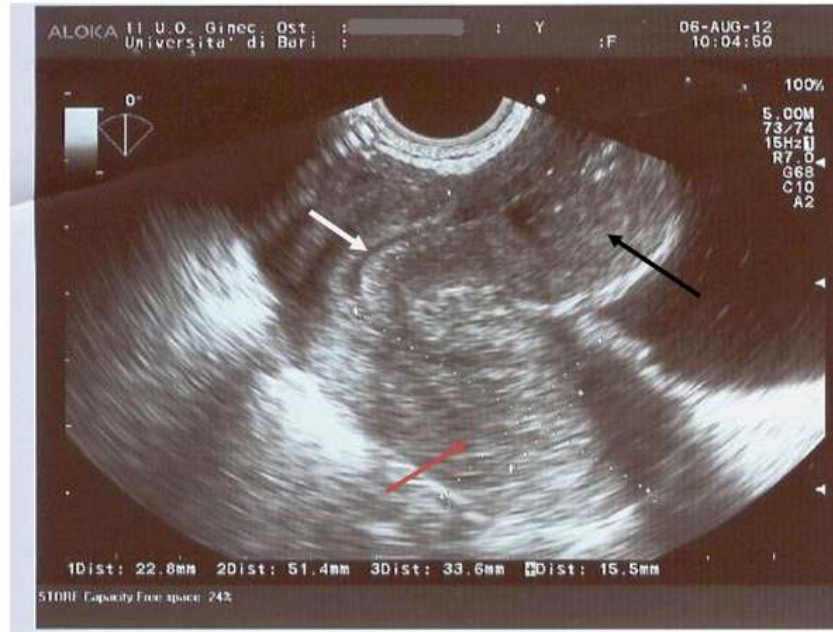

FIG. 1.B

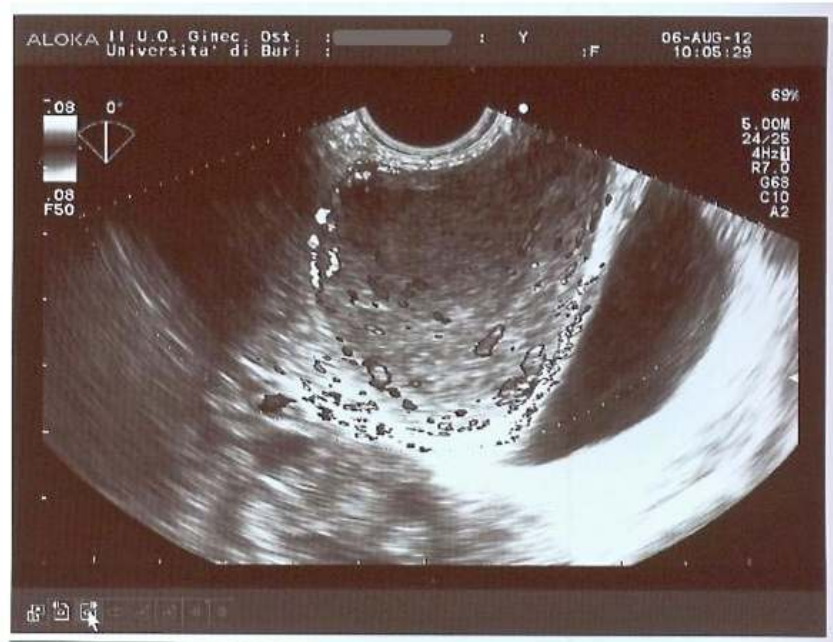

Fig. 1. A: Transrectal 2D Ultrasonographic scan showing uterus (red arrow), vagina (white arrow) and the hyperechogenic inhomogeneous mass (black arrow). B: Transrectal ultrasound doppler of the mass showing peripheral vascularization

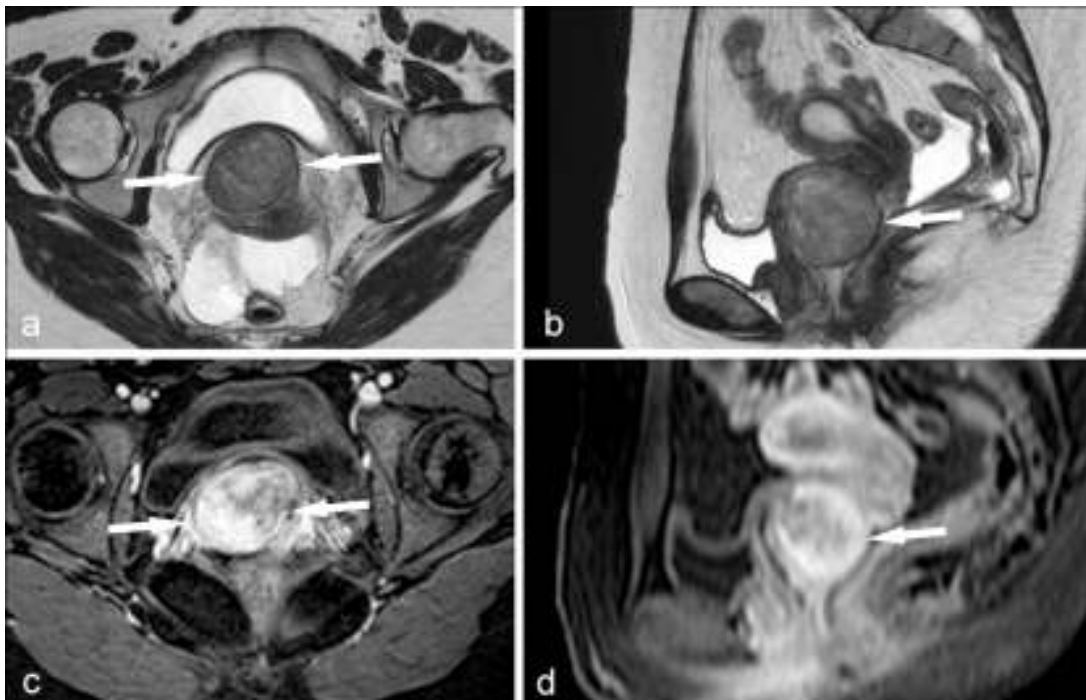

Fig. 2. MR of pelvis. TSE T2 axial (a) and sagittal (b) images. Voluminous, round-shaped well delimited formation at posterior vaginal fornix occupies a large part of vaginal lumen (arrows). Axial (c) and sagittal (d) THRIVE images after m.o.c. . Neof ormation shows intense and disomogeneous vascular enhancement (arrows)

Microscopically it was a cellular leiomyoma of the vagina arising on vaginal adenosis with ulceration of mucosa. Immunohistochemical reaction was positive for desmine and smooth muscle actine, negative for ck-pool, CD34, S100, HMB45. Ki <5%. Fig. 3A & 3B.

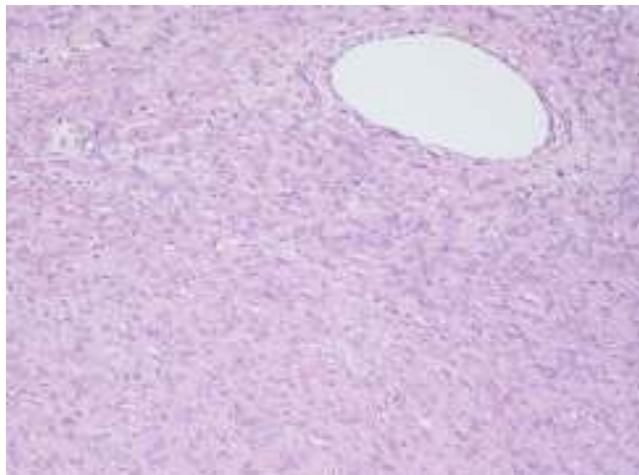


Fig. 3A. 10x. EE. Tumoral mass: well differentiated and organized smooth muscle cells, no mitosis, no abnormalities

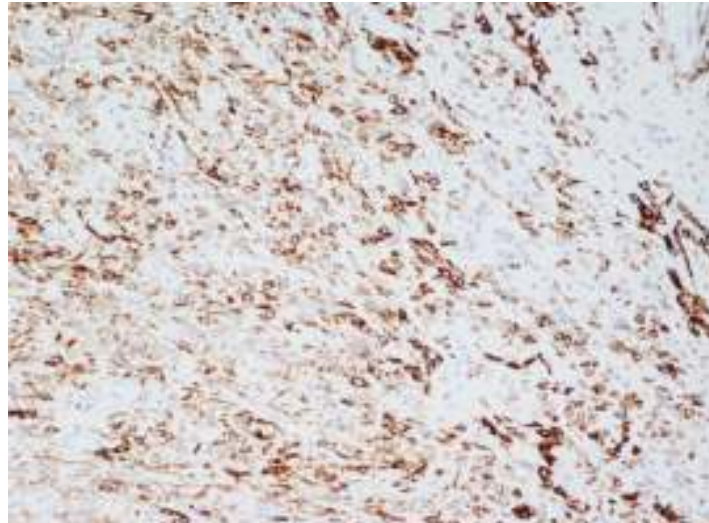


Fig. 3B. 10x. Desmin

As regards follow-up, we arranged appointments with the patient every 4 months. First echographic and physical control was performed 4 months after surgery and showed no recidive of the tumor nor sequelae. The patient denied any health problem. Second control was negative too. We keep the patient under observation nowadays.

3. DISCUSSION

Leiomyomas usually cause symptoms like vaginal bleeding, dysmenorrhea, dyslocation of lower urinary tract and urinary symptoms, lower back pain and feeling of heaviness in the lower abdomen, depending on the volume and position of the mass. Our patient presented to our Department complaining dysmenorrhea and menorrhagia.

Diagnostic process in such cases should be physical examination, basic blood tests and tumor markers, US scan as first level imaging and MR scan as second level, hystopathological analysis. In this case we performed all these tests and invasive examinations have been performed per rectal way because the patient was a virgo.

Physical examination depicted the presence of a pelvic mass but could not give information on its origin or nature. US scan gave us many important informations as a first level imaging. A translabial US scan has been performed too, as literature advices [9], but the imaging we acquired was not very significant because of the position of the mass (upper third of vagina). Here we present the transrectal US report, much more significative. US imaging clarified the localization of the mass; its echostructure allowed to assess a solid nature, so excluding a cystic disorder, dimensions and generic morphology.

CT scan, performed in another Centre, revealed shape, absence of a proper capsule, lack of necrosis, haemorrhage and calcification within the body. Diagnosis was currently oriented toward tumoral neoformation and all imaging suggested genital provenance and benign nature.

MR clarified vaginal genesis of the neoformation, posterior wall. Developing, the mass occupied all vaginal space dislocating posterior bladder wall.

Nature of symptoms, negativity of tumor markers and imaging allowed to exclude the diagnosis of a malignant tumor. On these elements, elective therapy choice has been surgical excission per transvaginal way. The specimen was sent to the Department of Pathology of University in Bari for hystopathological and immunohystochemical analysis: presence of smooth muscle actine filaments and desmine depository in cells were assessed and malignancy was escluded. The outcome poited out the mesenchimal nature of neoformation on vaginal adenosis, depicting the diagnosis of a vaginal leiomyoma. Transvaginal abscission and enucleation is the treatment of choice [10], as performed in this case, but sometimes severe haemorrhage can occur. If the base of the mass is not easily approachable, it is advisable to choose abdominal route. Following up this patients after surgery is very important because this kind of tumor, despite benign, can reurr after some time, rarely malignant evolution towards leiomyosarcoma is possible, so abscission in strongly recommended [11,12].

4. CONCLUSION

We present this case because of its clinical peculiarities. First of all, the patient came to our observation with a slight and generic gynaecological symptomatology that could not bring to a rapid solution of the case. The mass aroused from posterior wall of the vagina, not anterior as usually happens [2]. Second, the patient was a virgo and thus all invasive examination had to be performed per rectal way in the diagnostical phase. Then, we gathered a wide range of images to dispel every doubt about differential diagnosis. In such rare cases of benign mesenchimal tumors, excluding the possibility of a malignant or aggressive disease has primary importance. Hystopathology confirms is terminal role in clarifying any possible doubt. We hope this article could improve scientific knowledgment on this fascinating chapter of clinical gynecological practice.

CONSENT

All authors declare that written informed consent was obtained from the patient for publication of this case report and accompanying images.

ETHICAL APPROVAL

Not applicable.

ACKNOWLEDGEMENTS

We want to thank Prof. Vera Loizzi, Prof. Gennaro Cormio and Prof Luigi Selvaggi who allowed this team to perform this work.

COMPETING INTERESTS

The authors declare that they have no competing interests.

REFERENCES

1. Nel CP, Tiltman AJ. Eight cases of leiomyoma of vagina. S. Afr. Med. J. 1978;11(54):816-817.
2. Young SB, Rose PG, Reuter KL. Vaginal fibromyomata: Two cases with preoperative assessment resection and reconstruction. Obstet Gynecol. 1991;78:972-974.
3. Costantini E, Cochetti G, Porena M, Vaginal para-urethral myxoid leiomyoma: case report and review of the literature. Int Urogynecol J Pelvic Floor Dysfunct. 2008;19(8):1183-5. doi: 10.1007/s00192-008-0588-9. Epub 2008 Mar 20.
4. Hubert KC, Remer EM, Rackley RR, Goldman HB. Clinical and magnetic resonance imaging characteristics of vaginal and paraurethral leiomyomas: can they be diagnosed before surgery? BJU Int. 2010;105(12):1686-8. doi: 10.1111/j.1464-410X.2009.09046.x. Epub 2009 Nov 4.
5. Levens ED, Wesley R, Premkumar A, Blocker W, Nieman LK. Magnetic resonance imaging and transvaginal ultrasound for determining fibroid burden: implications for research and clinical care. Am J Obstet Gynecol. 2009;200(5):537.e1-7. doi: 10.1016/j.ajog.2008.12.037. Epub 2009 Mar 9.
6. Elsayes KM, Narra VR, Dillman JR, Velcheti V, Hameed O, Tongdee R, Menias CO. Vaginal masses: magnetic resonance imaging features with pathologic correlation. Acta Radiol. 2007;48(8):921-33.
7. Scialpi M, Benagiano G, Frati S, Pisciole I, Barberini F, Lupattelli L. Magnetic resonance imaging features of myxoid leiomyoma of the vagina: A case report. Indian J Radiol Imaging. 2009;19(3):238-41. doi: 10.4103/0971-3026.54880.
8. Sørensen M, Chauhan P. Leiomyoma can also be located in the vagina. Ugeskr Laeger. 2011;173(21):1510-1.
9. Torreggiani W, Zwirowich C, Lyburn I, Harris A, Davis JE, Wilkie D, Fenster H, Marchinkov L. Translabial sonography of vaginal fibroids: report of two cases and review of the literature. J Ultrasound Med. 2001;20(8):909-13.
10. Castle WN, McLaughlin WL. Paraurethral vaginal leiomyoma. Journal of the Medical Association of Thailand 1987;30:70-2.
11. Qian J, Zheng F, Shi Y, Clinical analysis of 25 cases of leiomyoma of the vagina. Zhonghua Fu Chan Ke Za Zhi. 2001;36(3):156-8.
12. Daliwhal LK, Das I, Gopalan S. Recurrent Leiomyoma of the vagina. Int Gynaecol Obstet. 1992;37(4):281-3.

© 2013 Cramarossa et al.; This is an Open Access article distributed under the terms of the Creative Commons Attribution License (<http://creativecommons.org/licenses/by/3.0>), which permits unrestricted use, distribution, and reproduction in any medium, provided the original work is properly cited.

Peer-review history:

The peer review history for this paper can be accessed here:
<http://www.sciencedomain.org/review-history.php?iid=205&id=12&aid=1349>