

A Rare Complication in a Peritoneal Dialysis Patient: Hydrothorax in Late Period

¹Tamer Selen  ²Çise Tüccar  ³M. Deniz Ayli 

1.Düzce Atatürk State Hospital, Nephrology Department, Düzce, Turkey

2.Health Sciences University, Department of Chest Diseases and Tuberculosis, Diskapi Yildirim Beyazit Education and Research Hospital, Ankara, Turkey

3.Health Sciences University, Ankara Etlik City Hospital, Nephrology Department, Ankara, Turkey

Corresponding author: Tamer Selen, Düzce Atatürk State Hospital, Nephrology Department, Düzce, Turkey. E-mail: tamer_selen_@hotmail.com

Cite this article: Selen T, Tüccar Ç, Ayli MD. A rare complication in a peritoneal dialysis patient: Hydrothorax in late period. *J Eur Int Med Prof.* 2023;1(2):54-56.

This is an open-access article distributed under the terms of the Creative Commons Attribution License (<https://creativecommons.org/licenses/by/4.0/>).

See <http://www.jeimp.com> for full terms and conditions.

Received: 27.12.2022 Accepted: 03.01.2023 Published: 27.01.2023

ABSTRACT

Peritoneal dialysis (PD) associated hydrothorax is a rare complication caused by leakage of dialysis fluid from the peritoneal cavity into the pleural space. The typical clinical presentation is a right-sided pleural effusion and patients present with sudden chest pain, shortness of breath, and loss of ultrafiltration. The fluid is usually transudate. Chow gradient [pleural fluid glucose concentration - serum glucose concentration] > 50 mg/dL supports the diagnosis. It usually occurs in the first few months after the onset of PD in cases with congenital diaphragmatic defects or lymphatic drainage disorders. In patients with clinical conditions that increase the pleuroperitoneal pressure difference, such as constipation, may also occur in later periods, as in the case we presented. A 53-year-old male patient presented with chest pain and shortness of breath in the 10th month of PD treatment. A diagnosis of "PD-associated hydrothorax" was made with transudative pleural effusion in the right hemithorax and high a Chow gradient. In this case, increased pleuro-peritoneal pressure difference due to constipation that has been going on for several weeks was evaluated in favor of a late hydrothorax clinic.

Keywords: Peritoneal dialysis, pleural effusion, hydrothorax

INTRODUCTION

Peritoneal dialysis (PD) associated hydrothorax is a rare complication caused by leakage of dialysis fluid from the peritoneal cavity into the pleural space and was first described by Edward and Unger in 1967 (1). Cases due to congenital diaphragmatic defects or lymphatic drainage defects occur predominantly in the right hemithorax and usually within the first few months after the onset of PD (In more than 50% of cases within the first three months) (2,3). On the other hand, sudden coughing attacks, constipation, tight clothing, and an increase in intra-abdominal fluid volume may also lead to the development of hydrothorax even in later periods through an increased pleuro-peritoneal pressure difference (4,5).

Hydrothorax may be completely asymptomatic or result in pleuritic chest pain, shortness of breath, and loss of ultrafiltration.

In this article, we present a case of PD who applied with chest pain and shortness of breath at the 10th month of PD treatment and was diagnosed with PD -related

hydrothorax in the late phase.

CASE

A 53-year-old man was admitted to our emergency department with increasing shortness of breath and right chest pain. Blood pressure was 100/75 mmHg, body temperature was 36°C, heart rate was 96 beats/minute, respiratory rate was 20/minute, and oxygen saturation on room air was 95%. There was no pretibial edema on physical examination. Breath sounds and chest vibration were decreased; percussion was dull in the lower right lung segments. Laboratory findings: urea: 89 mg/dL, creatinine: 7.02 mg/dL, albumin: 3.9 g/dL, hemoglobin: 11.7 g/dL, white blood cell count: 8800/mm³, C-reactive protein: 9.05 mg/dL. On anteroposterior chest X-ray, the increased density in the lower right lung area was evaluated as pleural effusion (**Figure 1A**), and he was hospitalized.

Peritoneal dialysis was started 10 months ago with a diagnosis of chronic renal failure due to arterial hypertension. Because of good residual renal function,

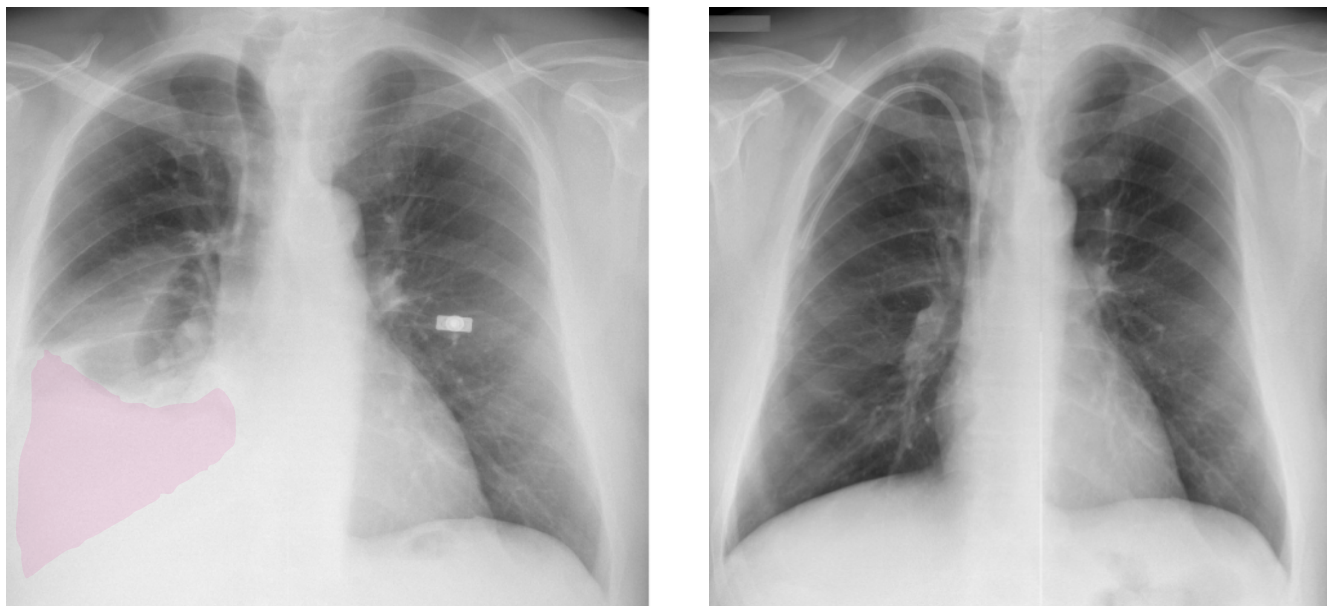


Figure 1. A) Right pleural effusion on chest X-ray is illustrated, B) Chest X-ray at the end of 1st week. .

he was prescribed nocturnal intermittent peritoneal dialysis with a cycler. He performed 4 night cycles with an inflow volume of 1900 ml with a lactate-buffered dialysis solution containing 1.36% glucose. The peritoneal membrane had a high average permeability, and there were no problems with adequacy parameters.

The patient has been suffering from constipation for several weeks. Last week's records indicated a decrease in ultrafiltration volume of 100-300 ml/day. The patient has no known pre-existing heart failure. Diagnostic thoracentesis in the right hemithorax revealed 70 leukocytes and 50 erythrocytes in the straw-coloured fluid. There was no growth in culture and no malignant cells in cytology. The fluid was transudative according to Light criteria (**Table 1**). The Chow gradient [glucose concentration in pleural fluid (665 mg / dL) - serum glucose concentration (131 mg / dL)] was calculated to be 534 mg/dL. The high chow gradient (> 50 mg/dL) supported the diagnosis of hydrothorax associated with PD and PD was suspended. One week after starting hemodialysis, the dyspnea resolved completely, and the effusion disappeared on chest X-ray (**Figure 1B**). The patient did not want to continue PD and refused diagnostic procedures such as scintigraphic examination. The PD catheter was removed and a maintenance hemodialysis program was initiated.

DISCUSSION

This article presents a relatively late case of hydrothorax associated with PD. It was suspected that the increase in intra-abdominal pressure due to constipation, which persisted for several weeks, led to the development of PD-related hydrothorax in the late phase.

Our patient was diagnosed on the basis of the results of physical examination, chest X-ray findings, and biochemical analysis of the fluid. The detection of transudative fluid with high glucose content is very important for the diagnosis. A glucose concentration in pleural fluid greater than 300 mg/dL or a Chow gradient greater than 50 mg/dL is diagnostic of PD-associated hydrothorax (6). The Chow gradient in this patient was calculated to be 534 mg/dL.

Table 1. Simultaneous laboratory results of pleural fluid and serum sample.

	Serum	Pleural fluid
Serum glucose (mg/dL)	131	665
Lactate dehydrogenase (U/L)	232	5
Total protein (g/dL)	6.92	1.06
Albumin (g/dL)	3.96	0.05

Treatment of this complication should be planned according to the patient's clinical condition and preferences. In cases of congenital diaphragmatic defects, pleurodesis may yield positive results. On the other hand, in cases where increased intraperitoneal pressure is considered a priority, PD can be temporarily discontinued and then resumed with minor volume changes (7). This was also the primary planned approach in our case. It was assumed that pleuro-peritoneal leakage could be stopped after the constipation was relieved. However, the hemodialysis program was initiated because the patient did not want to continue PD.

CONCLUSION

Hydrothorax may develop at relatively late stages in PD patients, although rarely. While obvious congenital defects cause symptoms immediately after the onset of PD, some clinical factors may contribute to development at later stages. Awareness among clinicians will contribute to the correct diagnosis and management of such cases

DECLARATIONS

Acknowledgment: Not applicable

Ethics Committee Approval Number: Not necessary

Informed Consent: Not necessary

Referee Evaluation Process: Externally peer-reviewed

Conflict of Interest Statement: Authors declare no conflict of interest.

REFERENCES

1. Edwards SR, Unger AM. Acute hydrothorax---a new complication of peritoneal dialysis. *JAMA*. 1967;199(11):853-855.
2. Nomoto Y, Suga T, Nakajima K, et al. Acute hydrothorax in continuous ambulatory peritoneal dialysis--a collaborative study of 161 centers. *Am J Nephrol*. 1989;9(5):363-367. doi:10.1159/000167997
3. Momeni N, Colletti PM, Kaptein EM. Low pleural fluid-to-serum glucose gradient indicates pleuroperitoneal communication in peritoneal dialysis patients: presentation of two cases and a review of the literature. *Nephrol Dial Transplant*. 2012;27(3):1212-1219. doi:10.1093/ndt/gfr393
4. Lew SQ. Hydrothorax: pleural effusion associated with peritoneal dialysis. *Perit Dial Int*. 2010;30(1):13-18. doi:10.3747/pdi.2008.00168
5. García Ramón R, Carrasco AM. Hydrothorax in peritoneal dialysis. *Perit Dial Int*. 1998;18(1):5-10.
6. Chow KM, Szeto CC, Wong TY, Li PK. Hydrothorax complicating peritoneal dialysis: diagnostic value of glucose concentration in pleural fluid aspirate. *Perit Dial Int*. 2002;22(4):525-528.
7. Moreno A, Suria S, Pérez-Valentín MA, et al. Hydrothorax in peritoneal dialysis. Effective treatment with pleurodesis. *Perit Dial Int*. 1998;18(6):657-658.