Angiokeratoma of the vulva

E. Terzakis[1], G. Androutsopoulos[2], D. Zygouris[1], C. Grigoriadis[1], G. Derdelis[1], N. Arnogiannaki[3]

[1]2nd Department of Gynaecology, St. Savvas Anticancer-Oncologic Hospital, Athens,
[2]Department of Obstetrics and Gynaecology, Amfissa General Hospital, Amfissa,
[3]Department of Pathology, St. Savvas Anticancer-Oncologic Hospital, Athens (Greece)

Summary

Angiokeratoma of the vulva is relatively uncommon in the general population. We present two cases of angiokeratoma of the vulva and review the literature. The two patients presented with the complaint of vulvar pruritus. They underwent wide local excision of the lesions. Histopathology revealed angiokeratoma of the vulva. The women remain well with no evidence of recurrence 48 and 32 months after initial surgery. Although it is a rare disease, angiokeratoma of the vulva should be included in the differential diagnosis of a vulvar tumor.

Key words: Vulvar angiokeratoma; Treatment.

Introduction

Angiokeratoma of the vulva is an uncommon benign cutaneous lesion [1, 2]. Its etiology and pathogenesis remain unclear. Perhaps it is the result of dilation of ectatic thin-walled blood vessels and congested capillaries in the subdermal layer [3].

It generally occurs on the labia majora and rarely on the clitoris [1, 2]. It is easily confused with other benign and malignant tumors from which they must be differentiated by histological examination [1, 2]. We present two cases of angiokeratoma of the vulva and review the literature.

Case Report

Case 1

The patient, a 65-year-old, gravida 1, para 1, postmenopausal Greek woman presented with the complaint of vulvar pruritus. Her past surgical history was unremarkable. Her family history revealed no evidence of cancer among the first-degree relatives.

On gynecologic examination there was a bluish globular lesion 1.1 cm involving the left labia major. There were no palpable inguinal lymph nodes and the rest of the pelvic examination was normal.

The patient underwent wide local excision of the lesion. Histopathology revealed angiokeratoma of the vulva.

Follow-up 48 months after initial surgery showed no evidence of recurrence.

Case 2

The patient, a 69-year-old, gravida 2, para 2, postmenopausal Greek woman presented with the complaint of vulvar pruritus. Her past surgical history was unremarkable. Her family history revealed no evidence of cancer among the first-degree relatives.

On gynecologic examination there was a cherry red papular lesion 0.7 cm involving the right labia major. There were no palpable inguinal lymph nodes and the rest of pelvic examination was normal.

The patient underwent wide local excision of the lesion. Histopathology revealed angiokeratoma of the vulva.

Follow-up 32 months after initial surgery showed no evidence of recurrence.

Discussion

Angiokeratoma is a benign vascular lesion, characterized from ectatic dilatation of preexisting vessels of the papillary dermis accompanied by a hyperkeratotic epidermis [4]. Angiokeratoma of the vulva is relatively uncommon [1, 2]. It may affect women between 20 and 40 years of age (range 15-58 years) [1, 2]. There is no racial distinction [2]. It has been observed in both white and black women [1, 2, 5, 6].

Its etiology and pathogenesis remain unclear. Embryologically the labia majora and scrotum are derived from the labioscrotal swellings [2]. As they are homologues, the pathophysiology of vulvar and scrotal angiokeratoma is thought to be the same [1, 2, 7, 8].

Angiokeratoma of the vulva perhaps is the result of dilation of ectatic thin-walled blood vessels and congested capillaries in the subdermal layer [3]. Degenerative changes in the elastic tissue of the blood vessels appear to be important in the pathogenesis [1, 2]. These changes could result from a primary (congenital, idiopathic) or a secondary process (decreased nonstriated muscle support, increased venous pressure, chronic inflammation) [1, 2]. Pregnancy, hysterectomy, vulvar varicosities, hemorrhoids, inflammation and radiation have been presumed to be predisposing factors [1, 2, 7, 9, 10]. In our patients we could not find any predisposing factors.

It generally occurs on the labia majora and rarely on the clitoris [1, 2]. In most cases it is unilateral and located on the left side of the vulva [1, 2]. The lesions may be single or multiple (maximum 24 lesions) [1, 2, 11]. In our patients, the lesion was single and located on the labia majora.

The lesions usually measure between 2 mm and 10 mm in diameter and may assume a papular, globular or warty

Revised manuscript accepted for publication January 17, 2011

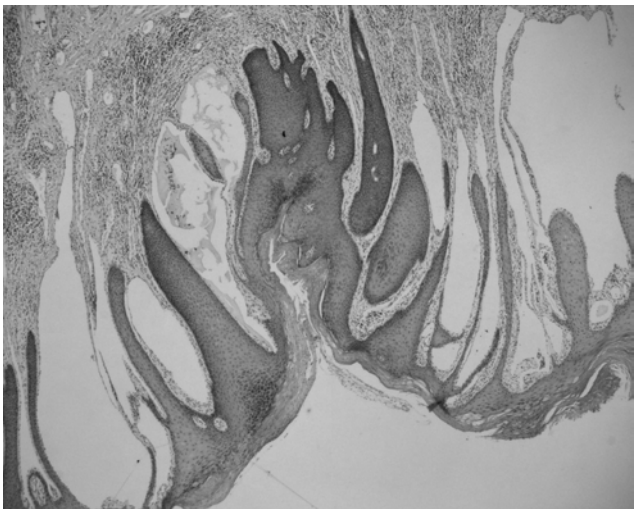

Figure 1. — Angiokeratoma of the vulva (x 40).

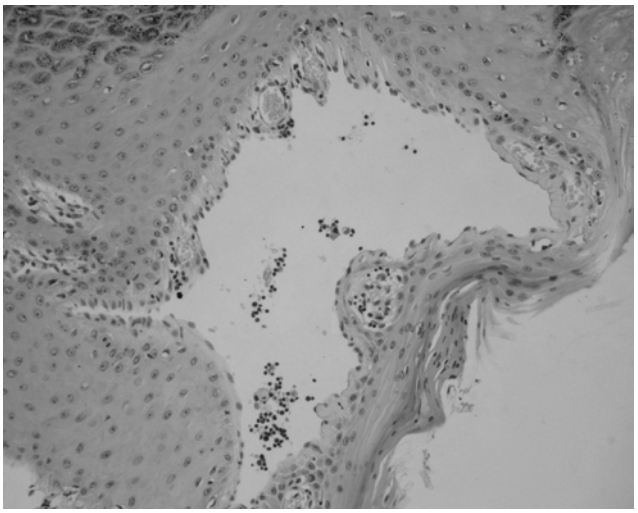

Figure 2. — Angiokeratoma of the vulva (x 200).

appearance [1, 2, 7, 11]. The earlier lesions are cherry red in color which become bluish or brownish as they increase in size and duration [1, 2, 7, 11, 12]. In our cases, one patient had a bluish globular lesion 1.1 cm and one patient had a cherry red papular lesion 0.7 cm in size.

Angiokeratoma of the vulva is usually asymptomatic [1, 2, 11]. The most common symptoms are intermittent bleeding (25%), vulvar pruritus (11%) and pain (9%) [1, 2, 6]. Frequently, patients complain of blood-stained underwear [1]. Patients with symptoms often seek medical attention sooner than those with asymptomatic lesions [1, 2]. Our patients presented with a complaint of vulvar pruritus.

Although the pathogenesis and clinical presentation vary, the histological features are similar for all lesions of angiokeratoma [3]. Histologically they characterized by dilated ectatic, blood-filled vascular spaces in the papillary dermis associated with acanthosis, hyperkeratosis and papillomatosis [1, 2, 3, 13]. Epidermal pathological changes seem to be a secondary reaction [3, 13].

Because of the varied clinical presentation, angiokeratoma of the vulva should be clinically differentiated from infectious (bacterial, viral), inflammatory, vascular and epithelial (benign, malignant) lesions [2, 7, 9].

In all patients the diagnosis must be confirmed by biopsy [2, 7, 13]. For patients with asymptomatic lesions reassurance with periodic follow-up is an adequate approach [2]. For patients with symptomatic lesions the therapeutic options are surgery (local excision, vulvectomy), electrosurgery and laser [2, 5, 7, 12-15]. Laser therapy has recently become the treatment of choice because it is less painful, causes minimal blood loss and cosmetically is much better, though the disease may recur more often compared to surgical excision [2, 12, 14, 15]. In our patients we performed wide local excision of the lesion.

Although it is a rare disease, angiokeratoma of the vulva should be included in the differential diagnosis of a vulvar tumor.

References

[1] Imperial R., Helwig E.B.: "Angiokeratoma of the vulva". *Obstet. Gynecol.,* 1967, *29,* 307.

[2] Cohen P.R., Young A.W. Jr., Tovell H.M.: "Angiokeratoma of the vulva: diagnosis and review of the literature". *Obstet. Gynecol. Surv.,* 1989, *44*, 339.

[3] Schiller P.I., Itin P.H.: "Angiokeratomas: an update". *Dermatology,* 1996, *193,* 275.

[4] Requena L., Sangueza O.P.: "Cutaneous vascular anomalies. Part I. Hamartomas, malformations, and dilation of preexisting vessels". *J. Am. Acad. Dermatol*., 1997, *37,* 523.

[5] Collins C.G., Hansen L.H., Theriot E.: "A clinical stain for use in selecting biopsy sites in patients with vulvar disease". *Obstet. Gynecol.,* 1966, *28,* 158.

[6] Verbov J., Manglabruks K.: "Angiokeratoma of vulva". *Dermatologica,* 1978, *156,* 296.

[7] Novick N.L.: "Angiokeratoma vulvae". *J. Am. Acad. Dermatol*., 1985, *12,* 561.

[8] Imperial R., Helwig E.B.: "Angiokeratoma of the scrotum (Fordyce type)". *J. Urol*., 1967, *98*, 379.

[9] Haidopoulos D.A., Rodolakis A.J., Elsheikh A.H., Papaspirou I., Diakomanolis E.: "Vulvar angiokeratoma following radical hysterectomy and radiotherapy". *Acta Obstet. Gynecol. Scand.,* 2002, *81,* 466.

[10] Smith B.L., Chu P., Weinberg J.M.: "Agiokeratomas of the vulva: possible association with radiotherapy". *Skinmed,* 2004, *3*, 171.

[11] Uhlin S.R.: "Angiokeratoma of the vulva". *Arch. Dermatol.,* 1980, *116,* 112.

[12] Dotters D.J., Fowler W.C. Jr., Powers S.K., McCune B.K.: "Argon laser therapy of vulvar angiokeratoma". *Obstet. Gynecol.,* 1986, *68* (3 suppl.), 56S.

[13] Yiğiter M., Arda I.S., Tosun E., Celik M., Hiçsönmez A.: "Angiokeratoma of clitoris: a rare lesion in an adolescent girl". *Urology,* 2008, *71,* 604.

[14] Oni G., Mahaffey P.: "Treatment of angiokeratoma of the vulva with pulsed dye laser therapy". *J. Cosmet. Laser Ther*. 2010, *12,* 51.

[15] Baruah J., Roy K.K., Rahman S.M., Kumar S., Pushparaj M., Mirdha A.R.: "Angiokeratoma of vulva with coexisting human papilloma virus infection: a case report". *Arch. Gynecol. Obstet.,* 2008, *278,* 165.

Address reprint requests to:
G. ANDROUTSOPOULOS, M.D.
Anaxagora 45
Ag. Paraskeui 15343 (Greece)
e-mail: androutsopoulosgeorgios@hotmail.com