International Journal of Computer Science and Information Security (IJCSIS),
Vol. 19, No. 5, May 2021

Computer Aided Diagnostic System for Diabetic Retinopathy Detection using Image Processing and Artificial Intelligence

Anitha T Nair
Department of CSE
FISAT
Ernakulam, India
anitha.mrt@fisat.ac.in

Arun Kumar M N
Department of CSE
FISAT
Ernakulam, India
akmar_mn11@fisat.ac.in

Anitha M L
Department of CSE
PES College of Engg.
Mandya, India
anithamuralikrishna@gmail.com

Anil Kumar M N
Department of ECE
FISAT
Ernakulam, India
mn_anilkumar@fisat.ac.in

***Abstract*—The number of individuals who develop Diabetic Retinopathy (DR) has increased significantly in recent years. Early detection and diagnosis is essential to prevent the vision loss. Ophthalmologist need to analyze mass retinal images to discover the anomalies, for example, spilling veins, retinal swelling(macular edema), greasy stores on the retina (exudates), and changes in the veins. Early detection of DR from retinal images is a challenging task. Medical image examination is the most effective method for diagnosis of DR. Computer Aided Diagnosis (CAD) systems, which can be used in clinical environments assists an ophthalmologist in diagnosing and detecting DR. This paper aims to investigate, the state of art regarding CAD for DR. The review focus on major techniques in image processing and data mining that are employed for developing a CAD system for DR. This survey also comes up with a common analysis of the current CAD system according to the employed modalities for DR diagnosis or detection. Future research works are discussed to develop efficient CAD systems for DR diagnosis or detection.**

Index Terms*— *Computer Aided Detection, Classification, Diabetic Retinopathy, Feature Extraction, Image Processing, Preprocessing.

I. INTRODUCTION

Diabetic Mellitus is a chronic disease caused due to excessive level of sugar content in the blood. It mainly affects kidneys, nerves, heart and minute blood vessels in the eyes[1]. DR is an eye disease, which can cause damage to the retina. A vascular eye disease will eventually cause blindness in people and can be of two types, Non-Proliferative DR (Early DR)[2] and Proliferative DR (Advanced DR). These days DR is a significant reason for visual impairment in individuals with diabetic. Therefore, constant eye check-up and timely treatment is required. However, the dearth of experts along with related higher medical prices makes regular check up pricey. To fill this opening, development of low cost CAD systems, which can be employed in clinical environments, have gained far more attentiveness in recent years.

*Address correspondence to this author at the Department of Computer Science and Engineering, Federal Institute of Science and Technology, Ernakulam-683577, India; E-mails: amrakmar.mn11@gmail.com

In this period, individuals with diabetic is more and ophthalmologist need to look at mass retinal pictures to discover the irregularities, for example, leakage of blood vessels, deformation of retina(macular edema) and small deposits known as exudates.Early detection of DR is a challenging task in ophthalmology. Most of the CAD systems use some computerized feature extraction and classification algorithms to detect DR. These can be a better tool or an intelligent diagnostic system for an ophthalmologist in detecting or diagnosing the DR[3]. Many efforts has been made to develop CAD systems, which are based on the breakthrough or advances in digital image processing, data mining techniques and pattern recognition. Development of a DR-CAD system[4, 5] is a tough task in the field of ophthalmology. Automatic detection systems were utilized different advances beginning with image processing technologies of retinal data[6] and upgraded to AI approaches such as machine learning and deep learning[7]. Optical coherence tomography and fundus image analysis[8] are mainly used as imaging techniques to draw out the characteristics associated with the retina in the diagnosis of various retinal diseases. Several methods were employed to develop CAD system that uses various datasets, feature vectors and different methodologies for classification[9-11]. Due to the technological development, numerous applications were suggested for the development of DR-CAD system. Earlier days CAD framework were employed with the support of image processing techniques for the mass screening of retinal images[1, 12]. Retinal images were segmented using segmentation algorithms, which will identify optic disc, blood vessels and fovea localization[13, 14] etc. Geometric relationship of different features and lesions can be used along with some morphological operations[15] to obtain a better framework for analyzing the retinal images. Image processing techniques can be effectively applied on retinal images for the effective segmentation[16]. Soft computing techniques[17] employ as a proficient method for the recognition of blood vessels in digital retinal images.

With the introduction of AI based approaches CAD system acquired more accuracy than the previous methods. Automatic detection systems for DR using machine-learning approaches given a new look to the CAD system[18]. Era of deep learning approaches[19, 20] provides desirable and improved results for the detection of DR. In the field of ophthalmology, application of deep learning algorithms in retinal imaging is an upcoming research area[21, 22]. Hybrid solution including image processing and AI approaches[23] is another versatile method for developing CAD system with good accuracy. Voets et. al.[24] overcomes the issues of deep neural network by incorporating new methodologies. .In this paper, we present some of the important methods, which have been employed in developing the CAD system for DR.

https://sites.google.com/site/ijcsis/
ISSN 1947-5500

A.List Of Abbreviations

AHE	Adaptive Histogram Equalization
AI	Artificial Intelligence
BDT	Binary Decision Tree
BPNN	Back Propagation Neural Network
CAD	Computer Aided Diagnosis/Detection
CLAHE	Contrast Limited Adaptive Histogram Equalization
CNN	Convolutional Neural Network
CUHK	Chinese University of Hong Kong
DNN	Deep Neural Network
DR	Diabetic Retinopathy
DWT	Discrete Wavelet Transform
FFT	Fast Fourier Transform
FIRE	Fundus Image Registration
GLCM	Gray Level Co-occurrence Matrix
HE	Histogram Equalization
LESH	Local Energy-based Shape Histogram
LPBPC	Local Property-Based Pixel Correction
LFSA	Local Feature Spectrum Analysis
LTP	Local Ternary Pattern
MA	Micro Aneurysm
NPDR	Non-proliferative DR
PDR	Proliferative DR
PNN	Probabilistic Neural Network
SERI	Singapore Eye Research Institute
SIFT	Scale Invariant Feature Transform
SVM	Support Vector Machine
STARE	Structured Analysis of Retina
QDA	Quadratic Discriminant Analysis

II. RELATED WORKS

https://sites.google.com/site/ijcsis/
ISSN 1947-5500

Many research works have been developed to improve the diagnostic accuracy of DR screening[30]. Xiao et.al.[10] presented an overview of the automatic screening systems such as Iowa DR, Tennessee Ocular Telehealth Network (OTN) etc. Our paper attempts to elaborate different life cycle stages and the various methodologies involved in each stage of the CAD system. [Fig. 1]. shows the life cycle stages of DR detection.

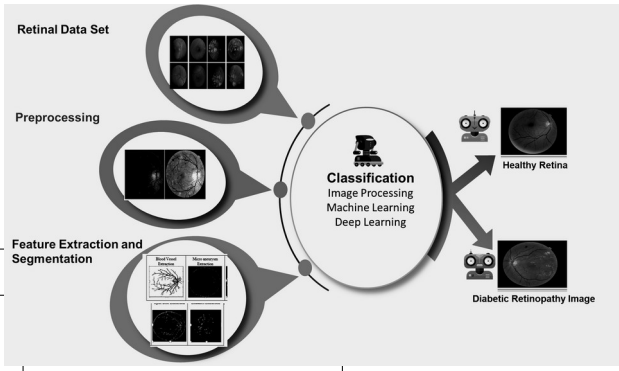

Fig. (1). Life Cycle Stages of DR Detection

A. Preprocessing of the Retinal Image

Preprocessing eliminates unwanted elements and defects from the images and resolves the problems of lighting, illumination, contrast and resolution. Preprocessing of images [31] will improve the quality of retinal images in further processing of a CAD system. Both early and modern CAD system adopted different approaches according to the requirement of the user. DR detection using image processing techniques uses different preprocessing methods to improve the quality of images. Gray scale conversion was performed in most of the images and image enhancement methods such as HE, AHE, and CLAHE were applied to it. Resizing the images to different dimensions and applying morphological operations really improved the performance of the system by reducing the processing time. Green channel extraction was performed to identify the prominent blood vessels in the retinal images. Different filtering methods including matched filter, median filter, Gaussian filter, sober filter and Gabour filter were used to reduce the noise.

Table 1. Details of available dataset.

Sl.No			Remarks
1		g various cameras.	Patients were selected from 15 National Health Service hospitals in the United Kingdom
2	DRIVE [14,21,99].	8 bits/color plane at 565 × 584 pixels.	40 fundus images with 33 typical normal images and 7 DR affected images.
3	STARE [14,21,45 ,66,79.	700 x 605 pixels.	20 retinal fundus images.
4	SERI, CUHK [22].	It was captured with a CIRRUS SD-OCT device.	128 cross-sectional scans with a resolution of 512 × 1, 024 pixels.
5	A2A SD-OCT (Duke dataset) [22].	1, 000 × 512 pixels.	384 SD-OCT volumes: 269 AMD and 115 control or normal eyes.
6	Retinopathy Online Challenge [25].	768 × 576, 1058 × 1061 and 1389 × 1383 pixels.	100 color image of the retina.
7	Messidor [26][36].	440 X960, 2240 X 1488, and 2304 X1536 pixels.	1200 images.
8	KAGGLE [27,98].	High-resolution fundus images.	It contains an aggregate of 35,126 fundus images.
9	E-Ophtha [28].	NA.	381 compressed images of which 148 have MAs presents and 233 depict healthy.
10	DIARETDB1[6][9]][28].	1500 x 1152 with 500 field of view (FOV).	28 training and 61 testing images captured at 50 ° FOV.
11	FIRE [29].	Utilizing a Nidek AFC-210 fundus camera with resolution of 2912 × 2912 pixels and 45 ° field of view (FOV).	Publicly accessible retinal image registration dataset with ground truth annotation.
12	CHASE.[14,79]	1280 X 960 pixels resolution.	28 images.

https://sites.google.com/site/ijcsis/
ISSN 1947-5500

In NPDR detection, Zhentao Gao et al.[32] discussed different techniques for preprocessing such as normalization, color decomposition, space conversion techniques and contrast enhancement. To extract the structural features from the data sets Chetoui Mohamed et al.[33] used gray scale conversion methods. Khoeun Ratanak, et al. proposed a method to detect micro aneurysm using modified matched filtering with an accuracy of 90.7%. Methodologies in[34] used matched filter and[35] used Gaussian filter as a preprocessing methods for enhancing the images. Morphological operation, binarization and histogram matching were used in[36] to enhance retinal images. Table 2 provides the main themes used in the preprocessing stage.

Table 2. Main themes in preprocessing techniques.

Sl. No	Techniques	Reference(s)
1	AHE, HE, and CLAHE.	[2, 6,15, 17,23,26,31,36 [42-44], [47-49], 55, [59-63], 66,68, 70, 71, 72,74, 77, 80, 81, 86, 88, 94]
2	Resizing.	[2, 13,19,21,23,31,39, 51, 54, 55,68, 73, 74, 88,100]
3	Normalization.	[2, 13,20,23,32,38,44,98]
4	Top-hat form filter. Matched filtering.	[8,75] [8,48,86]
5	Shaded correction.	[8, 15, 47, 77]
6	Spatial Normalization. Global Contrast Normalisation	[15] [14]
7	Green channel extraction.	[15-16,28,31,[37-41], 63,67, 68,71, 74, 86,92]
8	Local-phase method	[16]
9	Median filtering.	[15, 22,25,37,57,43, 47, 62, 66,67, 89, 97]
10	Color Normalization.	[25],[32][53, 54]
11	Gray scale conversion.	[17,26,44, [48-52] , 62, 70, 71, 80, 81, 89, 93]
12	Morphological Operation.	[28,36,38, 39, 42, 43, 59, 63, 80, 94]
13	Binarization, Image cropping, Erosion.	[36, 38, 59, 64, 81, 94]
14	Fuzzy filtering(Median filter), Fuzzy HE, Fuzzy edge detection.	[40, 93]
15	Canny edge detection.	[41, 55]
16	Intensity Inversion.	[42, 43]
17	Adaptive Weiner filter. Homomorphic filtering.	[43] [45]
18	DWT.	[44,48]
19	AM-FM Decomposition.	[46]
20	Gabor filter.	[52, 84]

B. Image Segmentation

Great efforts have been put forward to perform segmentation on retinal images. Segmentation methods attempt to extract the required part of image for further processing. It actually detects the different objects present in the retinal images. In the field of medical imaging many segmentation techniques has been developed[56]. Traditional image processing methods uses some mathematical functions to perform segmentation. Lesion detection is the necessary preliminary phase for DR detection. This will provide added advantage to the later stages of the CAD system. Automatic segmentation of retinal images is very crucial to find out the exudates[57], micro aneurysms, optic disc and extraction of blood vessel, which in turn identifies DR[58]. Classification accuracy of DR can be improvised with the support of image segmentation[59]. Different models designed for the identification of the characteristics present in the retinal image is shown in [Fig.2]. Features used for the segmentation of DR include micro aneurysms, exudates[60], optic disc and hemorrhages[61].

Segmentation models of retinal images include optic disc extraction[34, 62], exudate detection[63], blood vessel extraction[34, 64-65] hemorrhages and micro aneurysm detection. Results of retinal image segmentation is grouped as shown in the [Fig.3].

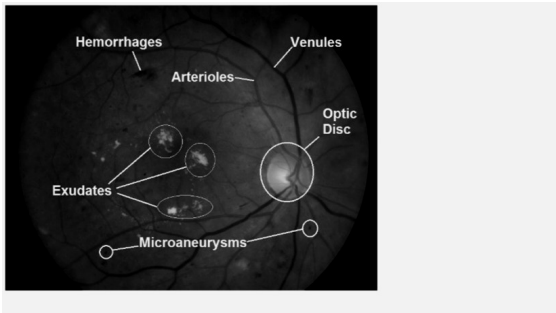

Fig. (2). Features of color retinal image

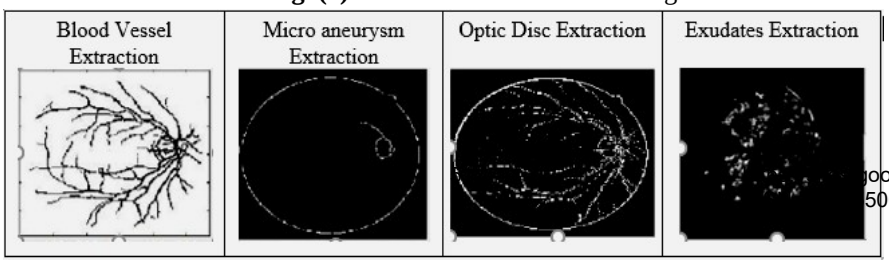

Fig. (3). Result of retinal segmentation models

Shyam et. al.[67] used Hough transform to segment optic disc in the fundus image. Prasad et al.[68] proposed a work to improve the accuracy of exudate detection. This work used top hat platform to perform segmentation with an accuracy of 90%. Tanapat et al.[72] discussed localization of optic disc using morphological operation and convex hull techniques. Method performs localization of fovea and macula using morphological erosion operation, which reported an accuracy of 97%. Siva Sundhara Raja and Vasuki proposed an automatic segment of blood vessels through the elimination of optic disc[76]. Non linear filter, anisotropic diffusion filter and morphological operations are used for detecting the retinal blood vessels. It outperforms other segmentation methods with an accuracy of 98.08%.Waleed Al-Nuaimy et al.[77] focused on the detection of exudate by exploiting characteristics of distinct borders using morphological gradient and rectified the unilluminating defects by using region based segmentation. Sensitivity of 93.1% is reported in this method. Zhou et al.[78] used LFSA to reconstruct new optic disc images and a generated spectrum was used for classification. Classification accuracy of 99% reported on Messidor dataset.

Liskowski et al.[79] proposed a supervised segmentation technique that uses a DNN trained on a huge collection of preprocessed images. It used a supervised segmentation technique using DNN with a sensitivity of 87%. It is an effective method for detecting the blood vessels in the retinal images. Prasad et.al.[80] extracted blood vessels using morphological processing and filtering methods. Kabir Md Ahasan[81] proposed LPBPC algorithm to remove the false blood vessels from the segmented vessels. Tan et al.[82] proposed a 10-layer convolutional neural network to automatically segment and discriminate exudates, hemorrhages and micro-aneurysms. Table 3 provides state of art related to retinal segmentation techniques.

Table 3. State of art related to retinal segmentation techniques.

Sl.No.	Techniques	References	Dataset	Remarks
1.	Region growing method.	[4][6][30]	MESSIDOR,DIARETDB1 .	Vessel segmentation.
2.	Deep Neural Networks.	[14][73]	DRIVE, STARE, and CHASE databases. DDR.	Vessel segmentation. Lesion detection .
3.	Morphological component analysis.	[15][57][68]	MESSIDOR.	Vessel segmentation. Exudate sementation.
4.	Adaptive Thresholding	[16]	140 images	Blood vessel extraction
5.	Gaussian mixture model.	[27]	KAGGLE.	Blood vessel extraction. Exudate detection.
6.	Patch based analysis.	[35]	DIARETDB1 and e-Ophtha.	Identification of exudates, hemorrhages, and microaneurysms.
7.	Rule based and machine learning methods.	[65]	DRIVE, STARE.	Retinal vessel segmentation techniques using Rule based: Automatic local thresholding techniques. Kernel-based techniques(Matched filtering based). Mathematical morphology-based. Multi-scale Techniques. Model-based. Vessel-tracking.
8.	Density analysis and bounding box technique.	[66]	30 images. -blood	v Vessel extraction.
9.	Hough transform, Top hat transform. Watershed transform.	[36,37,[67-69,100]	DIARETDB1, HRF.	Blood vessel segmentation. Optic disc extraction.

https://sites.google.com/site/ijcsis/
ISSN 1947-5500

				Micro aneurysm extraction.
10.	Thresholding	[6,12,17,25,30,31,38,40,45,57, 60,68,69,99]	DIARETDB1, HRF. Retinopathy Online Challenge dataset and E-Ophtha-MA dataset. DRIVE.	Blood vessel extraction. Detection of Microaneurysms. Detection of hard exudates.
11.	Intensity based properties.	[70]	DIABETDB1.	Exudate. Blood vessel extraction. Microaneurysms. Hemorrhages.
12.	Canny edge detection.	[71, 72]	STARE. and CHASE_DB1.	Detect normal and abnormal blood vessels. Detect MA and Hemorrhage
13.	U-net model.	[74]	DIARETDB1, HEI-MED, MESSIDOR.	Detection of exudates.
14.	Saliency method.	[75]	DIARETDB1 .	Detection of optic disc and exudates.
15.	Anisotropic diffusion filter.	[76]	DRIVE and STARE.	Detection of optic disc from the green channel retinal image. Lesion segmentation.
16.	Fuzzy C-means clustering.	[48]	100 images(Resolution of 1280 x 1024 or 700 x 605 Pixels).	Detection of blood vessels from the sample fundus images.
17.	Splat segmentation.	[91]	MESSIDOR.	Detection of retinal hemorrhages.

C. Feature Extraction

Feature extraction[83] is the core phase in the detection process of DR. Classification accuracy of the CAD system can be improved by the use of advanced feature extraction methods[84]. It is very essential to identify the features that are used for classification. This preliminary phase is crucial for the later stages of the detection of DR. Many features such as blood vessels, exudates, micro aneurysms and location of optic disc are extracted and analyzed for the classification purpose. Faust O et al.[11] described detailed view of the retinal features. Chaudhuri[12] used two dimensional matched filters to extract the blood vessels to differential the severity level of DR detection. Priya and Aruna[44] extracted statistical features such as radius, diameter, and area, arc length to find hemorrhage or exudate. Sarah Barman et al.[47] applied region growing method and mathematical morphology techniques to extract image components. Multi scale correlation coefficients were used to detect bright spot in the image. In another method Chand et.al.[53] used gray level co-occurrence matrix to extract the textual features from the retinal images. Pratt et al.[54] introduced recent CNN based algorithms to pull out the features accurately with an accuracy of 75%.

Bhargavi R et al.[85] used SIFT algorithm to identify the key points in an image. SIFT is one of the best among local invariant feature descriptors. By using the extracted features, the system can categorize the severity of the diseases as mild, moderate and severe. Deep neural networks extract a set of retinal features from the training data set. In addition, it performs feature selection based on deep neural network model, repeatedly removing features for the classifier model, one by one, until it reaches a stable performance measure. Nisha et al.[87] proposed a method that combines texture and vessel feature extraction based on Gabor wavelet methods. This work used entropy filter and range filters which were used to extract the neighborhood features from retinal images. Table 4 provides state of art feature extraction techniques.

Table 4. Feature extraction techniques.

Feature extraction techniques	**References**	**Remarks**
Matched Fillter	[12,66,92]	Blood vessel extraction.
Morphological transform and Gradient operator.	[16][36] [40]	Optic disc removal and blood vessel extraction.
Saddle and D-saddle Feature detector	[29]	Vessel feature extraction.
Local Energy model and LESH.	[33]	It gathers the attributes at points of an image where the local frequency components are maximized in term of phase.

https://sites.google.com/site/ijcsis/
ISSN 1947-5500

		LTP uses a fixed threshold to make binary patterns extraction more robust.
Local Ternary Co-occurrence Pattern.	[33]	Uses a fixed threshold to make binary patterns extraction stronger.
SURF.	[18,41, 96]	Detector and a descriptor for points of interest in images where the image is transformed into coordinates.
Thresholding.	31,[44]	Exudates and optic disc extraction. A straightforward shape extraction technique. Method of producing regions of uniformity within an image based on some threshold criterion.
Top hat transform.	[37.99]	Micro aneurysm and blood vessel extraction.
Circular hough transform. Region of Interest (ROI)	[40]	Optic disc detection.
DWT.	[44, 84]	Extraction of wavelet based features such as aspect ratio, eccentricity, entropy etc.
GLCM.	[49, 53, 68, 84, 88]	Extraction of texture and intensity features.
FFT.	[51]	Transform domain feature extraction.
Principal Component Analysis	[27,71, 83]	Blood vessel extraction. Extraction of statistical features.
Local Binary Pattern.	[67,80,90]	Extraction of texture features sensitive to noise.
Spherical directional local ternary pattern (SDLTP)	[83]	Extraction of statistical features based on direction.
SIFT.	[27,85]	Local invariant feature descriptor extraction.
Spat based feature extraction	[91]	Detection of Hemorrhage .

D. Classification

Main goal of automated classifier is to classify the images in to a particular category based on the features extracted from them. Earlier work on DR mainly focused on image processing techniques, which were initially used as the technology for the classification of retinal images. Other than these conventional methods, neural networks provide promising result for classification tasks. New generation algorithms use statistical, machine learning, visualization, and other deep learning techniques[89] for the classification purpose.

SVM classifier[2] is employed to classify the images into normal, mild, moderate, severe and proliferative categories. This system extracted blood vessels and exudates for the detection of DR. Accuracy of the system is 96.4%. It uses small data sets such as DIARETDB0 and DIARETDB1databases. Neural network multi-layer perceptron system for classification of retinal images was a powerful mechanism[38] to extract the lesions. Accuracy of the method is 91%. For good accuracy, brighter lesion identification algorithms are needed. More number of features can be added to improve the efficiency of the system. Preprocessing techniques including image enhancement will improve the accuracy of the system. Priya et al.[44] models PNN, Bayesian Classification and SVM and their performances are compared. Authors claimed SVM outperforms other two methods with an accuracy of 95.3%. Agurt et al.[46] uses a cross validation approach, which classifies retinal images into different grades. K-means clustering was used for grouping the information and a linear regression model, Partial Least Square (PLS) was used to identify the classes with an accuracy of 92%. Velázquez-González et al.[49] classified the severity of DR into Normal DR, Light NPDR, moderate and severe DR using BPNN. Accuracy of the system is 92%. Accuracy coukd be increased by employing more retinal images and strong algorithmic implementations. Exudate detection from normal and abnormal image was scrutinized using SVM classifier[53] by Chand et.al.. Method always provided better results when it used with high dimensional data sets. Exudates were detected using SVM classifier with an accuracy of 92%. Prasad et al.[55] proposed one rule classifier and BPNN for the detection of DR. Data set used is DIARETDB1 database. Method gives an accuracy of 93.8% for BPNN and 97.75% for one rule classifier. Ratanak Khoeun et.al.[86] proposed unique approach using Matched Filters and Area Based Noise Removing to extract the micro aneurysms in the retina images. Mahiba C et .al[90] proposed a multi class DR classification methodology using hybrid color, texture features and modified CNNs. The overall classification accuracy of the proposed system is 98.41%.

https://sites.google.com/site/ijcsis/
ISSN 1947-5500

In[91] classification carried out using QDA in which over fitting may occur. Class labels were identified Using K-Nearest Neighbour. Accuracy achieved by the system is 87%. Maher et.al.[92] described a comparison between different classification methods and their accuracies. Rahim et al.[93] used decision tree and the k-nearest neighbor classifiers to classify the images in to different categories. It classifies data in to two classes with the accuracy of 74% for BDT and 78% for k-nearest neighbor. Table 5provides summary of the detection of DR. Table 6 provides Advantages/Disadvantages of DR detection/classification schemes.

Table 5. Summary of the detection of DR.

Ref. No	Major steps of methodology	Features used	Dataset used	Performance/Remarks
[16]	i)Green channel extraction. ii)Local-phase method is emloyed . iii)Morphological operator used for vessel extraction. iv)Gradient operator used for removing optic disc. v)ANOVA test for classification	Blood vessels,optic disc	140 images collected at Department of Ophthalmology, Kas-turba Medcial College, Manipal, India.	Accuracy of :91%for normal, 92.7% for PDR, and 87.8% for NPDR images. This method outperforms [12]
[26]	i) Gray scale conversion is performed. ii) CLAHE is employed in next phase. iii) Error-correcting output codes (ECOC) has been used for classification.	Statistical features of Visibility graph representation.	MESSIDOR.	Accuracy of :92%. Sensitivity :95.83%. Specificity : 98.61%. This method can effectively applied for DR grading and give better performance than [35,36,40,48]
[33]	i) Gray scale conversion is performed. ii) Local Energy model and Local Energy-based Shape Histogram (LESH) used for extracting the point of interests. iii) SVM with a Radial Basis Function kernel (SVM-RBF) is employed.	Texture features.	MESSIDOR.	Accuracy:90.04%. It gives best performance due to LESH features and perform better than [48,91,93,94,97,99]
[35]	i) Contrast enhancement is employed. ii) Patch preparation and image analysis is performed. iii) CNN is applied for DR detection.	Exudates, hemorrhages and micro aneurysms.	DIARETDB1. e-Ophtha.	Accuracy :DIARETDB1 97.3%. 86.6% for e-Ophtha. Patch and image-based analysis gives better accuracy than other studies such as [36,37,40,48,54,2,74,84,96,97, 98,99]
[36]	i) Morphological processed image is binarized. ii) Noises are reduced. iii) SVM and decision tree is used for classification.	Blood vessel density. Actual number of micro aneurysms. Density of hard exudates. Quantitative features.	MESSIDOR.	SVM Accuracy:92.4%. Decision-tree Accuracy:92%. It provides an optimized better result than [48,68,97] using similar classifiers.
[37]	i) Median filtering is applied. ii) Green channel extraction is performed. iii) K Nearest Neighbor is used in the final stage.	Micro Aneurysm.	1441images.	Sensitivity : 85.4%. Specificity : 83.1%. This work detects MA only.
[40]	i) Green channel extraction and Fuzzy filtering is performed. ii) Fuzzy Histogram Equalization is employed. iii) Classifiers such as k-Nearest Neighbour, Polynomial Kernel SVM, RBF Kernel SVM and Naïve-Bayes are	Exudates. Blood vessels,optic disc.	600 images collected at the Hospital Melaka, Malaysia.	K nearest neighbor Accuracy:93%. Polynomial Kernel SVM Accuracy:70%. RBF Kernel SVM Accuracy:93%. Naïve-Bayes

https://sites.google.com/site/ijcsis/
ISSN 1947-5500

	used for DR detection/classification.			Accuracy:75%. This work out performs [46] which uses AM-FM features.
[48]	(i)AHE,Matched Fitering,Gray scale conversion is performed. ii)DWT is employed. iii)Fuzzy C-means clustering is used for segmentation. iV)PNN and SVM are used for classification.	Statistical features.	100 images(Resolution of 1280 x 1024 or 700 x 605 Pixels).	Accuracy:87.68% Sensitivity : 81.42% Specificity : 100%. DR system using SVM gives more accuracy than PNN (70%). It outperforms [97]
[51]	i) Image is resized. ii) Gray scale conversion is done. iii) Feature vector is formed using FFT. iv)Multi Layer Perceptron is employed.	Statistical parameters.	DIARETDB0.	Accuracy:99%. MLPNN classifier perform well with 09 hidden PEs, learning rule momentum, transfer function tanh and step size 0.1.FFT based feature extraction gives best accuracy than [52,54,70,74,84,88,94-98]
[52]	i) Grayscale conversion is performed on image. ii) Gabor filter is applied. iii) Mathematical morpology is used for image segmentation. iv) Probabilistic,geometric,tree based and KNN classification methods are applied for DR detection/classification.	Statistical and geometric features.	MESSIDOR. DIARETDB. DRIVE. VDIS HRF HRIS e-ophtha	Average accuracy: 98.58%. This method is evaluated on 7 data sets . DIARETDB gives an accuracy of 96.6 for KNN,96.8 %for SVM,96.6 %for Bayesian and 91.7 for ensemble classifier.
[70]	i) Green channel extraction is performed. ii) HE is employed. iii) Morphological operations are applied. iv) SVM is used for classification.	Number and area of MA.	DIABETDB1.	Sensitivity:96%. Specificity:92%. Proposed method gives better sensitivity and specificity for NPDR detection than [84,97]
[74]	i) Image is resized. ii) Green channel extraction is performed. iii) Adaptive contrast enhancement technique is applied. iv) Conditional GAN is used in the final stage of the method developed.	Exudates.	e-Ophtha_EX. DIARETDB1. HEI-MED. MESSIDOR.	Accuracy:95.45%. With CGAN Specificity 92.13%, Sensitivity:88.76%, and F1score:89.58%, without cGAN thhe sores are 86.36%, 87.64%, 76.33%, 86.42% respectively. System performance is better than [95,98]
[84]	i) Candidate region is extracted. ii) Contrast enhancement is performed. iii) Morphological operations are applied to enhance MAs. iv) Multi layered feed forward neural network (FFNN) and support vector machine classifiers were applied.	Micro aneurysm Statistical and wavelet features	DIARETDB1.	SVM Accuracy, Sensitivity, Specificity: 95%, 76%, 92% respectively. Multi layered feed forward neural network (FFNN) classifier Accuracy, Sensitivity, Specificity:92%, 79%, 90% respectively.
[88]	i) Image is resized. ii) CLAHE is applied. iii) SVM is employed for classification.	Blood vessel area, Micro aneurysms area, Exudates area and Texture features	DIARETDB0. DIARETDB1.	Accuracy:96.67%. SVM classifier reports good results.
[94]	i) HE is employed. ii) Morphological operations are applied. iii) Image is binarized.	Area of veins, hemorrhages and micro aneurysms	124 retinal images.	Sensitivity:90%. High computational cost.

https://sites.google.com/site/ijcsis/
ISSN 1947-5500

	iv) Back propagation algorithm is used for DR detection/classification.			
[95]	i) Data augmentation is performed. ii) CNN is employed for classification.	Hard exudates, red lesions, micro aneurysms and blood vessel	KAGGLE.	Accuracy:94.5%. CNN gives better accuracy than [38,91,93,96,9,99].This method gives more accuracy than [54] on kaggle data set.
[96]	i) Green channel extraction is performed. ii) Image is resized. iii) AHE and morphological operations are performed. iv) SVM is used in the final stage of DR detection.	Lesions	DRIDB0,DRIDB1 , MESSIDOR, STARE and HRF.	Accuracy:94.4%. This method outperforms [48] .Adopted SIFT for feature extraction.
[97]	i) Daubechies Wavelet transform is employed. ii) Background normalization is performed. iii) Median filtering is applied. iv) SVM classifier is employed in the final stage.	Micro aneurysm	LaTIM (Laboratoire de Traitement de lInforma-tion Médicale). E-ophtha,ROC database.	Sensitivity: 62% (LaTIM). Sensitivity:66% (eophtha). Sensitivity:32 %. (ROC) MA are detected easily by extracting laws texture based features from small regions at a time.
[98]	i) Normalization and Data augmentation is performed. ii) Non-Local Means Denoising is performed iii) CNN is used for classification.	Automatic feature Identification	KAGGLE.	Accuracy:95.68%. Transfer learning and hyper parameter-tuning methods are applied to improve the performance of this system. It out performs [95] and [54]
[99]	i) Discrete Curvelet Transform is applied. ii) Morphological operations are applied. iii) Simple thresholding is performed. iv) Connected component analysis is performed.	Blood vessels and statistical features	DRIVE.	Accuracy: 94%. Contrast of the images can be improved by FDCT.

III. Result and Discussions

This study of DR detection techniques reveals the requirement for numerous preprocessing techniques needed for the noise reduction. The efficiency of the CAD system can be improved by applying preprocessing techniques effectively at the early stages. Most of the papers in this survey applied contrast enhancement and filtering techniques for preprocessing. Importance of various techniques in the survey is shown in the [Fig.4]. Various extracted features from the retinal images are the input to the classification algorithms. Different authors were used different features of the retinal images including blood vessels, exudates, micro aneurysms, hemorrhages, optic disc and other statistical features.

Among the methods mentioned in this paper, work[26] reported an accuracy of 92%, which adopted statistical features and error correcting output codes. Due to FFT based feature extraction on DIARETDB dataset Bhatkar et.al. Method[51]outperforms other methods with 99% success rate. Method[97] exhibited poor accuracy because of its restricted use of features extraction and preprocessing techniques . Amin et. al.[52] evaluated the performance on 7 data sets and applied various classification techniques for DR detection. Among the classification techniques employed, KNN outperforms other methods.

Optic disc localization using morphological erosion provided an accuracy of 97%. Blood vessel extraction is the main segmentation scheme used in most of the papers in this survey. This can achieve accuracy around 98%. Segmentation of exudates is another technique used with an accuracy of 93%. The frequency of segmentation methods used in the classification algorithms are depicted in the [Fig.5]. According to the survey conducted, machine learning and deep learning techniques can improve the accuracy of segmentation techniques.

This survey focuses on the different classification algorithms used in the detection and prediction of retinal images. The study includes the various image processing methods used in classification process. With the introduction of AI, classification process of CAD system improves its performance. Image processing techniques along with machine learning techniques evolved as a technological development in the diagnosis system for DR. SVM and Naive Bayes classifiers perform well in the data sets of DR detection with an accuracy of 92%. Deep learning technique such as CNN is the common method used in the field of medical imaging. It can provide promising results with larger data sets. Wan, Shaohua et.al.[98] usesd CNN algorithm on Kaggle dataset and reported an accuracy of 95.86%. It used preprocessing techniques such as augmentation and normalization on the datasets to improve the accuracy. Requirement of a large dataset is the great challenging task associated with the DNN. Synthetic images can be generated using the generative networks like GAN. Application of

https://sites.google.com/site/ijcsis/
ISSN 1947-5500

GAN networks in retinal data sets can be used to generate images and can be used for noise reduction. AI techniques such as machine learning and deep learning algorithms effectively classify the retinal images.

SVM-RBF followed by LESH performed better in the classification of DR. Method reported an encouraging result. Fuzzy Histogram Equalization preceded by SVM-RBF reported an accuracy of 93%in DR detection. Multilayer perceptron which uses features from FFT reported an accuracy above 98% on DIARETDB0 data set. In the detection of DR, KNN followed by the probabilistic geometric tree method showed a better performance with an average accuracy of 98.95% over 7 data sets.

Performance of CAD system for DR detection can be further improved by the application of relevant techniques. Deep neural networks along with transfer learning will improve the accuracy of the systems. Transfer learning can be used for different strategies and can be combined (hybridized approach) to get better performance for a CAD system. In some cases, methods dealing with imbalanced data classification will improve the performance of the CAD system. Application of relevant under sampling or oversampling techniques will solve the imbalanced dataset issue and will improve the performance of the CAD system. Performance of blood vessel and lesion segmentation methods can be further improved by employing relevant dimensionality reduction techniques. It is a challenging task to compare various methodologies in terms of its accuracy, because most of the researchers have used different techniques and various datasets. Detection of different size, shape and position of the lesions can be a major challenge in the classification of DR. Transfer learning based CNN [50] can be applied to improve the performance of CAD system.

Fig. (4).Review of various preprocessing techniques used in the survey.

Fig. (5). Review of various segmentation methods

Table 6. Advantages/Disadvantages of some DR detection/classification schemes.

Work	Advantages(A) /Disadvantages (D)	Work	Advantages(A) /Disadvantages (D)	Work	Advantages(A) /Disadvantages (D)
[16]	(A) The proposed method uses local-phase method.	[32]	(A) Novel dataset with new labeling scheme is useful for ce. false negative graded as erity class. from more re not included.	[33]	(A) Use of Local Ternary Pattern (LTP) and Local Energy-based Shape Histogram (LESH) captures the connection between neighboring pixels and features, which are less sensitive to variation in illumination, color and noise. It can easily be differentiated between DR and non-DR images. (D) Suitable only for small data sets.
	available databases with the training done on one and the testing on both with similar outcomes. (D) Unfit to separate among		n to detection of performs grade classification. The outcome was additionally optimized by choosing the most relevant features and classification parameters. number of micro was not identified images. Texture l soft exudates considered for	[39]	(A) Proposed method is robust to noise. Does not depend on the specific features of lesions present in the retinal images. (D) Performance of blood vessel and lesion segmentation methods are not satisfactory.
[4]			tic and statistical sed for better . Multiple data evaluation. of DR grading is le with only	[53]	(A) SVM along with textual features provides good results to extract the exudates in DR images. (D) Utilize only optic disc segmentation.

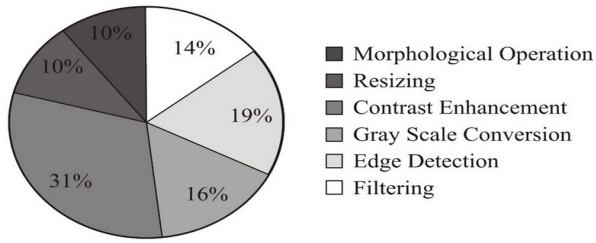

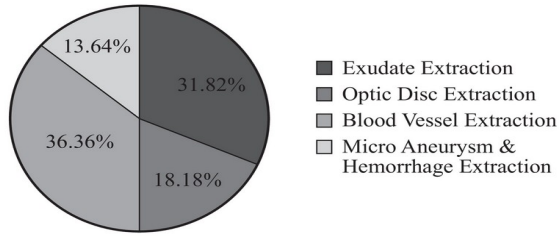

https://sites.google.com/site/ijcsis/
ISSN 1947-5500

	retinal structures must be removed. Hence, strong preprocessing methods are needed.		exudate segmentation.		
[62]	(A) Good performances on low quality images. (D) Used as a primary diagnosis tool, needs the support of ophthalmologist.	[74]	(A) Methodology applied a cGAN framework to solve the imbalance data classification problem. It also generate synthetic images to improve the generalization property of the network. (D) In the proposed methodology extra training phase is required for cGAN.	[80]	(A) Combination of neural network and fuzzy classification improves the accuracy of multi stage DR classification. The main advantage of the system is the learning capability and its simplicity. (D)Efficient segmentation methods not used for detecting retinal features.
[84]	(A) Proposed system make use of an optimal feature set for accurate detection and classification of DR. Accurate blood vessel extraction improves the accuracy of the system. (D) Other lesions present in the retinal images such as exudates were not utilized.	[87]	(A) Time constraints is reduced by the proper usage of feature reduction techniques. (D) Automatic segmentation techniques not used in this paper.	[88]	(A) Apart from the lesion features of retinal images, proposed system also includes texture features for classification. This will improve the classification accuracy. (D) Only 4 texture features and small set of images considered for evaluation.
[91]	(A) Splat-based image representation provides an efficient and optimized way to model uneven shaped abnormalities in medical images. It also took less time for classification. (D) Reference model was used only part of the dataset and took review only from a single expert.	[96]	(A) This method is a feasible, efficient, and time saving way of DR detection. Proposed method discriminates retinal images without earlier requirement for segmentation of blood vessels and optic disc. (D) Limited number of retinal images were used.	[97]	(A) Higher-order statistics method, such as Laws masks combined with conventional methods used to detect MA with a promising result. (D) Two trains and two test phases were needed. Still preprocessing was not so effective.
[100]	(A) Different specific features and datasets combined for the detection of DR. (D) Datasets with only 516 images used for the evaluation.	[101]	(A) Deep transfer learning is an appropriate method for multi-categorical classification of fundus images. (D) Due to the small data sets deep learning technique for DR detection is not so effective.	[102]	(A) Custom morphology based multi scale descriptors for lesion analysis improved the performance of the system. (D) Study only included darkly pigmented Asian Indian patients. Therefore, the result can't be generalized.

IV. CONCLUSION

Nowadays, retinal imaging and its diagnosis is an emerging field in medical imaging. This survey presented a detailed study of CAD system for DR. This paper presented methods that are used for building a CAD system for diabetic retinopathy screening. This work will be helpful for the researchers and technical persons who want to utilize the ongoing research in this area. A researcher to get an insight in to the various segmentation, feature extraction and classification methods can use our paper. The accuracy of various classification algorithms were compared by analyzing their performances. Efficiency of the CAD system can be improved by the development of deep neural networks on large data sets. New annotated data sets can be created for efficient clinical applications. Synthetic retinal images can be created by applying networks like GAN and can be used for the processing of deep neural networks. DR detection systems still need improvements in grading the severity of the retinal diseases. CAD system for DR can be further upgraded by adapting new acquisition and optimized pre-processing methods in retinal data sets.

REFERENCES

[1] Larsen M, Godt J, Larsen N, Lund-Andersen H, Sjølie AK, Agardh E, Kalm H, Grunkin M, Owens DR. Automated detection of fundus photographic red lesions in diabetic retinopathy. Investigative ophthalmology & visual science. 2003 Feb 1; 44(2):761-6.

[2] Maher RS, Kayte SN, Meldhe ST, Dhopeshwarkar M. Automated diagnosis of non-proliferative diabetic retinopathy in fundus images using support vector machine. International Journal of Computer Applications. 2015 Jan 1; 125(15).

[3] Torre J, Valls A, Puig D. A deep learning interpretable classifier for diabetic retinopathy disease grading. Neurocomputing. 2020 Jul 5; 396:465-76.

[4] Abramoff MD, Niemeijer M, Russell SR. Automated detection of diabetic retinopathy: barriers to translation into clinical practice. Expert review of medical devices. 2010 Mar 1; 7(2):287-96.

[5] Pires R, Avila S, Wainer J, Valle E, Abramoff MD, Rocha A. A data-driven approach to referable diabetic retinopathy detection. Artificial intelligence in medicine. 2019 May 1; 96:93-106.

[6] Palavalasa KK, Sambaturu B. Automatic diabetic retinopathy detection using digital image processing. In 2018 International Conference on Communication and Signal Processing (ICCSP). 2018 Apr 3 (pp. 0072-0076). IEEE.

[7] Schmidt-Erfurth U, Sadeghipour A, Gerendas BS, Waldstein SM, Bogunović H. Artificial intelligence in retina. Progress in retinal and eye research. 2018 Nov 1; 67:1-29.

[8] Abràmoff MD, Garvin MK, Sonka M. Retinal imaging and image analysis. IEEE reviews in biomedical engineering. 2010 Dec 10; 3:169-208.

[9] Fadafen MK, Mehrshad N, Razavi SM. Detection of diabetic retinopathy using computational model of human visual system.(2018).

[10] Xiao D, Bhuiyan A, Frost S, Vignarajan J, Tay-Kearney ML, Kanagasingam Y. Major automatic diabetic retinopathy screening systems and related core algorithms: a review. Machine Vision and Applications. 2019 Apr 15; 30(3):423-46.

[11] Faust O, Acharya R, Ng EY, Ng KH, Suri JS. Algorithms for the automated detection of diabetic retinopathy using digital fundus images: a review. Journal of medical systems. 2012 Feb 1; 36(1):145-57.

[12] Chaudhuri S, Chatterjee S, Katz N, Nelson M, Goldbaum M. Detection of blood vessels in retinal images using two-dimensional matched filters. IEEE Transactions on medical imaging. 1989 Sep; 8(3):263-9.

[13] Tan JH, Fujita H, Sivaprasad S, Bhandary SV, Rao AK, Chua KC, Acharya UR. Automated segmentation of exudates, haemorrhages, microaneurysms using single convolutional neural network. Information sciences. 2017 Dec 1; 420:66-76.

[14].Liskowski P, Krawiec K. Segmenting retinal blood vessels with deep neural networks. IEEE transactions on medical imaging. 2016 Mar 24; 35(11):2369-80.

[15] Kasurde SD, Randive SN. An automatic detection of proliferative diabetic retinopathy. In 2015 International Conference on Energy Systems and Applications 2015 (pp. 86-90). IEEE.

[16] Yelampalli PK, Nayak J, Gaidhane VH. Blood vessel segmentation and classification of diabetic retinopathy images using gradient operator and statistical analysis. In Proceedings of the World Congress on Engineering and Computer Science 2017 (Vol. 2).

[17] Adalarasan R, Malathi R. Automatic detection of blood vessels in digital retinal images using soft computing technique. Materials Today: Proceedings. 2018 Jan 1; 5(1):1950-9.

[18] Costa P, Galdran A, Smailagic A, Campilho A. A weakly-supervised framework for interpretable diabetic retinopathy detection on retinal images. IEEE Access. 2018 Mar 15; 6:18747-58.

[19] Li YH, Yeh NN, Chen SJ, Chung YC. Computer-assisted diagnosis for diabetic retinopathy based on fundus images using deep convolutional neural network. Mobile Information Systems. 2019 Jan 1; 2019.

[20] Pratt H, Coenen F, Broadbent DM, Harding SP, Zheng Y. Convolutional neural networks for diabetic retinopathy. Procedia Computer Science. 2016 Jan 1;90:200-5.

[21] Zhao H, Li H, Maurer-Stroh S, Cheng L. Synthesizing retinal and neuronal images with generative adversarial nets. Medical image analysis. 2018 Oct 1; 49:14-26.

[22] Perdomo O, Rios H, Rodríguez FJ, Otálora S, Meriaudeau F, Müller H, González FA. Classification of diabetes-related retinal diseases using a deep learning approach in optical coherence tomography. Computer methods and programs in bio medicine. 2019 Sep 1; 178:181-9.

[23] Hemanth DJ, Deperlioglu O, Kose U. An enhanced diabetic retinopathy detection and classification approach using deep convolutional neural network. Neural Computing and Applications. 2020 Feb 1; 32(3):707-21.

[24] Voets M, Møllersen K, Bongo LA. Reproduction study using public data of: Development and validation of a deep learning algorithm for detection of diabetic retinopathy in retinal fundus photographs. PLOS one. 2019 Jun 6; 14(6):e0217541.

[25] Eftekhari N, Pourreza HR, Masoudi M, Ghiasi-Shirazi K, Saeedi E. Microaneurysm detection in fundus images using a two-step convolutional neural network. Biomedical engineering online. 2019 Dec 1; 18(1):67.

[26] Mohammadpoory Z, Nasrolahzadeh M, Mahmoodian N, Haddadnia J. Automatic identification of diabetic retinopathy stages by using fundus images and visibility graph method. Measurement. 2019 Jul 1; 140:133-41.

[27] Mansour RF. Deep-learning-based automatic computer-aided diagnosis system for diabetic retinopathy. Biomedical engineering letters. 2018 Feb 1; 8(1):41-57.

https://sites.google.com/site/ijcsis/
ISSN 1947-5500

[28] Chudzik P, Majumdar S, Calivá F, Al-Diri B, Hunter A. Microaneurysm detection using fully convolutional neural networks. Computer methods and programs in biomedicine. 2018 May 1; 158:185-92.

[29] Ramli R, Idris MY, Hasikin K, Karim NK, Abdul Wahab AW, Ahmedy I, Ahmedy F, Kadri NA, Arof H. Feature-based retinal image registration using D-Saddle feature. Journal of healthcare engineering. 2017 Jan 1; 2017.

[30] Valverde C, Garcia M, Hornero R, Lopez-Galvez MI. Automated detection of diabetic retinopathy in retinal images. Indian journal of ophthalmology. 2016 Jan; 64(1):26.

[31] Sisodia DS, Nair S, Khobragade P. Diabetic retinal fundus images: Preprocessing and feature extraction for early detection of diabetic retinopathy. Biomedical and Pharmacology Journal. 2017 Jun 20; 10(2):615-26.

[32] Gao Z, Li J, Guo J, Chen Y, Yi Z, Zhong J. Diagnosis of diabetic retinopathy using deep neural networks. IEEE Access. 2018 Dec 19; 7:3360-70.

[33] Chetoui M, Akhloufi MA, Kardouchi M. Diabetic retinopathy detection using machine learning and texture features. In 2018 IEEE Canadian Conference on Electrical & Computer Engineering (CCECE) 2018 May 13 (pp. 1-4). IEEE.

[34] Qureshi I, Ma J, Abbas Q. Recent development on detection methods for the diagnosis of diabetic retinopathy. Symmetry. 2019 Jun; 11(6):749.

[35] Khojasteh P, Aliahmad B, Kumar DK. Fundus images analysis using deep features for detection of exudates, hemorrhages and microaneurysms. BMC ophthalmology. 2018 Dec; 18(1):1-3.

[36] Carrera EV, González A, Carrera R. Automated detection of diabetic retinopathy using SVM. In 2017 IEEE XXIV International Conference on Electronics, Electrical Engineering and Computing (INTERCON) 2017 Aug 15 (pp. 1-4). IEEE.

[37] Fleming AD, Philip S, Goatman KA, Olson JA, Sharp PF. Automated micro aneurysm detection using local contrast normalization and local vessel detection. IEEE transactions on medical imaging. 2006 Aug 21; 25(9):1223-32.

[38] Handsková V, Pavlovicova J, Oravec M, Blasko R. Diabetic rethinopathy screening by bright lesions extraction from fundus Images. Journal of Electrical Engineering. 2013 Sep 1; 64(5):311.

[39] Imani E, Pourreza HR, Banaee T. Fully automated diabetic retinopathy screening using morphological component analysis. Computerized medical imaging and graphics. 2015 Jul 1; 43:78-88.

[40] Rahim SS, Palade V, Shuttleworth J, Jayne C. Automatic screening and classification of diabetic retinopathy and maculopathy using fuzzy image processing. Brain informatics. 2016 Dec 1; 3(4):249-67.

[41] Mangrulkar RS. Retinal image classification technique for diabetes identification. In 2017 International Conference on Intelligent Computing and Control (I2C2) 2017 Jun 23 (pp. 1-6). IEEE.

[42] Sreng S, Takada JI, Maneerat N, Isarakorn D, Varakulsiripunth R, Pasaya B, Panjaphongse MR. Feature extraction from retinal fundus image for early detection of diabetic retinopathy. In 2013 IEEE Region 10 Humanitarian Technology Conference 2013 Aug 26 (pp. 63-66). IEEE.

[43] Ramasubramanian B, Selvaperumal S. A comprehensive review on various preprocessing methods in detecting diabetic retinopathy. In 2016 international conference on communication and signal processing (ICCSP) 2016 Apr 6 (pp. 0642-0646). IEEE.

[44] Priya R, Aruna P. Diagnosis of diabetic retinopathy using machine learning techniques. ICTACT Journal on soft computing. 2013 Jul; 3(4):563-75.

[45] Estabridis K, de Figueiredo RJ. Automatic detection and diagnosis of diabetic retinopathy. In 2007 IEEE International Conference on Image Processing 2007 Nov (Vol. 2, pp. II-445). IEEE.

[46] Agurto C, Murray V, Barriga E, Murillo S, Pattichis M, Davis H, Russell S, Abràmoff M, Soliz P. Multiscale AM-FM methods for diabetic retinopathy lesion detection. IEEE transactions on medical imaging. 2010 Feb 2; 29(2):502-12.

[47] Sopharak A, Uyyanonvara B, Barman S. Automated microaneurysm detection algorithms applied to diabetic retinopathy retinal images. Maejo International Journal of Science and Technology. 2013 May 1; 7(2):294.

[48] Sayed S, Kapre S, Inamdar D. Detection of diabetic retinopathy using image processing and machine learning. International Journal of Innovative Research in Science, Engineering and Technology. 2017 Jan; 6(1):99-107.

[49] Velázquez-González JS, Rosales-Silva AJ, Gallegos-Funes FJ, Guzmán-Bárcenas GD. Detection and classification of non-proliferative diabetic retinopathy using a back-propagation neural network. Revista Facultad de Ingeniería Universidad de Antioquia. 2015 Mar(74):70-85.

[50] Gour N, Khanna P. Multi-class multi-label ophthalmological disease detection using transfer learning based convolutional neural network. Biomedical Signal Processing and Control. 2020 Dec 9:102329.

[51] Bhatkar, Amol P, and Govind K. FFT based detection of diabetic retinopathy in fundus retinal images. Proceedings of the Second International Conference on Information and Communication Technology for Competitive Strategies. ACM, 2016.

[52] Amin J, Sharif M, Yasmin M, Ali H, Fernandes SL. A method for the detection and classification of diabetic retinopathy using structural predictors of bright lesions. Journal of Computational Science. 2017 Mar 1; 19:153-64.

https://sites.google.com/site/ijcsis/
ISSN 1947-5500

[53] Chand CR, Dheeba J. Automatic detection of exudates in color fundus retinopathy images. Indian Journal of Science and Technology. 2015 Oct; 8(26).

[54] Pratt H, Coenen F, Broadbent DM, Harding SP, Zheng Y. Convolutional neural networks for diabetic retinopathy. Procedia Computer Science. 2016 Jan 1; 90:200-5.

[55] Prasad DK, Vibha L, Venugopal KR. Early detection of diabetic retinopathy from digital retinal fundus images. In 2015 IEEE Recent Advances in Intelligent Computational Systems (RAICS) 2015 Dec 10 (pp. 240-245). IEEE.

[56] Abràmoff MD, Folk JC, Han DP, Walker JD, Williams DF, Russell SR, Massin P, Cochener B, Gain P, Tang L, Lamard M. Automated analysis of retinal images for detection of referable diabetic retinopathy. JAMA ophthalmology. 2013 Mar 1; 131(3):351-7.

[57] Partovi M, Rasta SH, Javadzadeh A. Automatic detection of retinal exudates in fundus images of diabetic retinopathy patients. Journal of Research in Clinical Medicine. 2016 May 9; 4(2):104-9.

[58] Mookiah MR, Acharya UR, Chua CK, Lim CM, Ng EY, Laude A. Computer-aided diagnosis of diabetic retinopathy: A review. Computers in biology and medicine. 2013 Dec 1; 43(12):2136-55.

[59] Sathananthavathi V, Indumathi G, Vishalini R, Alphia J. Automatic detection of microaneurysms in retinal images for diabetic retinopathy. International Journal of Pure and Applied Mathematics. 2018; 119(15):1349-55.

[60] Sindhura A, Kumar SD, Sajja VR, Rao NG. Identifying exudates from diabetic retinopathy images. In 2016 International Conference on Advanced Communication Control and Computing Technologies (ICACCCT) 2016 May 25 (pp. 132-136). IEEE.

[61] Qureshi I, Ma J, Shaheed K. A hybrid proposed fundus image enhancement framework for diabetic retinopathy. Algorithms. 2019 Jan; 12(1):14.

[62] Wisaeng K, Hiransakolwong N, Pothiruk E. Automatic detection of exudates in diabetic retinopathy images. Journal of Computer Science. 2012 Aug 1; 8(8):1304.

[63] Long S, Huang X, Chen Z, Pardhan S, Zheng D. Automatic detection of hard exudates in color retinal images using dynamic threshold and SVM classification: algorithm development and evaluation. BioMed research international. 2019 Jan 23;2019.

[64] Sundaram R, KS R, Jayaraman P. Extraction of blood vessels in fundus images of retina through hybrid segmentation approach. Mathematics. 2019 Feb;7(2):169.

[65] Almotiri J, Elleithy K, Elleithy A. Retinal vessels segmentation techniques and algorithms: a survey. Applied Sciences. 2018 Feb; 8(2):155.

[66] Verma K, Deep P, Ramakrishnan AG. Detection and classification of diabetic retinopathy using retinal images. In 2011 Annual IEEE India Conference 2011 Dec 16 (pp. 1-6). IEEE.

[67] Shyam L, Kumar GS. Detection of glaucoma and diabetic retinopathy from fundus images by blood vessel segmentation. 2016.

[68] Prasad DK, Vibha L, Venugopal KR. Early detection and multistage classification of diabetic retinopathy using random forest classifier. 2018.

[69] Verma SB, Yadav AK. Detection of hard exudates in retinopathy images. ADCAIJ: Advances in Distributed Computing and Artificial Intelligence Journal. 2019; 8(4):41-8.

[70] Kumar S, Kumar B. Diabetic retinopathy detection by extracting area and number of micro aneurysm from colour fundus image. In 2018 5th International Conference on Signal Processing and Integrated Networks (SPIN) 2018 Feb 22 (pp. 359-364). IEEE.

[71] Kaur, Sukhpreet, and Kulwinder Singh Mann. Optimized technique for detection of diabetic retinopathy using segmented retinal blood vessels. 2019 International Conference on Automation, Computational and Technology Management (ICACTM). IEEE, 2019.

[72] Ratanapakorn T, Daengphoonphol A, Eua-Anant N, Yospaiboon Y. Digital image processing software for diagnosing diabetic retinopathy from fundus photograph. Clinical Ophthalmology (Auckland, NZ). 2019; 13:641.

[73] Li T, Gao Y, Wang K, Guo S, Liu H, Kang H. Diagnostic assessment of deep learning algorithms for diabetic retinopathy screening. Information Sciences. 2019 Oct 1; 501:511-22.

[74] Zheng R, Liu L, Zhang S, Zheng C, Bunyak F, Xu R, Li B, Sun M. Detection of exudates in fundus photographs with imbalanced learning using conditional generative adversarial network. Biomedical optics express. 2018 Oct 1; 9(10):4863-78.

[75] Nur N, Tjandrasa H. Exudate segmentation in retinal images of diabetic retinopathy using saliency method based on region. In Journal of Physics: Conference Series 2018 Nov (Vol. 12110).

[76] Siva Sundhara Raja D, Vasuki S. Automatic detection of blood vessels in retinal images for diabetic retinopathy diagnosis. Computational and mathematical methods in medicine. 2015 Feb 24; 2015.

[77] Jaafar HF, Nandi AK, Al-Nuaimy W. Detection of exudates from digital fundus images using a region-based segmentation technique. In 2011 19th European signal processing conference 2011 Aug 29 (pp. 1020-1024). IEEE.

[78] Zhou W, Wu H, Wu C, Yu X, Yi Y. Automatic optic disc detection in color retinal images by local feature spectrum analysis. Computational and mathematical methods in medicine. 2018 Jun 14; 2018.

[79] Liskowski P, Krawiec K. Segmenting retinal blood vessels with deep neural networks. IEEE transactions on medical imaging. 2016 Mar 24; 35(11):2369-80.

[80].Prasad DK, Vibha L, Venugopal KR. Multistage classification of diabetic retinopathy using fuzzy neural

network classifier. ICTACT Journal on Image & Video Processing. 2018 May 1;8(4).

[81] Kabir MA. A rule based segmentation approaches to extract retinal blood vessels in fundus image. American Scientific Research Journal for Engineering, Technology, and Sciences (ASRJETS). 2020 Mar 30; 66(1):202-24.

[82] Tan JH, Fujita H, Sivaprasad S, Bhandary SV, Rao AK, Chua KC, Acharya UR. Automated segmentation of exudates, haemorrhages, microaneurysms using single convolutional neural network. Information sciences. 2017 Dec 1; 420:66-76.

[83] Randive SN, Senapati RK, Bhosle N. Spherical directional feature extraction with artificial neural network for diabetic retinopathy classification. In 2018 IEEE 13th International Conference on Industrial and Information Systems (ICIIS) 2018 Dec 1 (pp. 152-157). IEEE.

[84] Shirbahadurkar SD, Mane VM, Jadhav DV. Early stage detection of diabetic retinopathy using an optimal feature set. International Symposium on Signal Processing and Intelligent Recognition Systems 2017 Sep 13 (pp. 15-23).

[85] Bhargavi R, Rajesh V. Exudate detection and feature extraction using active contour model and SIFT in color fundus images. J. Eng. Appl. Sci. 2015:2362-5.

[86] Khoeun R, Rasmequan S, Chinnasarn K, Rodtuk A. Microaneurysm candidate extraction using modified matched filter. In 2016 13th International Joint Conference on Computer Science and Software Engineering (JCSSE) 2016 Jul 13 (pp. 1-5). IEEE.

[87] Chandran A, Nisha KK, Vineetha S. Computer aided approach for proliferative diabetic retinopathy detection in color retinal images. In 2016 International Conference on Next Generation Intelligent Systems (ICNGIS) 2016 Sep 1 (pp. 1-6). IEEE.

[88] Harini R, Sheela N.
In 2016 Second International Conference on Cognitive Computing and Information Processing (CCIP) 2016 Aug 12 (pp. 1-4). IEEE.

[89] Dutta S, Manideep BC, Basha SM, Caytiles RD, Iyengar NC. Classification of diabetic retinopathy images by using deep learning models. International Journal of Grid and Distributed Computing. 2018 Jan 1; 11(1):89-106.

[90] Mahiba C, Jayachandran A. Severity analysis of diabetic retinopathy in retinal images using hybrid structure descriptor and modified CNNs. Measurement. 2019 Mar 1; 135:762-7.

[91] Tang L, Niemeijer M, Reinhardt JM, Garvin MK, Abramoff MD. Splat feature classification with application to retinal hemorrhage detection in fundus images. IEEE Transactions on Medical Imaging. 2012 Nov 15; 32(2):364-75.

[92] Raju Maher SK, Dhopeshwarkar DM. Review of automated detection for diabetes retinopathy using fundus images. International Journal of Advanced Research in Computer Science and Software Engineering. 2015 Mar; 5(3).

[93] Rahim SS, Palade V, Jayne C, Holzinger A, Shuttleworth J. Detection of diabetic retinopathy and maculopathy in eye fundus images using fuzzy image processing. In International Conference on Brain Informatics and Health 2015 Aug 30 (pp. 379-388).

[94] Yun WL, Acharya UR, Venkatesh YV, Chee C, Min LC, Ng EY. Identification of different stages of diabetic retinopathy using retinal optical images. Information sciences. 2008 Jan 2; 178(1):106-21.

[95] Xu K, Feng D, Mi H. Deep convolutional neural network-based early automated detection of diabetic retinopathy using fundus image. Molecules. 2017 Dec; 22(12):2054.

[96] Islam M, Dinh AV, Wahid KA. Automated diabetic retinopathy detection using bag of words approach. Journal of Biomedical Science and Engineering. 2017 May 10; 10(5):86-96.

[97] Veiga D, Martins N, Ferreira M, Monteiro J. Automatic microaneurysm detection using laws texture masks and support vector machines. Computer Methods in Biomechanics and Biomedical Engineering: Imaging & Visualization. 2018 Jul 4; 6(4):405-16.

[98] Wan S, Liang Y, Zhang Y. Deep convolutional neural networks for diabetic retinopathy detection by image classification. Computers & Electrical Engineering. 2018 Nov 1; 72:274-82.

[99] Miri MS, Mahloojifar A. Retinal image analysis using curvelet transform and multistructure elements morphology by reconstruction. IEEE Transactions on Biomedical Engineering. 2010 Dec 10; 58(5):1183-92.

[100] Ravishankar S, Jain A, Mittal A. Automated feature extraction for early detection of diabetic retinopathy in fundus images. In 2009 IEEE Conference on Computer Vision and Pattern Recognition 2009 Jun 20 (pp. 210-217). IEEE.

[101] Choi JY, Yoo TK, Seo JG, Kwak J, Um TT, Rim TH. Multi-categorical deep learning neural network to classify retinal images: A pilot study employing small database. PLOS one. 2017 Nov 2; 12(11):e0187336.

[102] Wang K, Jayadev C, Nittala MG, Velaga SB, Ramachandra CA, Bhaskaranand M, Bhat S, Solanki K, Sadda SR. Automated detection of diabetic retinopathy lesions on ultra wide field pseudocolour images. Acta Ophthalmologica. 2018 Mar; 96(2):e168-73.

https://sites.google.com/site/ijcsis/
ISSN 1947-5500