Revista
Coleta Científica
ISSN: 2763-6496

REVISTA COLETA CIENTÍFICA

Ano III, Vol. III, n.5, jan.-jun, 2019

ISSN: 2763-6496

DOI: https://doi.org/10.5281/zenodo.4737263

Data de submissão: 12/12/2018. Data de aceite: 20/06/2019.

STRETCH TREATMENT: A RESEARCH FOCUSED ON AESTHETIC BIOMEDICINE

TRATAMENTO DE ESTRIAS: UMA PESQUISA VOLTADA A BIOMEDICINA ESTÉTICA

Cecília Carvalho de Oliveira
Orcid: https://orcid.org/0000-0003-2960-0651
Cenecista Faculty of Rio das Ostras, FACRO, RJ, Brazil
Email: ceciliaoliveira.c@gmail.com

Raquel Chaves
Orcid: https://orcid.org/0000-0002-9534-7730
Cenecista Faculty of Rio das Ostras, FACRO, RJ, Brazil
Email: raquel.chaves@gmail.com

ABSTRACT
Increasingly, the aesthetic procedure has been sought with objectives ranging from personal satisfaction to pathological treatments. Every day new protocols are created, new aesthetic devices and instruments, new cosmetic formulations, all with one purpose: to keep the skin young and free from imperfections. One of the treatments that has been shown to be very efficient in this regard is micropuncture. A technique that consists of damaging the most superficial layers of the skin in order to cause controlled inflammation, and promote the activation of collagen cells. The increase in these cells activates the production of collagen and elastin, substances responsible for the firmness and elasticity of the skin. The micropuncture technique in the treatment of stretch marks andinvestigate the effects.It should be noted that the success of the technique goes beyond epithelial uniformity and, consequently, good tissue aesthetics, with benefits for the patient's self-esteem and personal satisfaction of the professional, who has in his hands the possibility of observing the evident improvement of the patient's skin, as long as hold the knowledge and properly execute the micropuncture. that micropuncture is an effective technique in the treatment of stretch marks, with the reduction in size, in millimeters, provides an improvement in the framework of this dysfunction. Some assets help in the process of formation of collagen and elastin, promoting the filling of the skin, changing its appearance.

KEYWORDS: Micropuncture. Collagen. Microneedling. Treatment.

RESUMO
Cada vez mais o procedimento estético tem sido procurado com objetivos que vão desde a satisfação pessoal a tratamentos patológicos. Todos os dias são criados novos protocolos, novosaparelhos e instrumentos estéticos, novas formulações cosméticas, todas com um só intuito: manter a pele jovem e livre de imperfeições. Um dos tratamentos que tem se mostrado muito eficiente neste quesito é a micropuntura. Uma

Revista
Coleta Científica
ISSN: 2763-6496

REVISTA COLETA CIENTÍFICA

Ano III, Vol. III, n.5, jan.-jun, 2019

ISSN: 2763-6496

DOI: https://doi.org/10.5281/zenodo.4737263

Data de submissão: 12/12/2018. Data de aceite: 20/06/2019.

técnica que consiste em lesionar as camadas mais superficiais da pele afim de provocar uma inflamação controlada, e promover a ativação de células colágenas. O aumento destas células ativa a produção de colágeno e elastina, substâncias responsáveis pela firmeza e elasticidade da pele. A técnica da micropuntura no tratamento das estrias e investigar os efeitos. Convém apontar que o sucesso da técnica vai alémda uniformização epitelial e consequentemente boa estética tecidual, com benefícios para a autoestima do paciente e satisfação pessoal do profissional, que tem em suas mãos a possibilidade de observar a evidente melhora da pele do paciente, desde que detenha o conhecimento e execute adequadamente a micropuntura. que a micropuntura é uma técnica eficaz no tratamento de estrias, com a redução do tamanho, em milímetros, proporciona uma melhora no quadro dessa disfunção. Alguns ativos auxiliam no processo de formação de colágeno e elastina, promovendo o preenchimento da pele, mudando o seu aspecto.

PALAVRAS-CHAVE: Micropuntura. Colágeno. Microagulhamento. Tratamento.

INTRODUCTION

Stretch marks are atrophies of the acquired skin due to the rupture of elastic and collagen fibers, at first reddish and then whitish, there is evidence that their appearance is multifactorial, not only mechanical and endocrinological factors, but also genetic predisposition, leading to the imbalance of the structures that make up the connective tissue. They appear mainly on the thighs, buttocks, abdomen, breasts and back of the trunk. Described as: strips or lines, with depression or elevation of the fabric, in which there is a change in color and texture. Stretch marks appear on the body where the skin has suffered excessive mechanical strength (PEREIRA, AZEVÊDO, TEXEIRA, 2009).

The term stria was first spoken in 1898. Atrophic striations, striae distensae or popularly known as striae, can be defined as a skin degenerative process, which is benign and varies in color according to the evolutionary phase (MONDO, 2004; AMARAL 2008). It is an acquired cutaneous atrophy that has several nomenclatures, vary according to languages, possible etiologies and, aspect of the skin macroscopically analyzed. Clinically, they are characterized by morphology, generally linear, atrophic and superficial and, occasionally, discreetly furrowed, with minimal transverse wrinkles to their largest axis that disappear when drawn (VAZIN, 2011; WHITE, 2007)

1. Structure and function of the skin.

The skin is a covering organ, has a flexible and resistant membrane and is the largest organ in the human body, composed of three layers of tissues: epidermis, dermis and hypodermis. The epidermis is the most superficial layer of the skin, formed by stratified squamous epithelium and stratum corneum, considered the main barrier to permeation. It is a region that has many lipids and keratin, organized in lamellar layers, which end up impairing the diffusion of assets (SILVA, 2010; OGUIDO; SHIBATTA, 2011; LEONARDI, 2004).

Revista
Coleta Científica
ISSN: 2763-6496

REVISTA COLETA CIENTÍFICA

Ano III, Vol. III, n.5, jan.-jun, 2019

ISSN: 2763-6496

DOI: https://doi.org/10.5281/zenodo.4737263

Data de submissão: 12/12/2018. Data de aceite: 20/06/2019.

1.1 Epidermis

The skin is considered to be composed of the epidermis, stratified horny epithelium whose main cellular components are macrophage cells and are involved in various pathologies, such as mycoses and contact dermatitis and cells of the melanic system. These cells are distributed in five epithelial layers. They are: corneal layer (peeling layer), lucid layer (of flattened cells and little apparent nucleus), granular layer (very flattened cells with granular structure) and the keratinization process, spiny layer or Malpighi (composed of polyhedral cells) begins perfectly placed), germ layer (basal layer, composed of young cells that multiply constantly) (JUNQUEIRA, 2004; CHENEIDER, 2009; BORGES 2010)

1.1.1 Dermis

The Dermis is located under the epidermis, a layer where blood vessels, sebaceous glands and nerves are found. Under the dermis, there is also the subcutaneous tissue, formed by fibrous, elastic and fatty tissues. There are four macromolecules produced by mesenchymal cells that are involved in the composition of the dermis: elastin (elastic fibers), proteoglycans, glycosaminoglycans and collagen. The dermis is constituted primarily by a fundamental substance (interstitial), fibers, nerve vessels, in addition to polysaceous follicles and sweat glands. These structures are distributed in three main regions: superficial or papillary dermis, deep or reticular dermis, adventitial dermis (JUNQUEIRA 2004; SCHENEIDER, 2009; SILVA, 2010)

1.1.2 Hypodermis

The hypodermis is extremely important because it fixes the epidermis and dermis to the underlying structures, and is also known as the subcutaneous mesh, subcutaneous tissue or superficial fascia. As mammals consume energy continuously, but feed intermittently, the importance of an energy reservoir, represented by adipose tissue, is understood. The distribution of fat is not uniform in all regions of the body. In normal individuals, some regions never accumulate fat, such as the eyelid, the umbilical scar, the penis, and the folds in the joints. In other regions, on the contrary, there is a greater accumulation of adipose tissue: the proximal portion of the limbs, the abdominal wall, especially the lateral portions (GUIRRO and GUIRRO, 2002).

The hypodermis is related in its upper portion to the deep dermis, constituting the dermo-hypodermic junction, in general, seat of the secretory portions of the apocrine or eccrine glands and of hair, vessels and nerves. Functionally, the hypodermis, in addition to a reserve nutritive deposit, participates in the thermal insulation and in the mechanical protection of the organism against external pressure and trauma and facilitates the mobility of the skin in relation to the underlying structures (LEONARDI, 2008; SAMPAIO; RIVITTI, 2001).

2. HISTOLOGY OF STRETCHES

Revista
Coleta Científica
ISSN: 2763-6496

REVISTA COLETA CIENTÍFICA

Ano III, Vol. III, n.5, jan.-jun, 2019

ISSN: 2763-6496

DOI: https://doi.org/10.5281/zenodo.4737263

Data de submissão: 12/12/2018. Data de aceite: 20/06/2019.

Stretch marks are nothing more than a type of symptom presented by the skin in a state of atrophy, which can be caused by a reduction in the activity of fibroblasts in the production of extracellular matrix and in the rupture of existing fibers. The lesions show loss of elasticity and compaction, but are histologically differentiated from senile lesions or scars, because in them fibroblasts are stellate and in atrophic the predominant fibroblast shape is the globular one, as shown in figure 1 below. For this reason, they are completely different histological alterations, and cannot be compared with any other dermal lesion (VANZIN, 2011; BRAVIM, 2007)

FIGURE 1: illustrative image of the stretch mark scar
Source: Lima, 2010

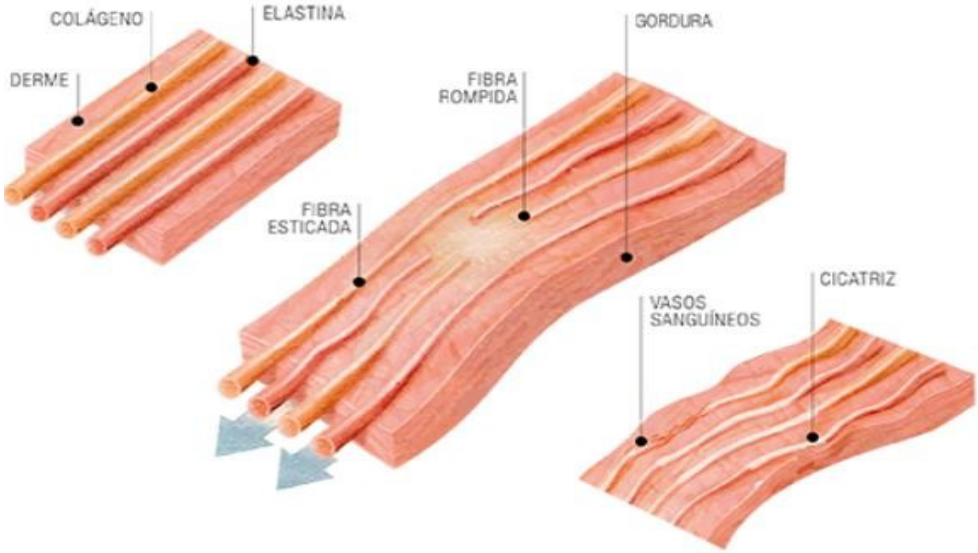

3. MOST COMMON TYPES OF STORY

The most common types of stretch marks are described as follows:

A) Pink: consists of the initial process of formation of healing due to the rupture of blood vessels. Its shape in this phase is reddish, the inflammatory character predominating, and localized edema, swelling and itching may appear. The treatment in this phase shows better results, considering that the cells are still alive and have a greater capacity for regenerative response. (Macedo; 2010)

B) Nacreous: they are older streaks, grayish-white or yellowish in color. They present this formation because the melanin is no longer produced in the place where the fibers break. Its main characteristic is the marked decrease in the thickness of the skin, forming a depression, like a scar, which results in its definition as such. The treatments mainly involve the narrowing and alleviation of depression, although some authors consider that, at this stage, they are not as effective, serving only to improve the appearance of the stretch mark, making it more narrow and reducing its depression. In the words of Guirro and Guirro (2004, p. 392), stretch marks are considered atrophic due to their characteristics of decreasing the thickness of the skin, “[...] due to the

Revista
Coleta Científica
ISSN: 2763-6496

REVISTA COLETA CIENTÍFICA

Ano III, Vol. III, n.5, jan.-jun, 2019

ISSN: 2763-6496

DOI: https://doi.org/10.5281/zenodo.4737263

Data de submissão: 12/12/2018. Data de aceite: 20/06/2019.

reduction in the number and volume of its elements and is represented by thinning, pleating, dryness, less elasticity, thinning of the hair ". In atrophic streaks, it is common to observe aspects of central depression and hypochromia, but with the preservation of skin attachments, such as hair, sweat and sebaceous glands. See below in figure 2. C) Albas: White lesions, depressed and finely wrinkled, look similar to scars; Epidermal atrophy and decreased collagen density. (Guirro and Guirro; 2004, p. 392)

Figure 2: whitish streaks (pearly)
Source:https://clinicapremium.com.br accessed in March 2018

4. SOCIAL IMPACT

In researching some experimental articles, the participants showed psychological distress that provoke reflections on how much an organic problem, considered common, can hinder the experience of the pregnancy or weight loss process. The results also demonstrated the importance of body image for these women, and their relationship with self-esteem. Body image refers to the perception of the image that a person has of his own body and the feelings generated by this perception; it is seen by scholars as an entity in constant self-construction and self-destruction, in constant change, growth and development. Conscious and unconscious processes are involved and experiences, memories, intentions and aspirations are part of it. It also encompasses the relationship with the environment and with the body images of others, as well as the attitudes of others towards their own bodies and their relationships. It is a mental representation that is made of yourself; being plastic and changeable it prints different and individualized meanings. It is strongly conditioned by social standards interfering in behavior, particularly in interpersonal relationships (SCHILDES, 1999; GRIEP and AQUINO, 2012)

The constant search for appropriate resources and techniques to repair connective tissue damaged by stretch marks, in search of alternatives to, if not eradicate, at least minimize the physical and psychosocial consequences of stretch marks (AZEVÊDO, TEIXEIRA and SANTOS, 2009 and PEREIRA, SILVA and SILVA, 2008). Aesthetics is a constant of new means of treatment, especially those that

Revista
Coleta Científica
ISSN: 2763-6496

REVISTA COLETA CIENTÍFICA

Ano III, Vol. III, n.5, jan.-jun, 2019

ISSN: 2763-6496

DOI: https://doi.org/10.5281/zenodo.4737263

Data de submissão: 12/12/2018. Data de aceite: 20/06/2019.

perceive bodily and facial results. In a study by a cosmetics laboratory, it was observed that stretch marks are among the five main causes of female insecurity. Approximately 45% of Brazilian women between 15 and 25 years of age present this aesthetic problem, not only as a result of growth, but also in adulthood, this percentage reaches 80%, mainly because of pregnancy and after menopause,

5. MICROPUNCTURE

The micropuncturewas developed by the Argentine beautician Java Jeiman, in 1989, with the objective of promoting skin stimulation with dermograph and appropriate cosmetics, thus initiating an inflammatory process. collagen and elastin, reconstructing the broken fibers. It is a treatment based on dermocosmetics, such as hyaluronic acid. lactic acid, collagen, vitamin C and growth factors that are applied directly to the area to be treated (NOGUEIRA, 2007, SILVA et al., 2014, CORPO, 2015).

In the micropuncture the demographer is used, a device in the form of a pistol or a pen, weighing 60 grams, containing inside a motor and a transmission shaft, on the outside a base with speed adjustments, a handle, a head and a tip (Figure 4).

Its vibrators provide back and forth movements driven by the transmission shaft that, through the speed base, vary the speed, being changed according to the depth of the skin to be worked, together with a stainless steel needle (measuring 6cm in length) with the plastic support and 0.39mm in diameter) and the plastic guide tip that determines the size of the external needle. The techniques used in the procedure are: Puncture, insertion of the needle in points on the groove without using pressure in the application, not exceeding 0.2 mm in depth, thus, reaching only the papillary dermis, and scarification, sliding over the line of the streak with the needle at a 45º angle (LIMA; LIMA; TAKANO, 2013). Observe in figure 3 below.

FIGURE 3: Photograph of a dermograph device

Revista
Coleta Científica
ISSN: 2763-6496

REVISTA COLETA CIENTÍFICA

Ano III, Vol. III, n.5, jan.-jun, 2019

ISSN: 2763-6496

DOI: https://doi.org/10.5281/zenodo.4737263

Data de submissão: 12/12/2018. Data de aceite: 20/06/2019.

Source: tudobelaestetica.com.br

5.1 Procedure

The procedure is considered to be non-invasive, since the stimulus occurs punctually on top of each stretch mark in isolation, at the superficial level of the skin. Two different types of needles can be used, being a polypropylene needle for scarification (sliding over the striae that will stimulate a local and controlled inflammatory process) or a fine needle with a tip, which will be punctured throughout the stretch mark extension. The puncture, in addition to contributing to the formation of the inflammatory process, promotes the opening of microchannels that facilitate the permeation of important active principles, such as polyhydroxy acids. A great advantage of this technique is that it does not damage the epidermis, as there is no removal of tissue, only disruption, thus the patient's recovery is faster. Observe in figures 4 and 5 (SILVA;

FIGURE 4: Before and after the micropuncture session in pearly streaks.

Revista
Coleta Científica
ISSN: 2763-6496

REVISTA COLETA CIENTÍFICA

Ano III, Vol. III, n.5, jan.-jun, 2019

ISSN: 2763-6496

DOI: https://doi.org/10.5281/zenodo.4737263

Data de submissão: 12/12/2018. Data de aceite: 20/06/2019.

Source: https://clinicadratatianapizani.com.br

FIGURE 5: before and after treatment with micropuncture in white streaks (whitish).

Source: Ligia Lotério (2018)

Revista
Coleta Científica
ISSN: 2763-6496

REVISTA COLETA CIENTÍFICA

Ano III, Vol. III, n.5, jan.-jun, 2019

ISSN: 2763-6496

DOI: https://doi.org/10.5281/zenodo.4737263

Data de submissão: 12/12/2018. Data de aceite: 20/06/2019.

Mechanism of action

The mechanism of action of the technique is divided into three stages: percutaneous collagen induction, healing and maturation. The first stage begins with the loss of fullness of the cutaneous barrier, aiming at the breakdown of keratinocytes, which allows the release of cytokines, such as interleukin and interleukin 1α, the latter predominating. Cytokines promote dermal vasodilation, in addition to the migration of keratinocytes for the purpose of restoring epidermal damage (LIMA; LIMA; TAKANO, 2013).

In the second phase, healing, cell proliferation occurs, that is, the exchange of neutrophils for monocytes, with angiogenesis, epithelialization and proliferation of fibroblasts, subsequent to the production of type III collagen, elastin, glycosaminoglycans and proteoglycans. Simultaneously, TGF - α and TGF - β (fibroblast growth factors) are released by monocytes. On average, five days after the injury, the fibronectin matrix is complete, enabling collagen deposition below the basal layer of the epidermis (LIMA; LIMA; TAKANO, 2013).

And, finally, in the third phase, the maturation phase, there is a slow replacement of type III collagen by type I collagen, which is more durable and can last from five to seven years. The tissue is therefore regenerated and the appearance of the skin is improved. See tables 1 and figure 6 below. (LIMA; LIMA; TAKANO, 2013).

5.3 Phototypes

TABLE 1: Phototype table

Phototypes	Group	Erythema	Pigmentation	Sensitivity
I	White	Always burns	Never tans	Very sensitive
II	White	Always burns	Sometimes you get a tan	Sensitive
III	Light brunette	Moderate burning	Moderate tans	Normal
IV	Brunette moderate	Burns little	Always tans	Normal
V	Dark brunette	Burns rarely	Always tans	Not very sensitive

Revista
Coleta Científica
ISSN: 2763-6496

REVISTA COLETA CIENTÍFICA

Ano III, Vol. III, n.5, jan.-jun, 2019

ISSN: 2763-6496

DOI: https://doi.org/10.5281/zenodo.4737263

Data de submissão: 12/12/2018. Data de aceite: 20/06/2019.

SAW	Black	Never burns	Always pigmented	Insensitive

Source: Callander, 2012

The most famous classification of skin phototypes is the Fitzpatrick scale, created in 1976, by the dermatologist and director of the Dermatology department at the Harvard Medical School, Thomas B. Fitzpatrick. He organized the classification into phototypes according to each person's ability to sunbathe under sun exposure, sensitivity and tendency to turn red under the sun's rays. Fitzpatrick performed this scale from empirical visualizations. (PORTAL, 2015).

Within this Fitzpatrick classification, people who have phototype VI may have hyperpigmentation. Hyperpigmentation occurs due to increased pigmentation of the skin, which takes on a darker color than the original color. It occurs mainly after an injury to the skin, such as a scratch, an acne lesion, inflammation or allergy (RIBEIRO; OHARA, 2002) as shown in figure 8.

FIGURE 6: phototypes



Source: Plena, 2015

Revista
Coleta Científica
ISSN: 2763-6496

REVISTA COLETA CIENTÍFICA

Ano III, Vol. III, n.5, jan.-jun, 2019

ISSN: 2763-6496

DOI: https://doi.org/10.5281/zenodo.4737263

Data de submissão: 12/12/2018. Data de aceite: 20/06/2019.

Hyperpimentation is reversible through the use of depigmentants. They are defined as active ingredients used in industrialized topical preparations that interfere in the synthesis of melanin production, with the purpose of clearing the skin's hyperpigmentations, used in cases such as chloasma, melasma, ephelids, freckles and post-inflammatory hyperpigmentations such as acne blemishes, insect bites, burns, among others. See in figure 7 a case of hyperpigmentation in stretch marks (FRIZO, 2010)

FIGURE 7: Hyperpigmentation in pearly streaks in a phototype IV patient.

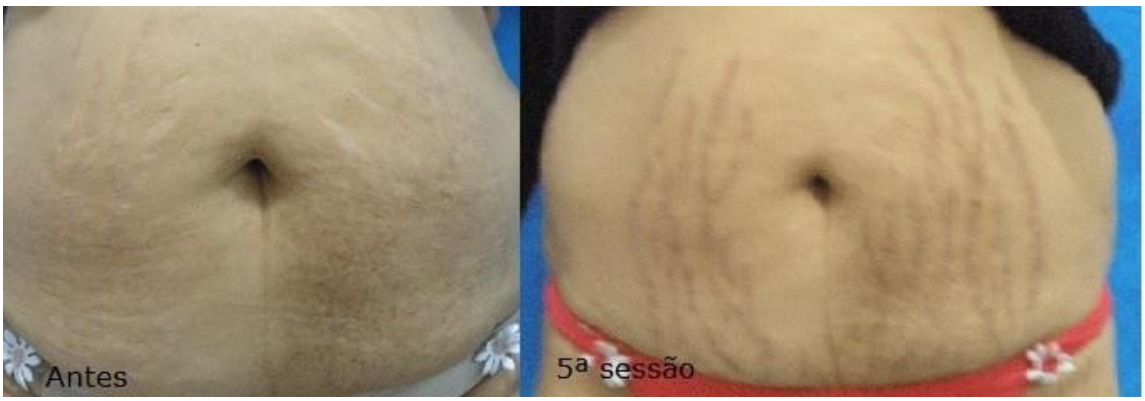

Source: Larissa Veloso Gomes

5.4 Most used assets

With an enhanced effect, the active will direct to a faster and more efficient response of the skin through micro channels that facilitate the absorption of the active effectively, being able to increase the penetration of larger molecules by up to 80%. Thus, it is possible to affirm that the combined action of micropuncture and cosmetic assets can enhance the results (KLAYN; LIMANA; MOARES, 2012; GARCIA, 2013; PIATTI, 2013).

TABLE 2: most used assets in microneedling procedures, the following stand out:

Revista
Coleta Científica
ISSN: 2763-6496

REVISTA COLETA CIENTÍFICA

Ano III, Vol. III, n.5, jan.-jun, 2019

ISSN: 2763-6496

DOI: https://doi.org/10.5281/zenodo.4737263

Data de submissão: 12/12/2018. Data de aceite: 20/06/2019.

Vitamin C	Powerful antioxidant that increases levels of pro-collagen messenger RNA types I and III.
Vitamin A	Stimulates the production of fibroblasts.
Vitamin B3	Used in the treatment of hyperchromias.
Copper Peptides	Required at synthesis in collagen performed by fibroblasts.
Zinc	Required at synthesis in elastin and collagen production.
Growth Factors	They are released by the body after micropuncture, but they can also be inserted into the skin.

Source: information searched by the author

6. BACKGROUND

Stretch marks usually occur from a mechanical process of the skin, such as pregnancy and weight loss. This event impairs the appearance of the skin, which starts to present a scar on its surface. When it comes to minimizing the scars on the skin, treatment options in aesthetic offices and clinics abound.

Dermatology and aesthetics are making great strides in the field of beauty and the secret is to choose a reliable clinic and, above all, a professional duly qualified with a specialist title by the Brazilian Society of Aesthetic Biomedicine (SBBME) or Brazilian Society of Dermatology (SBD) , who will prescribe the best treatment protocol for each patient, taking into account the individuality of each patient. These are the most qualified professionals to carry out the procedures mentioned in their resolutions. Micropuncture is a procedure that recently arrived in Brazil and has already given us something to talk about. Its effects are fantastic, as mentioned, it improves the scars of stretch marks by promoting the replacement of collagen and elastin and improving them until they are imperceptible. This new treatment procedure is now considered the gold standard for stretch marks. It is important that the equipment is registered with the National Health Surveillance Agency (ANVISA). This certification guarantees the quality of the product, for example, in relation to the steel used, number of needles, length and diameter of the needles, the sterilization of the same and thus avoiding contamination and complications. The importance of looking for a qualified professional, an appropriate place for the patient to perform the procedure is essential, as patients with problems already mentioned are contraindicated. number of needles,

Revista
Coleta Científica
ISSN: 2763-6496

REVISTA COLETA CIENTÍFICA

Ano III, Vol. III, n.5, jan.-jun, 2019

ISSN: 2763-6496

DOI: https://doi.org/10.5281/zenodo.4737263

Data de submissão: 12/12/2018. Data de aceite: 20/06/2019.

length and diameter of the needles, sterilization of the same and thus avoiding contamination and complications. The importance of looking for a qualified professional, an appropriate place for the patient to perform the procedure is essential, as patients with problems already mentioned are contraindicated. number of needles, length and diameter of the needles, sterilization of the same and thus avoiding contamination and complications. The importance of looking for a qualified professional, an appropriate place for the patient to perform the procedure is essential, as patients with problems already mentioned are contraindicated.

7. GOALS

The objective of this study is to point out the success of the micropuncture technique in the treatment of stretch marks and investigate the effects. It should be noted that the success of the technique goes beyond epithelial uniformity and, consequently, good tissue aesthetics, with benefits for the patient's self-esteem and the personal satisfaction of the professional, who has in his hands the possibility of observing the evident improvement of the patient's skin, provided that hold the knowledge and properly execute the micropuncture. Even with the success of the technique, in Brazil, there is not a high number of researches about its benefits, the intention of this research is to add positively the micropuncture technique in stretch marks and show its benefits.

The present study has the specific objective of describing the mechanism of action of micropuncture in stretch marks and also gathering scientific data that prove the effectiveness of the treatment.

8. METHODOLOGY

The methods used in this research are based on bibliographic research, aiming to expose important points about the micropuncture technique. Articles from the Scielo, Surgical and cosmetic Dermatology, google scholar, PubMed databases were used between March and November 2018.

Revista
Coleta Científica
ISSN: 2763-6496

REVISTA COLETA CIENTÍFICA

Ano III, Vol. III, n.5, jan.-jun, 2019

ISSN: 2763-6496

DOI: https://doi.org/10.5281/zenodo.4737263

Data de submissão: 12/12/2018. Data de aceite: 20/06/2019.

9. RESULTS AND DISCUSSION

TABLE 3: from the analyzed articles we have:

Author and Year	Objective of the study	Results of
LIMA, EV A .; LIMA, M A .; TAKANO, D. (2013).	Elucidate the mechanism of action of the microneedling technique.	It was verified the use of microneedling as a way of conveying assets with Retinol and Vitamin C
ADY AUST AND VOGT (2010)	The effectiveness of the percutaneous collagen induction technique in stretch marks.	For the study, 22 female people underwent the application of the technique and resulted in an improvement in the overall appearance of the skin.
LANGE, AN; COSTA, R .; BUENO, JS	Treatment of striated skin using the microneedling method.	They showed positive results after performing 6 treatment sessions.
LANGE; COSTA E BOENO (2013)	Association of microneedling with growth factors in atrophic stretch marks	They obtained a positive result after nine sessions, proving to be effective.
FLAG OF MELLO (2014)	Improvement in the striated area being noticeable to patients after treatment.	On a satisfaction scale of 1 to 10 where the majority of patients reported being satisfied with the treatment after two sessions were held.
RIBEIRO(2002)	To verify the effectiveness of the microneedling technique in patients with high phototypes.	It was found that people who have phototype VI, may have hyperpigmentation.

Revista
Coleta Científica
ISSN: 2763-6496

REVISTA COLETA CIENTÍFICA

Ano III, Vol. III, n.5, jan.-jun, 2019

ISSN: 2763-6496

DOI: https://doi.org/10.5281/zenodo.4737263

Data de submissão: 12/12/2018. Data de aceite: 20/06/2019.

KLAYN; LIMANA; MORAES; GARCIA PATITI. (2012; 2013).	To verify the effectiveness of this technique in conjunction with the permeation of assets.	There was a significant improvement after three microneedling sessions with 15-day intervals associated with an asset complex.

Through this literature review, based on 20 articles from which they were researched, the authors report the success and the importance of percutaneous collagen induction in the micropuncture technique in stretch marks associated or not with assets, according to the classification of skin phototypes. suggests that the higher the phototype, the greater the risk of hyperpigmentation, so the technique does not provide a significant improvement in cases of phototype VI. Although in recent years the use of the technique to soften stretch marks has increased, the micropuncture technique and the publication of scientific papers on the subject is still recent, which makes it difficult to compare them.

For Fabbrocini, (2009) the needles need to penetrate more deeply to stimulate the production of elastic fibers from the deep layers of the dermis towards the surface.

According to Lima (2013), the technique promotes advantages and disadvantages, as it states that the main positive points are: stimulating the production of collagen without removing the epidermis; healing time is shorter, with less risk of side effects to ablative techniques; low cost when compared to procedures that require technologies with high investment. And the points considered by him to be negative are: technical procedure that requires training; recovery time if moderate to profound injury is indicated.

According to Doddaballapeer (2009) the micro lesions caused on the skin, stimulate the production of collagen, generating an inflammatory process, increasing the synthesis of collagen, elastin and other substances present in the tissue, restoring the integrity of the skin. According to Lima et. al., 2013 microneedling makes the skin thicker and more resistant, in addition to having a shorter healing time compared to other treatments. It also assists in the permeation of assets, such as the growth factor, contributing to a significant improvement in treatment.

10. CONCLUSION

In the research conducted here, one can observe the mechanism of action of the microneedling technique, the reduction of the social impact on the lives of patients who have stretch marks, that micropuncture is an effective technique in the treatment of stretch marks, with the reduction of size, in millimeters, provides an improvement in the framework of this dysfunction. Some assets help in the process of formation of collagen and elastin, promoting the filling of the skin, changing its aspect, what could

Revista
Coleta Científica
ISSN: 2763-6496

REVISTA COLETA CIENTÍFICA

Ano III, Vol. III, n.5, jan.-jun, 2019

ISSN: 2763-6496

DOI: https://doi.org/10.5281/zenodo.4737263

Data de submissão: 12/12/2018. Data de aceite: 20/06/2019.

be observed during the research is that according to the classification of skin phototypes, it is concluded that the higher the phototype, the greater the risk of hyperpigmentation, so the technique does not provide a significant improvement in cases of high phototype, as it has the risk of post-inflammatory hyperchromia even though it is reversible, the depigmentation process is slow. Measures may be adopted by esthetic biomedicals to improve this dysfunction. There are studies on the treatment with growth factors, some biomedical esthetes and use the technique associated with a mixture of compounds, as it helps in improving the technique. It was concluded that the micropuncture technique is effective, has low cost and low risk of side effects.

11. REFERENCES

BORGES, FS Dermato-functional: Therapeutic modalities in aesthetic dysfunctions. 2. ed. Sao Paulo: Phorte, 2010

FABBROCINI, Gabriella; DE PANDOVA, Maria Pia; DE VITA, Valerio; FARDELLA, Nunzio; PASTORE, Francesco; TOSTI, Antonella. Treatment of periorbital wrinkles by collagen induction therapy, Surgical & CosmeticDermatology. Vol. 1, no. 3, pp. 106-111 2009.

GUIRRO, ECO; GUIRRO, RRJ Dermato - functional physiotherapy: fundamentals, resources, pathologies. 3rd ed. Barueri, 2004.

KS; ROSAS, RF Effects of galvanic current in the treatment of atrophic streaks. [2004?]. 6 f. Course Conclusion Paper (Physiotherapy) - University of Southern Santa Catarina, Tubarão, 2004.

LIMA, EV A .; LIMA, M A .; TAKANO, D. Microneedling: experimental study and classification of the injury caused. Surg Cosmet Dermatol. Recife, 2013.
Griep RH, Aquino EML, Chor D, Kakeshita IS, Gomes ALC, Nunes MAA. Test-retest reliability of scales of body self-image silhouettes in the Longitudinal Study of Adult Health. Cad. Public Health. 2012; 28 (9). [accessed 3 sep 2013]. Available: http: // dx.doi.org/10.1590/S0102-311X2012000900017

LEONARDI, Gislaine Ricci. Applied Cosmetology. 1. ed. São Paulo: Medfarma, 2004

LANGE, AN; COSTA, R .; BUENO, JS Treatment of striated skin using the microneedling method associated with the use of rosehip oil. In: RESEARCH SEMINAR AND SCIENTIFIC INITIATION SEMINAR, 11., 2013, Curitiba. Notebook of Summaries, Curitiba, 2013. p. 76. Available at:. Accessed on: 8 May 2015.

MACEDO, OR Striae, damage to the skin. 2010. Available at: Accessed on: 28 ago. 2011. MAIO, M. Aesthetic Medicine Treaty. 2. ed. 3. vol. São Paulo: Roca, 2011. 3. MONDO, P. NEGRÃO, Mariana CP Microneedling: physiological and practical bases.

Revista
Coleta Científica
ISSN: 2763-6496

REVISTA COLETA CIENTÍFICA

Ano III, Vol. III, n.5, jan.-jun, 2019

ISSN: 2763-6496

DOI: https://doi.org/10.5281/zenodo.4737263

Data de submissão: 12/12/2018. Data de aceite: 20/06/2019.

CR8 Editora, 2015.

OIL, DERMA. Your DERMA OIL spline reducer. AVAILABLE IN:www.tractamentoparaestrias.comAccessed on 03 March. 2010.

OGUIDO, Cristina Miyuki Kimura; SHIBATTA, Lenice Souza. Permeability of Assets in Cosmetology. V Multiprofessional Health Congress - Elderly Care. June 28 to 30, 2011. p. 1 - 4

PIATTI, IL Microneedling and growth factors. Personalité Magazine, São Paulo, year 16, n. 8, p. 22-25, 2013

PEREIRA, LMBN et al. D. Effect of dermotonia on the treatment of stretch marks. Ser Physiotherapy, Rio de Janeiro, Vol. 2, n. 2, p. 145-147, 2007. PEREIRA, LMBN; SILVA, ID;

SILVA, TV The effect of galvanic microcurrent in the treatment of atrophic streaks. Ser Physiotherapy, Rio de Janeiro, Vol. 3, n. 4, p. 242-246, 2008.

SILVA, CR; OLIVEIRA, DF Action of the red laser in a protocol for nacreous streaks. Camboriú: UNIVALI, 2010.

SILVA, AMR; ANDRADE, KF; VIEIRA, SL Acupuncture in Functional Dermato Physiotherapy on the Face. Sobrafisa, 2004.

SHENEIDER, Aline Petter. Aesthetic nutrition. Sao Paulo. Atheneu, 2009.
Schilder PA. Body image: the constructive energies of the psyche. São Paulo: Martins Fontes; 1999. 9.

SILVA, JA; APOLINÁRIO, AC; SOUZA, MSR; DAMASCENO, BPGL; MEDEIROS, ACD Cutaneous Drug Administration: Challenges and Strategies for the Development of Transdermal Formulations. Journal of Basic and Applied Pharmaceutical Sciences, Paraíba: 14/09/2010. p 125-131

SABATOVICH, O. Aesthetic Dermatology. São Paulo: Atheneu, 2004.

RIBEIRO, C; OHARA, MT Localized hyperpigmentation of the skin. Racine Magazine, São Paulo, Vol. 67, p. 62- 66, Mar / April, 2002.
WHITE, PAS et al. Effects of galvanopuncture in the treatment of atrophic stretch marks. 2007. 12
f. Monograph (Specialization in Dermato-functional Physiotherapy) - University of Ribeirão Preto, São Paulo, 2007. 10.KEDE, MPV;
VANZIN, SB; CAMARGO, CP Understanding Cosmeceuticals: Diagnostics and Treatments. São Paulo: Santos, 2011. 9.