



CODEN [USA]: IAJPBB

ISSN: 2349-7750

**INDO AMERICAN JOURNAL OF
PHARMACEUTICAL SCIENCES**Available online at: <http://www.iajps.com>

Research Article

**INCREASED EFFECTIVENESS USEFULNESS OF DILATATION
WITH INTRALESIONAL STEROID INJECTIONS IN
CORROSIVE OESOPHAGEAL STRICTURES TREATMENT****¹Dr. Amir Akram, ²Dr. Waqas Ahmad, ³Dr. Muhammad Ali Rathorde
¹UHS, Lahore.****Article Received:** January 2019**Accepted:** February 2019**Published:** March 2019**Abstract:**

Objectives: The research objective is the comparison of the effectiveness of intralesional steroid injection with dilatation VS with dilatation only while treating corrosive oesophageal strictures.

Method: We conducted this randomized controlled trial at Services Hospital, Lahore (October 2017 to November 2018). We took 60 patients (15 – 50) years' age having either gender and divided them into two groups; Group-A and Group-B using lottery method. We performed endoscopic dilatation in Group-A and Intra-lesional Triamcinolone injection with dilatation in Group-B. We followed-up the endoscopic dilatation for every 02 weeks. Using SPSS software, we analyzed the collected data.

Results: We took 60 patients, dividing into two groups, each consisting of an equal number (30 or 50%) of patients. We recorded the overall mean age as (32.6 ± 10.6) years among all patients with (1.7:1) of male to female ratio. The mean stricture length at baseline of Group-A (dilatation) and Group-B (combination) was $(23.3 \pm 2.2 \text{ cm})$ and $(24.2 \pm 3 \text{ cm})$ respectively. The mean length of stricture in Group-A and Group-B was $(11.2 \pm 3 \text{ cm})$ and $(5.33 \pm 3 \text{ cm})$ respectively with $(P\text{-value} = 0.0001)$.

Conclusion: The combination group (Oesophageal + dilatation) was more effective comparing to dilatation only group.

Keywords: Intra-lesional Steroid Injection (ILSI), Corrosive Oesophageal Strictures (COS), Stricture Length (SL), and Oesophageal Strictures (OS).

Corresponding author:

Dr. Amir Akram,
UHS, Lahore.

QR code



Please cite this article in press Amir Akram et al., **Increased Effectiveness Usefulness Of Dilatation With Intralesional Steroid Injections In Corrosive Oesophageal Strictures Treatment.**, Indo Am. J. P. Sci, 2019; 06(03).

INTRODUCTION:

OS is one of the common clinical problems in gastroenterology. The narrowing of oesophagus causes OS which makes swallowing difficult. Benign and Malignant are the major two types of OS. Several causes result benign but carcinoma is the only cause of malignant [1]. The common-most aetiologies of benign include peptic injury, radiation damage, anastomotic strictures, caustic swallowing, oesophageal webs and GERD (Gastrointestinal Reflux Disease). Corrosive intake, being a vital health issue among developed countries, is still an increase in incidence among the developing countries. Due to a large unreported number, the actual prevalence rate is unknown and cannot be figured out because of insufficient data and less personal experience [2]. By contacting the body, corrosive materials can damage tissues. Cleaning metal is its utility in usual. Getting it swallowed intentionally/accidentally causes a great health hazard. It is the 3rd common-most poisoning cause among adults according to epidemiological studies [3]. Progressive dysphagia to solids that later causes liquid intake intolerable is a common symptom of OS. Biopsy, endoscopy and barium swallow are the ways to diagnose such strictures. The most applicable treatment of OS is endoscopic dilatation, and PPIs (Proton Pump Inhibitors) inhibit acid production [4]. If solid food still does not swallow through oesophagus and recurrence happen repeatedly, then surgery becomes the next option [5]. Many studies conclude that using ILSIs are better option to add with standard treatment while treating OS. According to International Literature shows that due to its anti-inflammatory action, ILSIs can help in diameter increase [6]. But some studies show that ILSIs do not reduce the dilatation frequency [7]. Some studies showed ILSIs use in treating benign OS that showed resistance to bougie dilatation [8]. A study shows 100% success rate using corticosteroid injections with dilatation [9]. A local study shows 60% success rate with dilatation-alone [10]. Due to limited data available about ILSIs, it's not in routine practice during COS dilatation. The present research aimed to study the ILSIs role used with dilatation in improving the length of strictures in COS.

PATIENTS AND METHODS:

We conducted this randomized controlled trial at Services Hospital, Lahore (October 2017 to November 2018). We took approval from the Institutional Review Board. We calculated the sample size using significance level with symptomatic improvement percentage, dilatation-alone, dilatation combined, and power of study with the percentages of 5%, 60%, 100%, and 80% respectively. We took written consent

from each patient. Our selection criteria included patients of both genders, of (15-50) years' age group, and had COS (having ingested corrosive material which resulted in OS (10 mm) observed through barium swallow that caused difficulty in the passing endoscope in upper gastrointestinal-region). We excluded patients with a history of malignant disease, congenital strictures, peptic ulcer diseases, achalasia cardia and repetitive endoscopic band ligation resulting in strictures. We administered the barium meal and barium swallow for the assessment of length and site of stricture and oesophageal lumen's contraction degree. We divided patients into two groups; Group-A (dilatation) and Group-B (Combination). In Group-A, we did dilatation-only. In Group-B, we did dilatation with (0.5 cc per quadrant triamcinolone) using gauge 23, sclerotherapy needle (5 mm long). We increased dilatation by 3 mm each new session till we reached 15 mm in diameter. We gave all patients PPI regimen (standardized) of omeprazole (40 mg intravenous-IV) once a day. We kept a 14-day follow-up until there are no symptoms left. To assess the treatment success, we used Grade-0, Grade-1, Grade-2, Grade-3, and Grade-4 that denoted normal diet, unable to swallow solid food, semi-solid food can swallow only, and cannot tolerate liquids respectively [11]. We considered Grade-0 and (> 15 mm diameter) of the widened oesophagus in three months as successful. We analyzed data using SPSS. We compared both groups' effectiveness of treatment using independent-sample T-test and considered (P-value = ≤ 0.05) as statistically significant.

RESULTS:

We selected 60 patients dividing them into Group-A (dilatation) and Group-B (Combination), each consisting of 50% (30) patients. The mean age in Group-A and Group-B was (32.7 ± 10.2) and (32.7 ± 11.1) years respectively (P-value = 0.9338). The number of male and female patients in Group-A was 60% (18) and 40% (12) and Group-B as 66.6% (20) and 33.3% (10) respectively (P-value = 0.5990). In Group-A, we found 80% (24) and 20% (06) patients with acid and alkali substance intake respectively. There was no significant difference in both groups relative to post-intervention symptoms. The mean length of stricture at baseline of Group-A and Group-B was (23.3 ± 2.2 cm) and (24.2 ± 3 cm) respectively with (P-value = 0.1871). After three months, the mean length of stricture at baseline of Group-A and Group-B was (11.2 ± 3 cm) and (5.3 ± 3 cm) respectively with (P-value = 0.0001). We also studied complications at post-procedure and symptoms in both groups. Group-

B achieved a decreased length of stricture as a primary outcome with (P-value = 0.0001).

Table – I: Baseline Features of Gender and Corrosion

Baseline Features		Dilatation (30)	Dilatation + Steroid (Combination Group) (30)	Total (60)	P-Value
Gender	Male	18	20	38	0.5990
	Female	12	10	22	
Corrosion Type	Acid	24	19	43	0.1547
	Alkali	6	11	17	0.1556

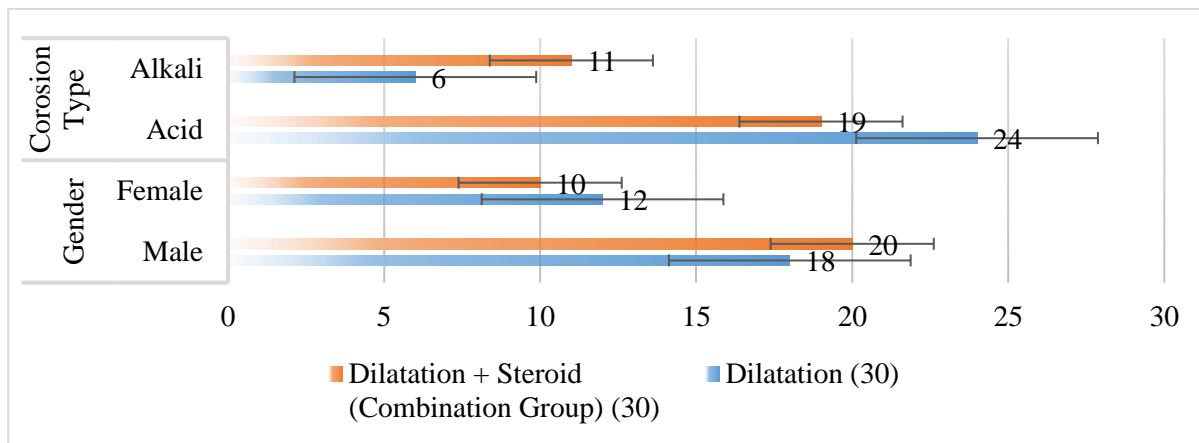


Table – II: Various Baseline Features (Mean and SD Values)

Baseline Features	Dilatation (30)		Dilatation + Steroid (Combination Group) (30)		Total (60)		P-Value
	Mean	±SD	Mean	±SD	Mean	±SD	
Mean Age (Years)	32.7	10.2	32.47	11.13	32.58	10.58	0.9338
Pulse (bpm)	75.5	8.8	75.47	8.86	75.48	8.75	0.9895
Blood Pressure (mmHg)	128.5	13.34	130	12.53	129.25	12.84	0.6552
Temp (oF)	99.3	0.44	99.3	0.44	99.3	0.44	1.0000
Respiratory Rate (rpm)	12.5	1.74	12.5	1.74	12.5	1.74	1.0000
Hb (g/L)	12.33	0.75	12.02	0.68	12.17	0.73	0.0989
Platelet (x103)	242.67	63.3	248.33	55.28	245.5	58.98	0.7136
Weight (kg)	67.8	8.53	66.8	10.84	67.3	9.68	0.6928

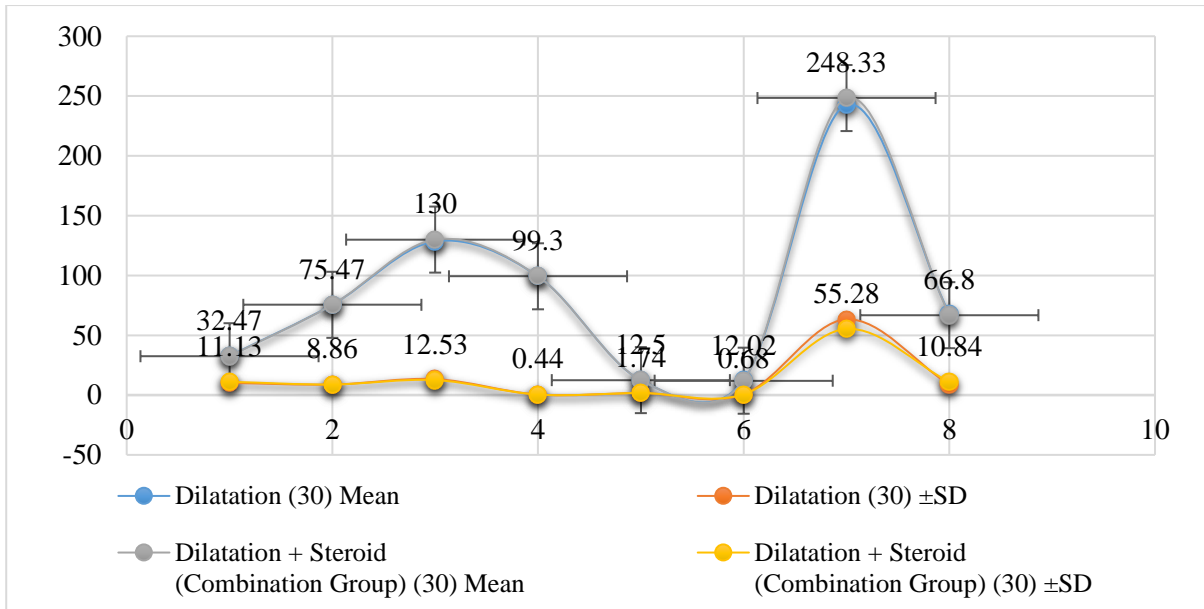


Table – III: Stratification of Symptoms

Symptoms	Dilatation (30)	Dilatation + Steroid (Combination Group) (30)	Total (60)	P-Value
Dysphagia	20	26	46	0.067
Odynophagia	20	26	46	0.067
Vomiting	21	21	42	> 0.999
Weight Loss	25	28	53	0.424
Chest Pain	8	13	21	0.176
Back Pain	7	5	12	0.519
Voice Harshness	25	28	53	0.228
Dyspnea	19	20	39	0.787

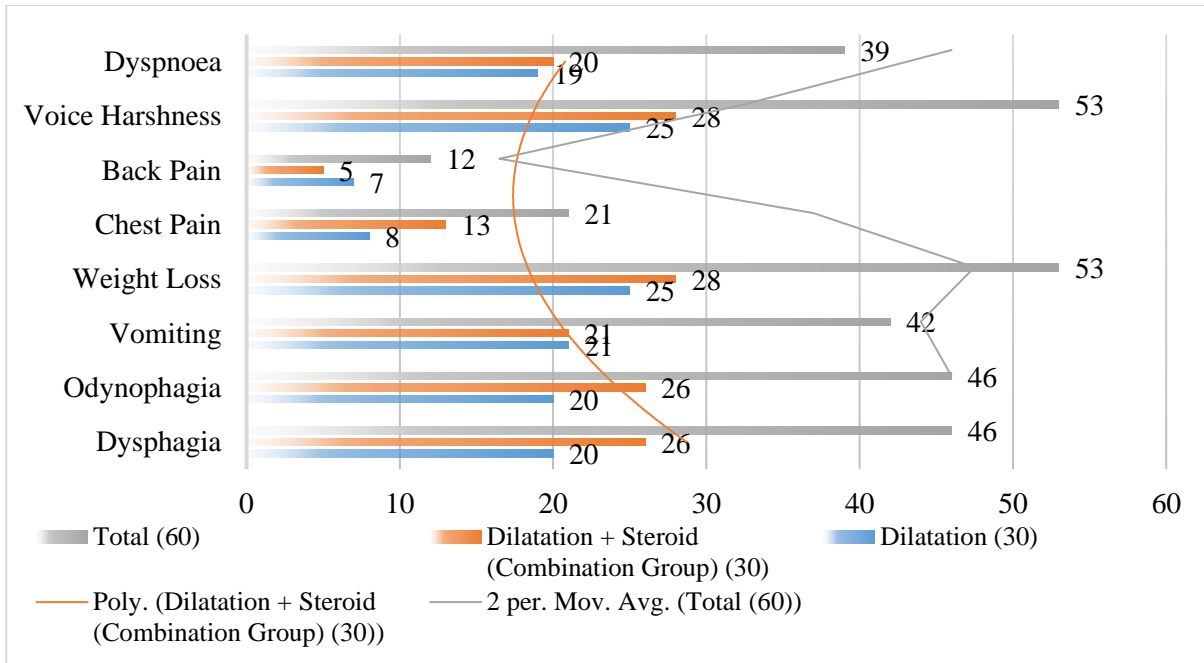
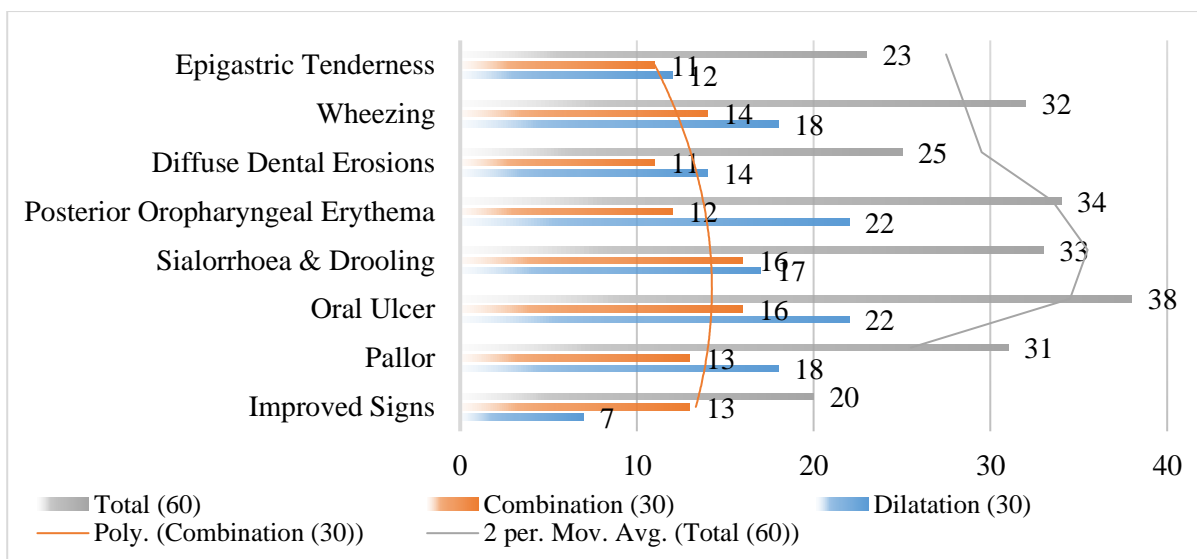


Table – IV: Stratification of Improved Symptoms

Improved Symptoms	Dilatation (30)	Combination (30)	Total (60)	P-Value
Improved Signs	7	13	20	0.100
Pallor	18	13	31	0.196
Oral Ulcer	22	16	38	0.108
Sialorrhea & Drooling	17	16	33	0.795
Posterior Oropharyngeal Erythema	22	12	34	0.009
Diffuse Dental Erosions	14	11	25	0.432
Wheezing	18	14	32	0.301
Epigastric Tenderness	12	11	23	0.791



DISCUSSION:

According to reports, ILSI along with dilatation prevents recurrence of the stricture. This addition in the management of OS has produced improved results among peptic strictures' patients since 1966. Nonetheless, there were not enough studies with control and sampling. Moreover, there are limited Randomized-Controlled-Trials having a small sampling size [12]. Our study achieved insignificant outcomes relative to symptoms and parameters of complications after the procedure. However, there was significant difference relative to posterior oropharyngeal erythema among the patients of both groups (less number of patients from Group-A, and more from Group-B) (P-value = 0.009). Initially, researchers tried ILSIs on animals for verification where they established the effectiveness of dilatation with steroid therapy [13]. The researches made factual establishment that ILSIs used with endoscopic dilatation boost the outcome in the management of OS [2]. Therefore, ILSIs are suggested a must-to-be while dealing with complex structures [14]. A study shows that subsequent Intralesional (10 mg triamcinolone) injections used with oesophageal dilatation increased the diameter of stricture in corrosive ingestion [15]. Various studies show the increased effectiveness of ILSIs with dilatation in dealing with different benign OS [16]. An observational study concludes steroid intervention with oesophageal dilatation with improvement in dysphagia [17]. A trial study shows ILSIs' extreme usefulness in the management of OS resistant to dilatation [18]. A Randomized-Controlled-Trial demonstrates superior results using ILSIs with dilatation comparing to dilation-only while treating peptic strictures with 13% and 60% rates of redo dilatation in steroid dilatation group and control group

respectively (P-value = 0.010) [19]. A study reported a 100% successful outcome of corticosteroid injection used with dilatation [9]. A local study showed a 60% success rate at the outcome with dilatation-only [10]. A Randomized-Controlled-Trial showed single ILSI followed by endoscopic dilatation producing favourable results while inhibiting OS cancer. Previous research also suggests ILSIs' usefulness in improving the effectiveness of endoscopic dilatation [9, 21]. However, some cases with unmanageable strictures are an exception for ILSIs with endoscopic dilatation combination [1, 22]. Our study comes with some limitations. First, the study was single-centre, even though most of the OS patients receive treatment here is one of the capable tertiary-care facilities in this region. Moreover, the outcome of our study is generalized to OS caused by corrosive intake only. Further studies are required to measure its effectiveness for other stricture causes (benign/malignant). Lastly, there was no blinding process relative to intervention among both groups. The study outcome recommends the use of ILSIs followed by dilatation for COS to achieve an improved outcome in terms of dilatation.

CONCLUSION:

The combination group produced improved results in terms of reduced stricture length comparing to the dilatation-only group. There was a significant difference observed in the outcome of both groups.

REFERENCES:

1. Altintas E, Kacar 5, Tunc B, Sezgin 0, Parlak E, Altiparmak E, et al. Intralesional steroid injection in benign oesophageal strictures resistant to

- bougie dilation. *J Gastroenterol Hepatol.* 2004; 19:1388-91.
2. Ramage II, Rumalla A, Baron TH, Pochron NL, Zinsmeister AR, Murray JA, et al. A prospective, randomized, double-blind, placebo-controlled trial of endoscopic steroid injection therapy for recalcitrant oesophageal peptic strictures. *Am J Gastroenterol.* 2005; 100:2419-25.
 3. Hanaoka N, Ishihara R, Takeuchi Y, Ueda N, Higashino K, Ohta T, et al. Intralesional steroid injection to prevent stricture after endoscopic submucosal dissection for oesophageal cancer: a controlled prospective study. *Endoscopy.* 2012; 44:1007-11.
 4. Lee M, Kubik OM, Polhamus CD, Brady III CE, Kadakia SC. Preliminary experience with endoscopic intralesional steroid injection therapy for refractory upper gastrointestinal strictures. *Gastrointest Endosc.* 1995; 41:598-601.
 5. Hishiki T, Kouchi K, Saito T, Terui K, Sato Y, Mitsunaga T, et al. Successful treatment of a severe refractory anastomotic stricture in an infant after oesophageal atresia repair by endoscopic balloon dilation combined with systemic administration of dexamethasone. *Pediatr Surg Int* 2009; 25: 531-3.
 6. Ravich WJ. Endoscopic Management of Benign Oesophageal Strictures. *Curr Gastroenterol Rep.* 2017; 19:50.
 7. Nijhawan S, Udawat HP, Nagar P. Aggressive bougie dilatation and intralesional steroid injections are effective in refractory benign oesophageal strictures secondary to corrosive ingestion. *Dis Oesophagus.* 2016; 29:1027-31.
 8. Poincloux L, Rouquette O, Abergel A. Endoscopic treatment of benign oesophageal strictures: a literature review. *Expert Rev Gastroenterol Hepatol.* 2017; 11:53-64.
 9. Kochhar R, Makharia GK. Usefulness of intralesional triamcinolone in the treatment of benign oesophageal strictures. *Gastrointest Endosc.* 2002; 56: 829-34.
 10. Rehman S, Hameed K, Khan IM. Endoscopic dilatation for caustic oesophageal strictures. *J Postgrad Med Inst.* 2007; 21: 292-95.
 11. Gramigna GD. How to perform video-fluoroscopic swallowing studies. *GI Motility.* [online] 2006 [cited 2007 Mar 12]. Available from: <https://www.nature.com/gimo/contents/ptl/full/gimo95.html> URL:
 12. Van Boeckel PGA, Siersema PD. Refractory Oesophageal Strictures: What to Do When Dilation Fails. *Curr Treat Options Gastroenterol.* 2015; 13:47-58.
 13. Kochhar R, Ray JD, Sriram PV, Kumar S, Singh K. Intralesional steroid injections augment the effects of endoscopic dilation in corrosive oesophageal strictures. *Gastrointest Endosc.* 1999; 49:509-13.
 14. Shah JN. Benign refractory oesophageal strictures: widening the endoscopist's role. *Gastrointest Endosc.* 2006; 63:164-7.
 15. Camargo MA, Lopes LR, Grangeia TAG, Andreollo NA, Bran realise NA. Use of corticosteroids after oesophageal dilations on patients with corrosive stenosis: prospective, randomized and double-blind study. *Rev Assoc Med Bras (1992).* 2003; 49:286-92.
 16. Groth S, Odell D, Luketich J. Oesophageal Strictures Refractory to Endoscopic Dilatation. In: Pawlik T, Maithel S, Merchant N, eds. *Gastrointestinal Surgery.* New York, NY: Springer, 2015.
 17. Orive-Calzada A, Bernal-Martinez A, Navajas Laboa M, Torres-Burgos S, Aguirresarobe M, Lorenzo-Morote M, et al. Efficacy of intralesional corticosteroid injection in endoscopic treatment of oesophageal strictures. *Surg Laparosc Endosc Percutan Tech.* 2012; 22:518-22.
 18. Morikawa N, Honda T, Kuroda T, Watanabe K, Tanaka H, Takayasu H, et al. High dose intravenous methylprednisolone resolves oesophageal stricture resistant to balloon dilatation with intralesional injection of dexamethasone. *Pediatr Surg Int.* 2008; 24:1161-4.
 19. Contini S, Scarpignato C. Caustic injury of the upper gastrointestinal tract: a comprehensive review. *World J Gastroenterol.* 2013; 19:3918-30.
 20. Mowry JB, Spyker DA, Cantilena LR Jr, McMillan N, Ford M. 2013 Annual Report of the American Association of Poison Control Centers' National Liaison Data System (NPDS): 31st annual report *Clin Toxicol (Phila).* 2014; 52:1032-283.
 21. Park KS. Evaluation and management of caustic injuries from ingestion of Acid or alkaline substances. *Clin Endosc.* 2014; 47: 301-7.
 22. Kluger Y, Shay OB, Sartelli M, Katz A, Ansaloni L, Gomez CA, et al. Caustic ingestion management world society of emergency surgery preliminary survey of expert opinion. *World J Emerg Surg.* 2015; 10:48.