There seemed to be some increase in the swelling, the tissues felt more infiltrated, and the patient complained of considerable pain.

The second injection was given March 24, after which no reaction followed. Improvement had, however, already appeared in the lesion. The swelling was gradually subsiding, March 30, when the last injection was given.

The patient was discharged, May 13, entirely free of the disease.

The results in these two cases have been striking and, of course, far superior and far more quickly obtained than by any other method we have heretofore used.

DECOMPRESSION CRANIOTOMY IN BULLET WOUND OF BRAIN AND HEMIPLEGIA

Junius Hardin McHenry, M.D., New York
Associate Neurologic Surgeon, Polyclinic Medical School and Hospital

History.—D. M., man, aged 74, born in Ireland, of small stature, weight 120 pounds, was brought to the Polyclinic Hospital in the evening of Jan. 16, 1916. He was perfectly conscious, and gave his history frankly without showing any great excitement or any evidences whatever of shock. He said that two men entered his small basement store and at the point of a revolver demanded money. He gave them what he had, and in leaving, one of them fired at him, striking him in the face just below the left eye. Almost immediately he lost the sight of the left eye.

Examination.—Just below the left eye was a small ragged wound, the size of a bullet, from which blood was freely oozing. There was also considerable hemorrhage from the left nostril. This was controlled by packing the nose with gauze, but even then it continued to ooze for two or three hours afterward. The temperature was 99, pulse 85, respiration 20. The left pupil was widely dilated, and did not react to either light or accommodation. The wound was thoroughly cleansed, and with a probe, the course of the wound was determined to be upward and inward to the orbital bone. No further attempt was made to locate the bullet. For drainage a small piece of folded rubber tissue was inserted into the wound and a sterile dressing applied. Three thousand units of tetanus antitoxin as a prophylactic

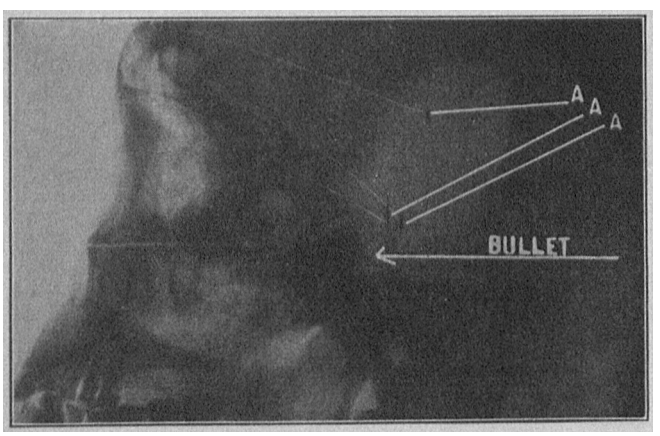

Fig. 1.—Location of bullet, and fragments along its course. *A, A, A,* silver wireclips placed over branches of middle meningeal artery in the dura at the time of operation.

dose were given intramuscularly, after which the patient was admitted to the ward on the service of Dr. William Sharpe.

The following morning, January 17, we found the patient with a complete right-sided hemiplegia. There were no signs of aphasia; there were a Babinski reflex of the right foot and beginning signs of medullary compression. The temperature was 100, pulse 60, respiration 16.

The cerebrospinal fluid by lumbar puncture was found by measurement under pressure and blood tinged.

Ophthalmoscopic examination revealed slight obscuration of the optic disk of the right eye, more marked on the nasal half.

These signs were present: 1. Hemiplegia of right side. 2. Beginning signs of medullary compression, as evidenced by lowered pulse rate, rise in temperature and diminished respiration. 3. The cerebrospinal fluid under pressure, shown by lumbar puncture and ophthalmoscopic findings.

The combined symptoms and signs of hemorrhage on the brain, together with other clinical signs, were also positive.

Fig. 2.—Patient, Oct. 10, 1916, aged 75.

Operation.—I performed a left cranial decompression. A vertical incision was made in the skin from a point just above the zygoma, on the left side about one-half inch anterior to the external auditory meatus upward about 3 or 4 inches to the middle of the parietal crest. The temporal fascia and muscle were incised longitudinally and retracted, care being taken not to tear away the attachment of the muscle to the parietal bone and thereby weaken its closure. With a Doygen perforator and burr a small opening was made in the lower and thinnest portion of the squamous portion of the temporal bone. With rongeurs the bone was cut away as far back as the retracted muscle would permit, in an oval shape to the diameter of 2 or 3 inches. The dura appeared tense and distinctly bluish underneath. When it was incised, quite a quantity of free dark blood escaped, but no clots were found. After the flow of blood ceased there was no evidence to be seen of any injury to the cortex. No attempt was made to search for the bullet (the location of which is shown in Figure 1). The dura was opened in a stellate manner and left so. A folded rubber tissue drain was placed in the lower angle of the wound subdurally into the middle fossa, then muscle, fascia and skin were securely sutured. Sterile dressing and roller gauze bandage were applied to the head and the patient returned to bed in good condition. The temperature was 99.6, the pulse 78, and the respiration 22.

Postoperative Course.—The wound healed by primary union. There was temporary incontinence of urine and feces. A discharge from the left eye ceased February 1. The left eye was totally blinded. There was no impairment of vision of the right eye. March 19, the patient was discharged with complete use of the right arm and hand; he still walked with the aid of a cane, but did not drag the foot. He has now passed his seventy-fifth birthday (Fig. 2), walks without a cane, is as mentally bright as before his accident, and continues to carry on his business—a small grocery store. He does not drag his feet, and has a firm grip to his right hand. The present weight is 118 pounds.

SUMMARY

The patient has always lived a temperate life, but his complete recovery, I believe, can be summarized as follows:

1. Prompt surgical relief of intracranial pressure before the onset of medullary edema with signs of compression or shock.
2. Release of subdural hemorrhage before any injury to the cortex from irritation by the formation of blood clots.
3. Selection of the subtemporal route with vertical incision for the decompression operation, thereby giving best opportunity for drainage and also perfect closure over the removed bone area.

175 West Seventy-Second Street.

Downloaded From: http://jama.jamanetwork.com/ by a Karolinska Institutet University Library User on 06/02/2015