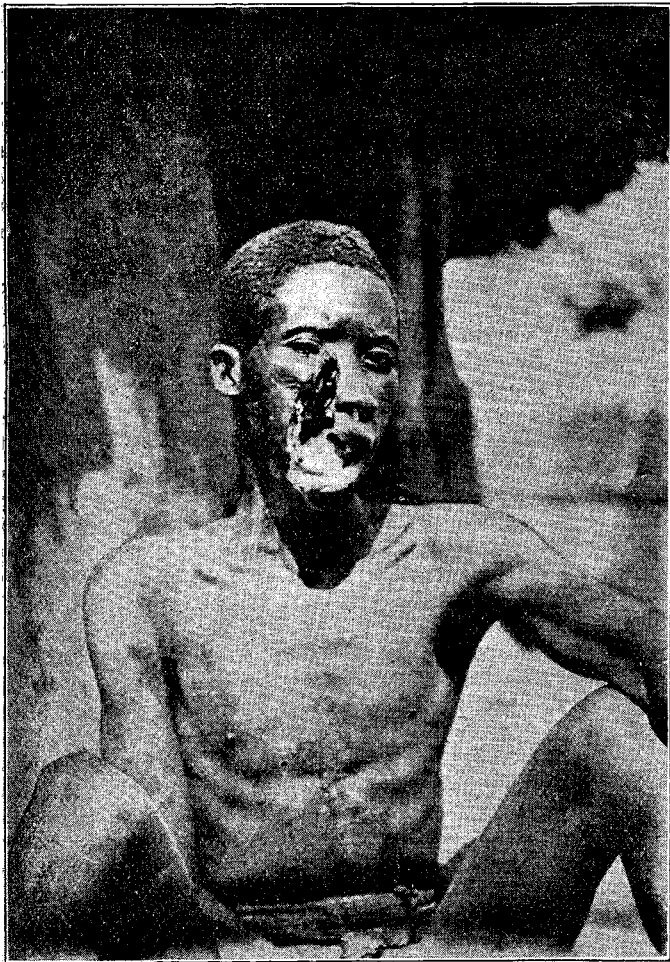


me when I remonstrated with him for telling me a boy was dead and asking for permission to bury him when as a matter of fact the native was not dead and did not die for some hours.

The history of the accident was as follows. A native police boy accused this boy of having taken his wife away. The native denied it and the police boy left the hut, leaving his rifle (a Martini) inside the hut. The native promptly picked it up, put it to his chin, and pulled the trigger with his right toe. A woman inside the hut seeing what he was about to do placed her hand over the barrel, the bullet passing between two of her fingers and inflicting no other damage than slight abrasion of the skin. The boy's injuries were terrible. The bullet fractured the lower jaw, almost severed the tongue, shattered the right half of the upper jaw, and came out between the inner angle of the orbit and the nose. The eye escaped entirely. The portion of the nose left consisted of skin and the deeper soft structures and, owing to the jaw on the left side also being fractured, was freely moveable. The native was seen inside a dark native hut by the light of a cheap candle. The hut was full of smoke and the atmosphere was extremely painful to one's eyes. In addition, a good view was obscured by old blood-clots and extremely foul pus, so that the precise nature of the injuries was extremely difficult to ascertain. The outer wall of the nasal fossa on the right side, the floor and septum seemed entirely destroyed and the superior and middle turbinated bones were exposed and bare. The boy's condition was extremely bad. He had a weak thready pulse, very rapid. He had rapid shallow breathing and



Showing appearance of wound.

painful cough, and his temperature was 103° F. His tongue was dry and covered with thick brown fur. He appeared to be moribund and if he lasted out the next few hours seemed in great danger of septic pneumonia or septic mischief extending inside the cranium. I gave him one chance in a 1000 and advised against his being carried to the nearest hospital, 15 miles away, as I thought that the journey would destroy his only chance. His brothers were feeding him on Kaffir beer only, administered by means of a gourd roughly shaped like an ordinary spouted feeding-cup. The same night I sent him out some boric lotion, instructing his brothers to cleanse the wound frequently with the lotion

and to apply hot fomentations. A week later I was told that the boy was better and a fortnight later, 16 days after the injuries, he walked 15 miles into the hospital.

The wound in the tongue had healed and the lower jaw had united. The cavity in the cheek had closed up considerably. The wound now seemed to be covered with healthy red granulations but the interior presented masses of dry brown-looking dead bone which from time to time came away. The native had lived for 16 days almost entirely on Kaffir beer.

The photograph reproduced was kindly taken for me by Private Timmins of the British South African police, hospital orderly. It shows the right nasal bone attached to the soft structure at the upper and outer corner of the wound and several portions of dead bone in the interior of the cavity. The right eye is partially closed by a lacrymal cyst.

Lomagundi, Southern Rhodesia.

#### A CASE OF HERMAPHRODITISM.

BY LIONEL H. MOISER, M.B. LOND., L.R.C.P. LOND.,  
M.R.C.S. ENG.,

LATE OBSTETRIC HOUSE PHYSICIAN AT GUY'S HOSPITAL.

THE patient was 19 years of age and rather masculine in appearance. Her voice was lower in tone than that of most women and she had no hair on her face. The hair on the pubes was normal in amount but it did not extend upwards to the umbilicus. The mons veneris was not well developed. The breasts were small and ill-developed, much the same in appearance as ordinary male breasts, and the nipples were small. The labia majora were normal in appearance but the labia minora were very small. The clitoris was very much hypertrophied, being one and a half inches in length and almost half an inch in diameter; the glans and prepuce were well developed, as also was the frænum. There was no meatus at the distal extremity of the clitoris. The meatus urinarius was in the normal position for the female. The vagina was two inches in length and small in circumference, the index finger being inserted with difficulty; the upper end of the vagina was slightly narrowed and blind. The hymen was absent. On examination under an anæsthetic no uterus or ovaries could be felt, neither was there any Fallopian tube. No testicles were felt.

Previously to Christmas, 1903, the patient never menstruated at all, but each month since that time she had had epistaxis, the onset being at regular intervals and each attack lasting about five days. Concurrently with these attacks she had an aching pain in the left ovarian region. Shortly after admission to the Royal Hants County Hospital on June 18th, 1904, she had a severe attack of pain in the left ovarian region which lasted eight or nine days; there was also slight epistaxis on one or two days. It was thought that she must have an ovary, either in a cystic condition or degenerated in some other way.

A laparotomy was performed to see if anything could be done to relieve the pain; no ovaries, uterus, Fallopian tube, or testicles were found. The vermiform appendix was about three inches in length and contained seven hard faecal concretions. This was removed. Since that time she has not had any recurrence of pain. Her temperature was normal throughout.

For permission to publish these notes I am indebted to Dr. H. E. Wingfield, physician to the Royal Hants County Hospital.

Winchester.

#### CHLORATE OF POTASSIUM IN HABITUAL ABORTION.

BY GEORGE S. S. HIRST, M.B., C.M. EDIN.

THE following notes may be of interest to the readers of THE LANCET.

In May last I was called to see a pregnant woman who 11 times previously had aborted during and after the third month of pregnancy. She and her husband were most anxious to have a living child and with this object she had consulted medical men during each pregnancy after the third—that is to say, she had been under medical treatment during the last eight pregnancies. Of the 11 abortions three had taken place during the third month, two during